

## Pedunculated lipoma of palate - A case study

Ashwini Dhananjay Mane Patil<sup>1</sup>, Sushant Narayan Mohite<sup>2</sup>, Prashant Shivaji Mane<sup>3\*</sup>

<sup>1</sup>Consultant, <sup>2,3</sup>Assistant Consultant, <sup>1-3</sup>Dept of Pathology, <sup>1-3</sup>Kolhapur Cancer Center Kolhapur Maharashtra, India

**\*Corresponding Author: Prashant Shivaji Mane**

Email: prashantmane0791@gmail.com

### Abstract

**Introduction:** Lipomas are a benign soft tissue neoplasm composed of mature adipocytes. They are most common soft tissue neoplasm in adults. These are usually subcutaneous tumors seen mostly on the trunk, back, shoulder and upper extremity. They are rarely seen in the oral cavity and account for less than 4% of all benign oral tumors. The patients usually present with an asymptomatic oral swelling. Histopathology shows many variants. Complete excision is curative with extremely rare recurrence. We report a case of a 40-year-old male with complaint of painless swelling in the oral cavity. The swelling was gradually increasing. On oral examination a pedunculated swelling was noted on the soft palate. The swelling was excised and was reported as a simple lipoma on histopathology. In conclusion, oral lipomas should be considered in differential diagnosis for the oral cavity swellings. A close follow-up is needed for deep intramuscular lipomas. We present this case for its rare presentation.

**Keywords:** Lipoma, Benign, Oral cavity, Soft palate.

### Introduction

Lipomas are most common benign soft tissue tumors in adults. Clinically they can be classified as superficial and deep lipoma. Superficial lipomas are seen in subcutaneous tissue of the trunk, back, shoulder and upper extremity, while deep lipomas are seen within the deep soft tissue or within skeletal muscle where they are called as intramuscular lipoma. The oral cavity is a very rare site for lipoma where its overall incidence is reported between 1% and 4% of all benign oral lesions.<sup>1,2</sup> Aetiology and pathogenesis of lipoma is not clear.<sup>2,3</sup> The most common site for oral lipomas are buccal mucosa.<sup>3-5</sup> Oral lipomas are usually asymptomatic but larger lesions may cause pain, difficulty in swallowing and speech. They may present as a pedunculated or sessile lesion. They are yellowish with consistency varying from soft to firm. On microscopy, it shows many variants such as simple lipoma, fibrolipoma, spindle cell lipoma, atypical lipoma and others. Surgical excision is the treatment of choice and recurrence is extremely rare.<sup>1-5</sup>

### Case Report

A 40-year-old male presented with oral cavity swelling and discomfort while swallowing. He also complained of gradually increase in size of the swelling. On oral examination, a 6 cm pedunculated, non-tender swelling with the smooth surface was noted on his soft palate. On palpation, the growth was slippery and soft in consistency. There were no signs of pain, discharge or inflammation. Based on the initial findings, the mass was considered to be a benign soft tissue lesion. The growth was surgically excised and the gross specimen consisted of a polypoidal mass measuring 6×4.5×3 cm with the smooth surface and soft consistency (Fig. 1). The cut surface revealed a well circumscribed, yellow colored fatty lesion. There were no areas of hemorrhage, necrosis or variegated appearance. Microscopic examination showed a circumscribed mass composed of mature adipocytes with scant fibrovascular

stroma (Fig. 2). It was confirmed to be a simple lipoma on histopathology.

### Discussion

The first case of oral lipoma was reported in 1878 by Roux, who referred it as “yellow epulis”.<sup>1,2</sup> Lipomas are the most common benign soft tissue tumor, but are rare in oral cavity accounting for less than 4% of all benign oral tumors.<sup>1,2,6</sup> Aetiology and pathogenesis of lipoma is not clear, but few possible theories suggesting its origin are heredity, fatty degeneration, hormonal abnormalities, injuries, infection, infarction, muscle cell metaplasia, residual embryonic fat cells, and chronic irritation.<sup>2,3</sup>

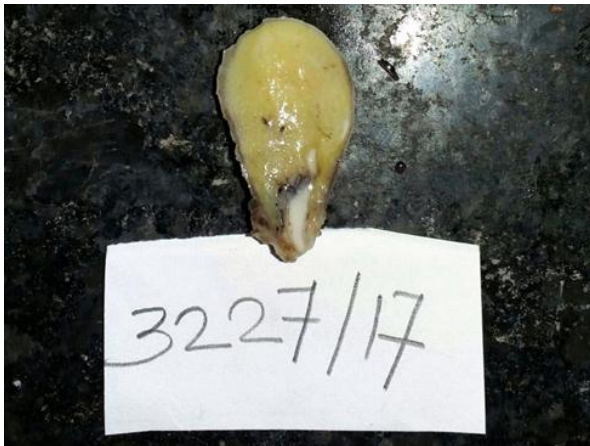
Lipomas are usually seen in adults between 50-60 years and are rare in children.<sup>3,4,7</sup> Morais HHA et al. reported a case of congenital lipoma of lip in a six-month child.<sup>8</sup> Oral lipomas are usually seen equally in both genders. Naruse T et al. found it to be slightly more common in females.<sup>3</sup> The patients usually present with an asymptomatic oral swelling. Larger lesions may sometimes produce pain, difficulty in swallowing, speech, dysarthria and dysmotility.<sup>3</sup> The swelling may be sessile or pedunculated. It may involve the buccal mucosa, tongue, lip, palate, gingiva, floor of the mouth or retromolar area. Buccal mucosa is the most common site for oral lipoma as reported by different studies.<sup>3-5</sup> Morais ALG et al. reported a case of intraosseous lipoma in the periapical region of third molar.<sup>9</sup> In the present case, the patient was 40 year male with a pedunculated swelling on soft palate.

The tumor size may vary, but the mean tumor size is reported as 2-3 cm.<sup>3,4,7</sup> Most oral lipomas show typical yellow color or surrounding mucosa color, smooth surface and consistency varying from soft to firm depending on fibrous tissue component. The swelling in our case was large measuring 6 × 4.5 × 3 cm and thus caused difficulty in swallowing. Histopathology is the gold standard for diagnosis. On microscopy, most oral lipomas are well-circumscribed and composed of mature adipocytes without

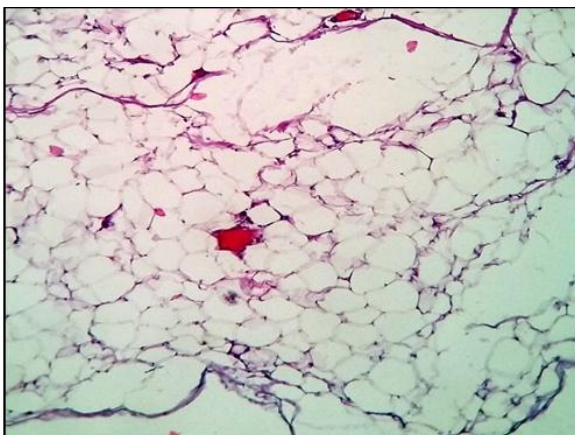
atypia and scant fibrovascular stroma. Individual cells show clear cytoplasm and eccentrically placed nucleus. On histopathology, lipoma can be classified as: simple lipoma, fibrolipoma, angioliipoma, chondrolipoma, angiomyoliipoma, intramuscular lipoma, pleomorphic lipoma, sialoliipoma, spindle cell lipoma, myxoid lipoma and atypical lipoma.<sup>1,3</sup> Simple lipoma is the most common subtype followed by fibrolipoma.<sup>3-5</sup> In our case it was simple lipoma.

Most of the published studies related to oral lipomas are single case reports. The largest study included 58 cases of oral lipoma published by Manor E et al. There was no gender predilection and most common site was buccal mucosa.<sup>4</sup> Fregnani ER et al. found similar findings in their study of 46 cases. Simple lipoma was the most common histological type in both studies.<sup>5</sup>

The treatment of choice for oral lipomas, including all the histologic variants, is complete surgical excision.<sup>3,5,8,9</sup> The prognosis is good with extremely rare recurrence. However, recurrence can be seen in deep lipomas. Wastner BF et al. reported one case of intramuscular lipoma of tongue which recurred after 10 years.<sup>10</sup> This can be attributed to incomplete excision. In our case, it was completely excised.



**Fig.1:** Intraoral pedunculated mass in the soft palate



**Fig. 2:** H&E section showing sheets of mature adipocytes; 40x magnification

## Conclusion

Intraoral lipomas are rare soft tissue tumors. They are seen equally in both genders in 5<sup>th</sup>-6<sup>th</sup> decade and commonly seen in buccal mucosa. Intraoral lipoma should be considered in differential diagnosis for oral cavity mass. Management remains the same for all histological subtypes and if complete excision is done, recurrence is extremely rare. Follow-up is necessary for deep intramuscular lipomas, where recurrence can be seen, if incompletely excised.

**Conflict of Interest:** None.

## References

1. Tettamanti L, Azzi L, Croveri F, Cimetti L, Farronato D, Bombeccari G et al. Oral lipoma: Many features of a rare oral benign neoplasm. *Head Neck Oncol* 2014;6(3):21.
2. Jeyaraj P, Sehgal S. Lipomas of the oral cavity: Importance of meticulous clinical evaluation, imaging and histopathological examination for precise treatment planning. *Dent Oral Craniofac Res* 2017;3(6).
3. Naruse T, Yanamoto S, Yamada S, Rokutanda S, Kawakita A, Takahashi H et al. Lipomas of the oral cavity: clinicopathological and immunohistochemical study of 24 cases and review of the literature. *Indian J Otolaryngol Head Neck Surg* 2015;67:67-73.
4. Manor E, Vardy NS, Joshua BZ, Bodner L. Oral lipoma: analysis of 58 new cases and review of the literature. *Ann Diagn Pathol* 2011;15(4):257-61.
5. Fregnani ER, Pires FR, Falzoni R, Lopes MA, Vargas PA. Lipomas of the oral cavity: clinical findings, histological classification and proliferative activity of 46 cases. *Oral Maxillofac Surg* 2003;3(1):49-53.
6. Filho GAN, Caputo BV, Santos CC, Souza RS, Giovani EM, Scabar LP et al. Diagnosis and treatment of intraoral lipoma: a case report. *J Health Sci Inst* 2010;28(2):129-31.
7. Bandéca MC, de Pádua JM, Nadalin MR, Ozório JE, Silva-Sousa YT and da Cruz Perez DE. Oral Soft Tissue Lipomas: A Case Series. *J Can Dent Assoc* 2007;73:431-4.
8. Morais HHA, Vajgel A, Rocha NS, Carvalho RWF, Caubi AF, Vasconcellos RJH et al. Congenital lipoma of the lip: a case report. *J Oral Sci* 2009;51(3):489-91.
9. Morais ALG, Mendonça EF, Alencar AHG, Estrela C. Intraosseous Lipoma in the Periapical Region of a Maxillary Third Molar. *J Endod* 2011;37(4):554-7.
10. Wastner BF, veronese M, Schussel JL, Silva WPP, Jung JE, Sassi LM et al. 10 years recurrence of an oral intramuscular lipoma: case report. *Arch Health Invest* 2017;6(9):443-5.

**How to cite this article:** Patil ADM, Mohite SN, Mane PS, Pedunculated lipoma of palate - a case study. *J Diagn Pathol Oncol* 2019;4(2):151-152.