

Primary pulmonary pleomorphic adenoma with cryptogenic organising pneumonia – A rare entity

Lithu Lal^{1*}, Thoppil Reba Philipose^{2,3}, Vinitha Samartha³

¹Consultant pathologist, ²Professor, ³Assistant Professor, Dept. of Pathology, ¹Sun Medical and Research Centre, Thrissur, Kerala, ^{2,3}A.J Institute of Medical Sciences, Mangalore, Karnataka, India.

Corresponding Author: Lithu Lal

Email: lithuz@gmail.com

Abstract

Pleomorphic adenoma, a common salivary gland tumor of the head and neck is a rare occurrence in the lung. We report a case of Primary pulmonary pleomorphic adenoma and its immunohistochemical features. The associated features of Cryptogenic organising pneumonia and post obstructive bronchiectasis are additional features which make the case more interesting. Awareness of this rare entity can prevent clinical misdiagnosis.

Keywords: Pleomorphic adenoma, Pulmonary, Bronchus.

Introduction

Pleomorphic adenoma (PA), a common salivary gland tumor of the head and neck is a rare occurrence in the lung.¹ With the 35 cases reported,² we report a rare case of Primary pulmonary pleomorphic adenoma (PPPA) associated with Cryptogenic organising pneumonia. PA is a tumor with both epithelial and connective tissue differentiation consisting of glands intermingled with myoepithelial cells in a myxoid and chondroid stroma.³ They are slow growing but with a potential to recur or metastasize.²

Case Report

A 37 year old man was referred to our hospital with a 2 month history of breathlessness, cough and right sided pleural effusion. He was found to have an obstructive lesion in the right intermediate bronchus on chest x-ray and bronchoscopy (Fig. 1a). There was no submandibular or parotid gland enlargement. The laboratory studies, including the peripheral blood smear, biochemical examination, and abdominal ultrasound showed no abnormalities. A right lower lobectomy (middle and lower) was done with a clinical diagnosis of Carcinoid – right bronchus.

Macroscopic examination showed a 2.8cm sized well circumscribed bluish white glistening homogenous unencapsulated mass in the right middle lobe bronchus (Fig. 1b).

Microscopy showed a well circumscribed biphasic tumor made up of epithelial and mesenchymal components. Epithelial component was seen in the form of ductal lumina lined by cuboidal epithelium, surrounded by myoepithelial cells in sheets and nests (Fig. 2a) merging with large chondroid and myxoid areas (Fig. 2b).

Surrounding lung parenchyma showed distal air spaces filled with fibroblastic plugs (Masson bodies) (Fig. 2c), – a feature of Cryptogenic organising pneumonia, confirmed by Masson trichrome staining.

Thickened and dilated bronchioles with intraluminal inflammatory exudate – feature of post obstructive bronchiectasis was also seen (Fig. 2d).

Lower lobe showed obstructive emphysema with dilated alveoli showing thinning and destruction of alveolar septae. There was positivity of the epithelial ductal elements for the antibodies to cytokeratin and vimentin (Fig. 3a). The myoepithelial component and the mesenchymal component of the tumor showed positivity for vimentin (Fig. 3b).

On followup, recovery was uneventful and patient is alive and well after 8 months.

Discussion

PPPA usually originate from the epithelium of the submucosal bronchial gland. They, therefore present as endoluminal lesions and rarely occur in peripheral or subpleural locations.⁴ There is no gender or age predominance: the ages ranging between 8 and 74 years.⁵

PPPA are biphasic like their salivary gland counterpart, but do not feature either a prominent glandular component or chondroid stroma like the salivary gland counterpart. Rather, tumors exhibit features of the so called “cellular mixed tumor” manifesting sheets, trabeculae or islands of epithelial and/or myoepithelial cells and a myxoid matrix. The present case featured predominance of chondroid component an unusual finding in PPPA. Mitotic activity, pleomorphism and necrosis are unusual.³ PPPA differ from pulmonary metastases of primary salivary gland tumors because they usually lack ducts or have very small branching ductules.⁶ Positive cytokeratin and vimentin immunochemical staining of the pleomorphic adenoma epithelial elements supports the diagnosis as primary tumors. In contrast, cytokeratin staining is more prominent in the salivary gland counterpart.⁶ Differential diagnosis includes chondroid hamartoma, pulmonary blastoma and carcinosarcoma. Chondroid hamartomas usually show mature cartilage that predominate the lesion while the latter tumors feature obvious malignant stroma and epithelium.⁶

Approximately one third of cases are found incidentally.⁷ The majority of patients do present with symptoms like cough, sputum production, dyspnea wheeze and stridor.⁸ In the present case due to the presence of intraluminal obstructive lesion of the bronchus, the

surrounding lung showed cryptogenic organising pneumonia with post obstructive bronchiectasis and the lower lobe showed obstructive emphysema.

In conclusion PPPA is an extremely rare tumor and metastasis from the salivary gland should be ruled out by thorough clinical history and examination. This case of

endoluminal pulmonary pleomorphic adenoma is interesting because of coexisting cryptogenic organising pneumonia and post obstructive bronchiectasis. Immunohistochemical staining supports the diagnosis of primary lung neoplasm. The treatment for this tumor is still surgical excision.⁶

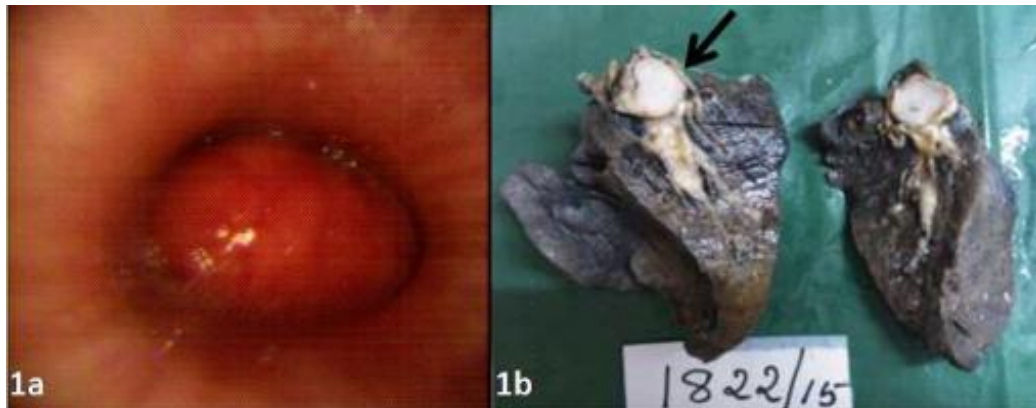


Fig. 1: (a) Flexible bronchoscopy intraluminal mass seen at the right intermediate bronchus. (b) Cut surface shows a bluish white glistening homogenous mass in the right middle lobe bronchus.

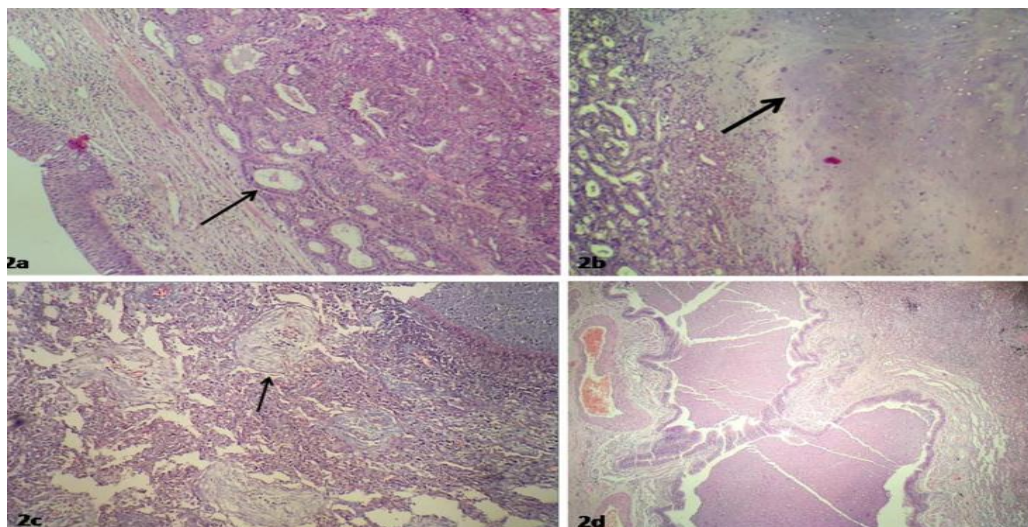


Fig. 2: (a) Epithelial component in ducts and surrounded by myoepithelial cells, (H&E x40). (b) Mesenchymal component with predominantly chondroid areas, (H&E x40). (c) Masson's bodies, (H&E x40). (d) Bronchiectasis – dilated bronchioles showing intraluminal inflammatory exudates, (H&E x40).

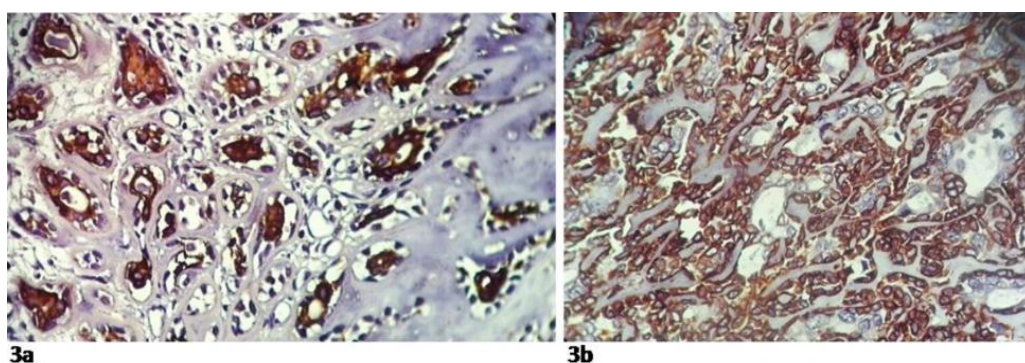


Fig. 3: (a) Cytokeratin positivity in the epithelial component. (b) Positive vimentin stain seen in the mesenchymal component.

References

1. Fitchett J, Luckraz H, Gibbs A, O'Keefe P. A rare case of primary pleomorphic adenoma in main bronchus. *Ann thoracic sur* 2008;30;86(3):1025-1026.
2. Huang YY, You DL, Tsou MH, Liu CC, Lee PI. Primary pulmonary pleomorphic adenoma with high uptake of FDG. *Eur J Radiol Extra* 2007;30;62(3):73-76.
3. Travis W.D., Brambilla E., Muller-Hermelink H.K., Harris C.C. (Eds.): World Health Organization Classification of Tumours. Pathology and Genetics of Tumours of the Lung, Pleura, Thymus and Heart. IARC Press: Lyon 2004;86.
4. Carretta A, Libretti L, Taccagni G, Zannini P. Salivary gland-type mixed tumor (pleomorphic adenoma) of the lung. *Interac cardiovasc thorac sur* 2004;1;3(4):663-665.
5. Goto T, Maeshima A, Akanabe K, Hamaguchi R, Wakaki M, Oyamada Y, Kato R. Bronchial pleomorphic adenoma coexisting with lung cancer. *Ann Thorac Cardiovasc Sur* 2011;17(2):174-177.
6. Ang KL, Dhannapuneni VR, Morgan WE, Soomro IN. Primary pulmonary pleomorphic adenoma: an immunohistochemical study and review of the literature. *Arch pathol lab med* 2003;127(5):621-622.
7. Sweeney EC, McDermott M. Pleomorphic adenoma of the bronchus. *J clin pathol* 1996;1;49(1):87-89.
8. Moran CA, Suster S, Askin FB, Koss MN. Benign and malignant salivary gland-type mixed tumors of the lung. Clinicopathologic and immunohistochemical study of eight cases. *Cancer* 1994;15;73(10):2481-2490.

How to cite this article: Lal L, Philipose TR, Samartha V, Primary pulmonary pleomorphic adenoma with cryptogenic organising pneumonia – A rare entity, *J Diagn Pathol Oncol* 2019;4(1):78-80