

Umbilical pilonidal sinus- an unusual presentation

Kafil Akhtar^{1,*}, Mohd Talha², Binjul Juneja³

¹Professor, ^{2,3}Resident, Dept. of Pathology, Jawaharlal Nehru Medical College, Aligarh, Uttar Pradesh

***Corresponding Author:**

Email: drkafilakhtar@gmail.com

Abstract

Umbilical Pilonidal Sinus (UPS) is a very rare form of umbilical disease. The presenting feature is usually pain and umbilical discharge. It affects active adolescent males with hairy abdomen and a deep naval. Treatment depends on the type of presentation with no consensus guidelines for the management of this disease. Most of the cases are managed conservatively with extraction of the hair and maintenance of personal hygiene. Surgery is indicated on failure of conservative management. Although umbilectomy is usually performed; complete sinus excision with reconstruction is done for cosmetic reasons. The commonest cause of failure of conservative management is incomplete hair extraction from the sinus tract. We present herewith a case of 27-year-old male, with umbilical pain, swelling, purulent discharge and bleeding on and off for the last 4 years. After repeated failed conservative management patient underwent excision of the sinus tract. After 2 years of follow up, the patient has no residual disease and has no complaints. This case emphasises the need for proper clinical examination for early detection of disease.

Keywords: Sinus Excision, Umbilical Pilonidal Sinus, Umbilicus Reconstruction.

Introduction

Pilonidal sinus disease usually occurs in the sacrococcygeal region, though it is also observed in the periumbilical.⁽²⁾ Exact etiology of this disease is unknown, but possibility of umbilical pilonidal sinus (UPS) should be considered in all cases of recurrent omphalitis.^(3,4) Clinical and pathological presentation of the disease supports the hypothesis of a congenital etiopathogenesis.⁽⁵⁾

Pilonidal sinus is characterized by a granulomatous reaction to the penetrating hair follicles. The umbilical pilonidal sinus should be treated more aggressively than its sacrococcygeal counterpart, as it is associated with a rapid peritoneal extension of inflammation.⁽¹⁾ Treatment of umbilical pilonidal sinus is usually surgical.⁽⁶⁾ The importance of differential diagnosis of umbilical pilonidal sinus from other umbilical pathologies should also be emphasized and taken into consideration.⁽²⁾

Case Summary

A 27 years old male presented to the surgical outpatient department with complaints of frequent pain followed by umbilical discharge for the last 4 years. The discharge was purulent and mixed with blood. There was no history of any previous similar symptoms or any trauma to the anterior abdomen. On local examination, a sinus opening with tuft of protruding hair and granulation tissue around the sinus was evident. Based on the clinical examination and history, a provisional diagnosis of Umbilical Pilonidal Sinus (UPS) was made. The tuft of hair was removed and a course of antibiotic therapy with anti-inflammatory drugs was prescribed. The patient was finally discharged with the advice of maintaining local hygiene and not to wear tight clothing. On routine follow up after a year, the patient again presented with similar complaints of umbilical pain and discharge with bleeding for the last 3 days. Fistulography

in midline near the bladder revealed a cavity of 4x4 cm size and a fistulous tract from the cavity to the umbilicus, with release of an opaque material from the orifice of the fistula. Due to risk of deeper infection, the pilonidal sinus was excised and the specimen submitted for histopathological examination. Microscopically tissue section showed a sinus tract with hair follicles lodged deeper into the dermis with intense foreign body type of granulomatous reaction, comprising of neutrophils and lymphocytes (Fig. 1 & 2). After 2 years of follow up, there is no residual disease and patient is symptom free.

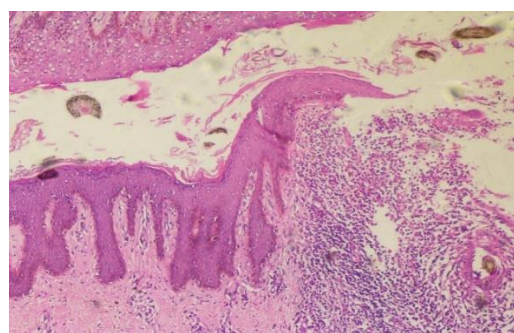


Fig. 1: Histopathological examination of the specimen showed a sinus tract with keratinous debris and dense neutrophilic and lymphocytic infiltrate. Hematoxylin and Eosin x 40X

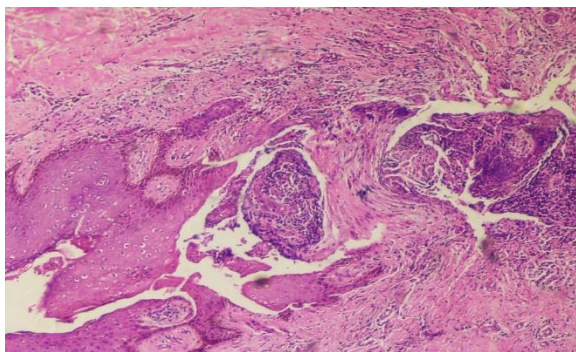


Fig. 2: Section shows hairs follicle lodged deeper into the dermis with intense foreign body type granulomatous reaction surrounded by dense neutrophilic and lymphocytic infiltrate. Hematoxylin and Eosin x 40X

Discussion

Pilonidal sinus is a common surgical disease. The term 'pilonidal' was first given in 1833 by Herbert Mayo. The Latin word, 'pilonidal', means nest of hair.⁽⁷⁾ The first case of an umbilical pilonidal sinus was reported by Patey and Williams in 1956. Since then, only a few cases have been reported in medical literature.⁽⁸⁾ The disease has a sacrococcygeal location but has also been reported at sites with accumulation of hair, like the axilla, between the breasts, the perineum, the penile shaft and between the fingers, particularly in the barbers. Penetration of the hair shafts into the skin is facilitated by a negative pressure which is created during body movements at the above-mentioned sites, leading to a sinus tract with foreign body reaction. Umbilical pilonidal sinus is very rare, accounting for only 0.6% of cases.⁽⁹⁾

The clinical features of umbilical pilonidal sinus results from an inflammatory reaction in the sinus. Pain, swelling and purulent discharge are the usual symptoms. The patients may present with an acute abscess. The predisposing factors are intense hairy anterior abdomen, young male, a deep navel and poor personal hygiene.^(6,10)

The differential diagnosis includes a host of umbilical region anomalies such as umbilical hernia (which can be ruled out as there is no pulsatile and non-reducible swelling), and Sister Mary Joseph nodule, which is a cutaneous umbilical nodule, due to metastatic deposits from primary malignancy in abdomen, (in our case there is no evidence of abdominal malignancy). UPS may also mimic pyogenic granuloma, which histopathologically shows a lobular capillary haemangioma, congenital anomalies (which are present since birth and with a positive family history), epidermoid cysts, which shows a cystic cavity filled with keratinous debris and endometriosis with foci of endometrial glands and stroma in a female presenting as a umbilical nodular mass.⁽¹⁰⁻¹²⁾

Though UPS can be diagnosed clinically by the detection of hair nests; preoperative intra-abdominal imaging may be required in doubtful cases.⁽¹²⁾

Conservative treatment in the form of hair extraction with improved umbilical hygiene are the first-line therapy to manage an umbilical pilonidal sinus.⁽¹³⁾

The main cause of failure with conservative treatment is the incomplete extraction of the hair from the sinus.^(13,14) A simple incision and drainage of the abscess may be curative at times.⁽¹⁰⁾ Cases resistant to conservative management are treated with surgical excision and reconstruction of the umbilicus.⁽¹⁵⁾ Some surgeons recommend umbilical excision and wound closure by secondary intention and scar formation to resemble a normal umbilicus.^(15,16) The technique to leave a skin fold at the mouth of the umbilicus after sinus excision and subsequent reconstruction seems to be cosmetically acceptable.^(15,16) Fazeli et al used a similar technique in their series of 45 cases and have recommended complete sinus excision and reconstruction surgery after umbilicus eversion, as a primary treatment of umbilical pilonidal sinus disease.⁽¹⁵⁾

Conclusions

A discharging umbilical sinus in a young active male, with dense hairy anterior abdominal skin should raise the suspicion of umbilical pilonidal sinus. The presenting symptom of the disease guides the management. The first line of treatment in symptomatic UPS is conservative with extraction of the sinus hair and maintenance of personal hygiene. Surgery is indicated in cases of failed conservative management. This case report emphasizes on considering pilonidal sinus in differentials of umbilical swellings for early detection and treatment.

References

1. Barrett TL and Schoelch SB. Umbilical Pilonidal Sinus. *Cutis* 1998;62:83-84.
2. Eryilmaz R, Sahin M, Okan H, Alimoglu O, Somay A. Umbilical Pilonidal Sinus disease: predisposing factors and treatment. *World J Surg* 2005;29:1158-1160.
3. Gupta S, Sikora S, Singh M, Sharma L. Pilonidal disease of the umbilicus - a report of two cases. *Jpn J Surg* 1990;20:590-592.
4. Colapinto ND. Umbilical Pilonidal Sinus. *Br J Surg* 1977;64:494-495.
5. Tocchi A, Liotta G, Agostini N, Maggiolini F. The umbilical pilonidal cyst: a case report. Comments on its etiopathogenesis and treatment. *G Chir* 1994;15:33-36.
6. McClenathan JH. Umbilical Pilonidal Sinus. *Can J Surg* 2000;43:225-226.
7. Thorlakson RH. Pilonidal Sinus of the umbilicus. *Br J Surg* 1966;53:76-78.
8. Patey D and Williams ES. Pilonidal sinus of the umbilicus. *World J Surg* 2014;271:281-282.
9. Goodall P. The etiology and treatment of the pilonidal sinus. *Diag Surg* 2016;12:117-120.
10. Abdulwahab BA and Harste K. Umbilical pilonidal sinus. *Ugeskr Laeger* 2010;172:2848-2849.
11. Akkapulu N and Tanrikulu Y. Umbilical Pilonidal Sinus: A Case Report. *J Med Cases* 2011;2:272-274.

12. Kareem T. Outcomes of conservative treatment of 134 cases of umbilical pilonidal sinus. *World J Surg* 2013;37:313-317.
13. Abdelnour A, Aftimos G, Elmasri H. Conservative surgical treatment of 27 cases of umbilical pilonidal sinus. *J Med Liban* 2015;42:123-125.
14. El-Bakry AA. Discharging umbilicus. *Saudi Med J* 2012;23:1099-1100.
15. Fazeli MS, Lebaschi AH, Adel MG, Kazemeini AR. Evaluation of the outcome of complete sinus excision with reconstruction of the umbilicus in patients with umbilical pilonidal sinus. *World J Surg* 2008;32:2305-2308.
16. Sroujeh AS and Dawoud A. Umbilical sepsis. *Br J Surg* 2016;76:687-688.