

Efficacy of endoscopic biopsies in establishing histologic diagnosis of upper gastrointestinal tract lesions - A one year prospective study

P Uma Rani¹, N Ramya², C Swathi^{3*}, Vijaya Kumar⁴, P Spandana⁵

¹Assistant Professor, ²Final Year Postgraduate, ³Assistant Professor, ⁴Professor, ⁵Second Year Postgraduate

***Corresponding Author:**

Email:saiswathi25@gmail.com

Abstract

Introduction: The definitive diagnosis of upper gastrointestinal disorders depends on histopathological confirmation & is the basis for planning treatment. Histopathological study is also used to monitor the extent of disease, response to therapy & for early detection of complications.

Aim: To determine the incidence and spectrum of Upper Gastrointestinal lesions.

Study design: A prospective descriptive study done in a period of one year from June 2015 to May 2016.

Setting: Department of Pathology, ASRAMS.

Materials and Methods: The study was carried out in our institute that includes 100 patients. All upper GIT endoscopic biopsies received during the 1 year period were included in the study. The tissues were formalin fixed, routinely processed and embedded in paraffin wax. Three to five serial sections were taken, stained with Hematoxylin & Eosin and examined.

Results: Stomach was the most frequent site of endoscopic biopsy(64%) followed by oesophagus(25%), duodenum(6%) and gastroesophageal junction(5%). Majority of patients(51%) presented with dysphagia and abdominal pain. Mean age of presentation was 50 years. Male to Female ratio is 3:1. Association with *Helicobacter pylori* was noted in few cases, which were identified on giemsa stain.

Conclusion: This study showed a good correlation between endoscopic and histological diagnosis. Further studies are needed to identify the underlying risk factors.

Keywords: Endoscopy, Histopathological study and upper gastrointestinal tract lesions.

Introduction

The definitive diagnosis of upper gastrointestinal disorders depends on histopathological confirmation & is the basis for planning treatment.⁽¹⁾ Upper gastrointestinal tumors include those arising from the esophagus, stomach, 1st & 2nd parts of duodenum. Malignancies of the oesophagus and stomach are detected late as the patients are either asymptomatic or present with mild non-specific symptoms in the early stages of disease. Thus early detection of these lesions is important. The technical advances that made fiberoptic instrument began in 1927 by Baird. Modern gastroscopy began in 1936 with the introduction of semi flexible endoscope by Wolf and Schinder. The modern era of gastrointestinal endoscopy began in 1957 when Basil developed first fiberoptic gastroscope. The chief value is an aid to the endoscopist in detecting the features of early cancer.⁽²⁾ Histopathological study is also used to monitor the extent of disease, response to therapy & for early detection of complications.

Materials and Method

The present study includes hundred patients. The endoscopic biopsies received to the department of pathology, at our institute during a period of 1 year, from June 2015 - May 2016 were included. The biopsies were received from our institute and the surrounding hospitals in the west Godavari district. The endoscopy was initially done by a surgeon at our institute and later on by a gastroenterologist. They provided us a detail clinical

findings during endoscopy along with complaints of patient. Even the endoscopic biopsies received from surrounding hospitals were provided with a detail endoscopic findings and clinical complaints. The tissues were received in 10% formalin filled container. It was entirely processed, and routinely embedded in paraffin wax. Multiple serial sections were taken, stained with Hematoxylin and Eosin. The sections were then examined. Special stains like giemsa, PAS, alcian blue & silver stains done whenever required. Giemsa was done in patients who were endoscopically diagnosed as chronic gastritis, duodenitis and whenever there is a suspicion of *Helicobacter pylori*. Periodic acid Schiff stain and alcian blue were done in cases of signet cell carcinoma, mucinous adenocarcinoma etc.

Statistics

All data were tabulated in a Windows Excel spreadsheet (Microsoft Excel 2011) and statistically analyzed. In esophageal carcinoma the sensitivity is 94.4% and specificity is 100%. In gastric carcinoma the specificity is 79% and sensitivity is 76%.

Results

Total 100 cases were examined in a period of 1 year and there was 94.44% positive correlation between endoscopy & histopathology in oesophageal biopsies, 76% in gastric malignancies. Majority of the patients either presented with dysphagia (25%) or abdominal or epigastric pain (37%). Remaining 38 % patients had non-specific symptoms such as nausea, vomiting, weight

loss, hematemesis, anaemia etc. Association with *Helicobacter pylori* was noted in few cases(1%), which were identified on giemsa stain. (Figure1 ; Figure 2; Figure 3; Table 1; Figure 4;Figure 5; Figure 6; Figure7; Figure 8)

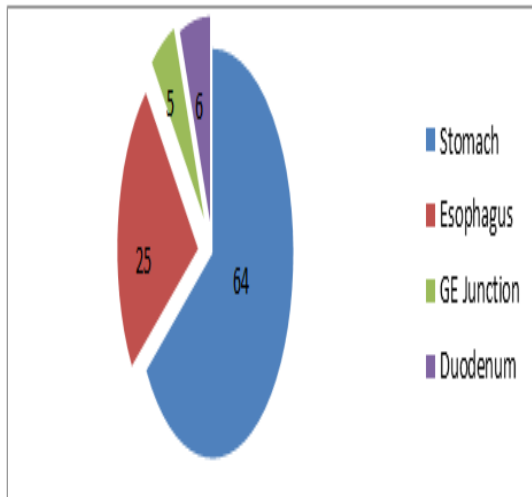


Fig. 1: Distribution of endoscopic biopsies

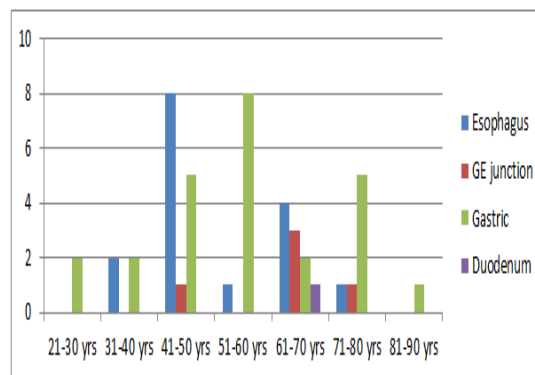


Fig. 2: Age distribution of malignant lesions

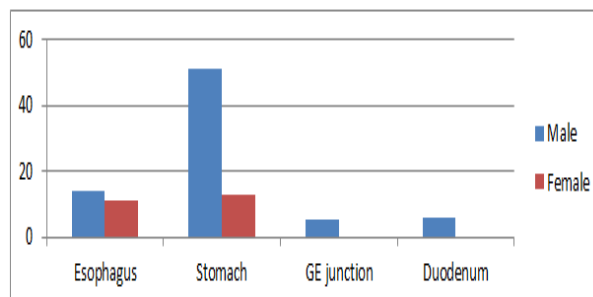


Fig. 3: Sex distribution of UGIT endoscopic biopsies

Table 1: Endoscopic presentation and histopathology findings of the total number of biopsies

Endoscopic presentation	Neoplastic lesions	Dysplasia	Non-neoplastic lesions	Unremarkable /Inconclusive	Total
Polypoidal	18	0	11	0	29
Ulcerative	28	2	8	2	40
Infiltrative	7	0	0	0	7
Atrophic	0	0	0	0	0
Irregular mucosa	0	0	22	2	24
Total	53	2	41	4	100

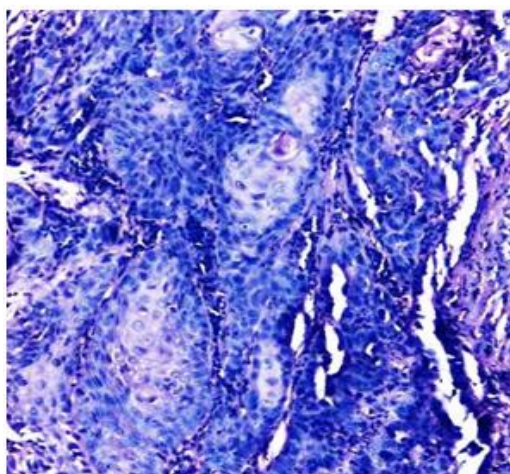


Fig. 4: Squamous cell carcinoma, sections shows nests of malignant squamous epithelial cells with pearl formation, Esophageal growth(H&E,10X)

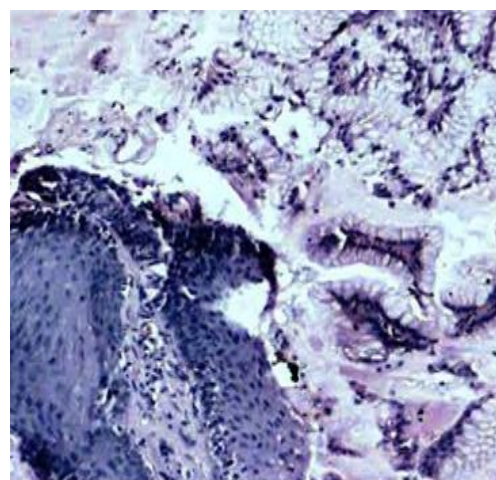


Fig. 5: Barrett mucosa, section shows metaplastic columnar epithelium with intervening goblet cells in lower third of the oesophageal region.(H&E,10X)

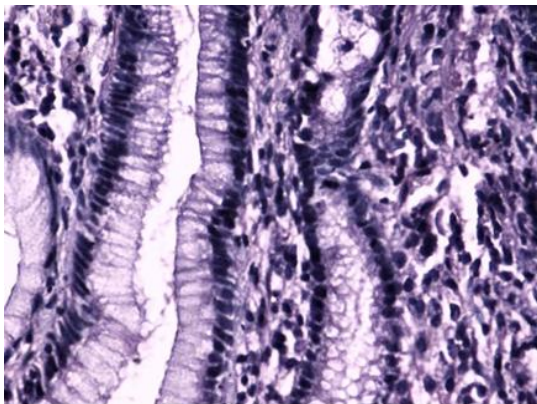


Fig. 6: Chronic gastritis, gastric mucosa (antrum) is diffusely infiltrated by chronic inflammatory cells (H & E,40x)

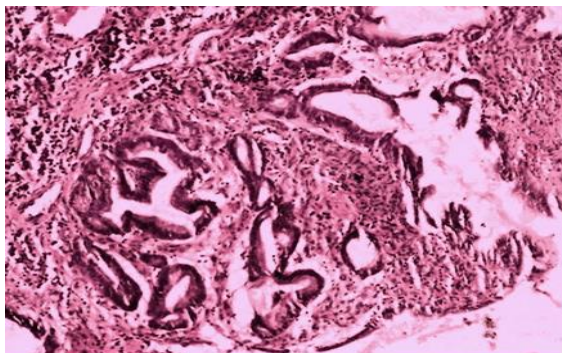


Fig. 7: Moderately differentiated adenocarcinoma, gastric biopsy showing irregular atypical glands lined by pleomorphic appearing tumor cells, surrounding stroma shows moderate inflammation (H&E, 10x)

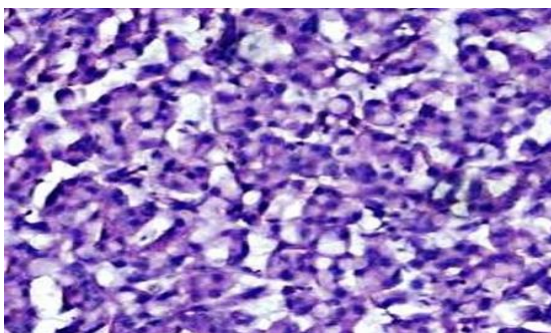


Fig. 8: Sheets of signet ring-like cells diffusely infiltrating the stroma (H&E,40X)

Discussion

The current standard of care for most patients with symptoms of upper GIT and having suspicious lesions consists of initial endoscopic examination followed by histopathology. The individual accuracy and sensitivity of these techniques in the diagnosis of any lesions is subjective to the operator’s ability to target site of pathology. This can be greatly improved by combining the two techniques.

In the present study, most common site for upper GI endoscopic biopsy is from the stomach, followed by esophagus & duodenum. Among 100 endoscopic biopsies, 76 were males & 24 were females. Male to female ratio is 3:1. Males are at more risk than females, correlating with the studies of JC Paymaster et al⁽³⁾ and other workers. Age of the patients varied from 20-85 years. Most of the biopsies were from 6th decade in our study, while Rashmi K et al⁽⁴⁾ found predominance in 5th decade. Mean age of esophageal carcinoma was 52.61years. In our study among 64 gastric biopsies, mean age of gastric carcinoma was 57.68 years, while Islam SMJ⁽⁵⁾ found 43.14 years. In our study, out of 6 duodenal biopsies, only case of duodenal adenocarcinoma was found at 65 years.

With respect to malignant lesions, endoscopic diagnosis was made in 17 out of 18 cases of esophageal carcinoma. Hence correlation between endoscopy & histopathology with respect to esophageal carcinoma was 94.44%.

Sensitivity = $\frac{\text{True positives}}{\text{True positives} + \text{False negatives}} \times 100 = 94.44\%$

True positives+false negatives

Specificity = $\frac{\text{True negatives}}{\text{True negatives} + \text{False positives}} \times 100 = 100\%$

False positives+True negatives

In carcinoma stomach, endoscopic correlation with histopathology was 19 out of 25 cases, that is around 76% and specificity is 79% which is less than that seen with esophageal carcinoma.

The reason for endoscopic biopsies in esophageal carcinoma having good sensitivity is because they usually present late in the clinical course & hence can be picked up by the endoscopy easily whereas gastric malignancies present mostly as ulcers or flat lesions. KaziJ1et al⁽⁸⁾ got 100% correlation in esophageal biopsies, 88.8% correlation in gastric biopsies. (Table 2)

Table 2: Comparison of our study with other similar studies

Esophagus		Our study(n=30)	Rashmi K et al	Qureshi NA et al ⁶	Jaynul Islam
Neoplastic lesions	SCC	60%	44%	1.35%	59.09%
	Adenocarcinoma	20%		70.2%	13.63%
Non-neoplastic lesions		13.33%	56%		27.28%
Gastric		Our study(n=64)	Rashmi K et al	Bhatty et al ⁷	Jaynul Islam
Malignant lesions		39.06%	27.94%	1.9%	45.2%

Gastritis	19%	37%	83.4%	20.55%
Duodenum	Our study(n=6)	Kazi J1 et al⁸	Jaynul Islam	
Hyperplastic polyp	50%	43.15%	73.33%	
Duodenal ulcer	33%	56.85%	13.67%	

Conclusion

The common site of upper GIT lesion is of gastric origin and the incidence of gastric tumors is high in west Godavari region. Histopathology is used to confirm endoscopic findings as well as to monitor the extent & course of disease, response to treatment and for early detection of complications.

Acknowledgments

- I sincerely thank the department of surgery and gastroenterology for their esteemed support in providing us the clinical data.
- I thank our entire department for their help and support in helping me to complete the study.

References

1. VM. Vashistha and P kumar. 50 years of immunization in India: Progress and future. Indian Paediatrics 2013, Vol 50: p.111 -118.
2. National Family Health Survey(NFHS-3),2005-06, India. Mumbai, International Institute of Population Sciences and Macro International, 2007. Available online:(http://nfhsindia.org/nfhs3_national_report.html) Accessed on 26 September 2014.
3. Paymaster JC, Sanghavi LD, Gangadharan P. Cancer of gastrointestinal tract in western India. Cancer 1968;21:279-87.
4. Rashmi K, Horakerappa MS, Karar A, Mangala G. A Study on Histopathological Spectrum of Upper Gastrointestinal Tract Endoscopic Biopsies. Int J Med Res Health Sci.2013;2(3):418-424. DOI: 10.5958/j.2319-5886.2.3.073.
5. Islam SMJ, Ali SM, Ahmed S, Afroz QD, Chowdhury R, Huda M. Histopathologic Pattern of Gastric Carcinoma in Bangladesh. JAFMC Bangladesh.2009;15(1):21-24.
6. Qureshi NA, Hallissey MT, Fielding JW. Outcome of Index Upper Gastrointestinal Endoscopy in Patients Presenting with Dysphagia in a Tertiary Care Hospital-A 10 Years Review. BMC Gastroenterology.2007;7:43 doi:10.1186/1471-230X-7-43.
7. Bhatti AS, Shaikh NA, Zahir N, Akhter SS, Vaswani AS, Manzoor H. Histopathologic Spectrum of Upper Gastrointestinal Endoscopies. Medical Channel.2009;15(4):11-14.
8. Kazi J I, Alam SM, Kazi AM, Anwar A, Shamsi Z. Correlation of Endoscopic and Histologic Diagnosis in Upper Gastrointestinal lesions. JPMA. 1990;40(12):281-283.