

## Xanthogranulomatous Pyelonephritis in association with Chronic kidney disease: A novel step in early detection of Renal Tuberculosis

Anandraj Vaithy. K

Assistant Professor, Dept. of Pathology, Mahatma Gandhi Medical College, Pondicherry

**\*Corresponding Author:**

Email: kanandr@gmail.com

### Abstract

**Introduction:** Xanthogranulomatous pyelonephritis is a chronic renal pathological condition with destructive granulomatous process. It is typically associated with nephrolithiasis followed by sequelae of nonfunctioning kidney. Tuberculosis being a major global infectious disease, the incidence of renal tuberculosis has been increasing in recent years in developing countries like India. Despite recent advances in diagnostic modalities, early and accurate diagnosis of renal tuberculosis has become a challenging task to the Pathologists especially with varied presentations having many differentials on histology. In the present study, we aimed to analyze the incidence of renal tuberculosis associated with Xanthogranulomatous pyelonephritis and correlation with clinical profile thereby aiding in prompt diagnosis & treatment.

**Materials and Method:** The present study involved all age groups. With few exclusion criteria, all the nephrectomy specimen sent to laboratory were subjected to standard histopathological procedure with staining in reference to standard operating procedure. All the histological features on microscopy were documented and correlated with preoperative clinical data and presentation.

**Results:** Total number of twenty nephrectomy specimen with varied preoperative clinical indications were analyzed. Among the cases with diagnosis of calculi without any clinical history and radiological evidence for renal tuberculosis, 18 cases showed renal calculi in association with xanthogranulomatous pyelonephritis. Extensive sampling from these 18 specimens, 10 cases revealed foci of renal tuberculosis associated with xanthogranulomatous pyelonephritis in the adjacent renal parenchyma

**Conclusion:** Renal tuberculosis is an uncommon renal pathology often under diagnosed preoperatively. Hence combination of a nonfunctioning contracted kidney, a central calculus, contracted renal pelvis with association of xanthogranulomatous pyelonephritis, suspicion of renal tuberculosis must always be included in the differential diagnosis by the Pathologist thereby aiding in the post-operative treatment.

**Keywords:** Chronic pyelonephritis, Renal tuberculosis, Xanthogranulomatous reaction

### Introduction

Chronic pyelonephritis is a renal infectious condition encompassing various entities of different underlying pathological causes. It is a destructive process of renal parenchyma tissue commonly associated with long term urinary tract obstruction. It had been observed by Craig et al., that approximately 19.2% of nephrectomy procedure being performed with the indication of chronic pyelonephritis[CPN].<sup>(1)</sup> Xanthogranulomatous pyelonephritis [XPN] is an uncommon entity of CPN first describe by Schlagenhauser in 1916 and is defined as a chronic destructive granulomatous inflammation of the renal parenchyma.<sup>(2)</sup>

This condition comprises of less than 1 % of the renal pathological incidence with female preponderance involving wide range of age groups from newborn to elderly adults.<sup>(2)</sup> Three microscopical classification of the condition includes diffuse, segmental and focal depending upon the involvement of renal parenchyma. XPN is a rare cause of CPN resulting in non-functioning kidney and poses a preoperative diagnostic dilemma mimicking other conditions often renal carcinoma warranting optimal surgical removal as treatment.<sup>(3)</sup>

The common symptom of XPN includes flank abdominal pain, lower urinary tract infection and hematuria. Superadded complication like psoas and pelvic-abscess, nephrocutaneous fistula are not uncommon.<sup>(3)</sup> However clinical diagnosis of XPN often goes with interpretation of common urinary tract infection with conservative antibiotic treatment leaving down the underlying pathology. Histologically XPN, presents with granulomatous inflammatory infiltrate composed of neutrophils, lymphocytes, plasma cells, xanthomatous histiocytes, multinucleated giant cells & foreign body reactions.<sup>(4)</sup>

Renal tuberculosis[RTB] being an extra pulmonary manifestation of Tuberculosis in Tropical countries, the incidence of RTB often remains obscure and unexplored due to its varying presentations.<sup>(5)</sup> Renal tuberculosis accounts for 5 to 15% of the renal pathology, the interpretation still remains a diagnostic challenge task to the Pathologists as well. Macroscopically RTB presents with cystic degeneration associated with presence of calculi giving various differential diagnosis to the pathologists grossly.<sup>(4,6)</sup>

With few exceptional cases, no clinical or radiological feature is diagnostic of RTB even in classical scenario. In a recent study, it had been observed that 22% of patients presented with renal mass

with necrosis and cystic change radiologically favoring renal neoplasm preoperatively showed RTB mostly associated with XPN on further histological section of the post-operative nephrectomy specimens.<sup>(7)</sup>

The exact etiology of XPN remains unknown, however many researchers postulated that, the then disease is associated with long term infection followed by obstruction. Additional predisposing factors like obesity, hepatitis, diabetes mellitus and cirrhosis were also reported.<sup>(8)</sup> Although none of the clinical, laboratory and radiological investigations are confirmatory, diseases like RTB presents with multiple clinical symptoms especially weight loss. Common laboratory investigations includes leukocytosis, anemia, elevated levels of ESR, alkaline phosphates, and blood sugar. Urine culture is of limited use.<sup>(8,9)</sup> CT and imaging though remains a mainstay for radiological diagnostic mode, it often has a self-limitation to categorize between other similar entities hence relying on histopathological interpretation.<sup>(9)</sup>

Renal TB being extra pulmonary manifestation, spreads by hematogenous mode more commonly from lungs, less than 5% of patients with urinary tract TB have active pulmonary tuberculosis.<sup>(10)</sup> Thus in many instances, preoperative diagnosis is dis-concordant with post-operative report due to vague clinical presentations. Hence the confirmatory diagnosis of RTB is based on histopathological study and surgery remains the treatment in almost all the cases.<sup>(7,10)</sup> In the present study, we aim to document the incidence of RTB, correlate with clinical data and to advocate the novel histological diagnostic features for interpretation of RTB thereby aiding in prompt patient care.

## Materials and Method

The present study included 20 cases of nephrectomy specimens operated for various clinical indications with radiological correlation and sent for histopathological examination. Nephrectomy done for the cases with proved renal malignancy, patients on dialysis preoperatively were excluded from the study. CKD was defined as per standard definition by renal disease outcomes quality initiative guidelines.<sup>(2)</sup> All the clinical data were documented in Performa. The nephrectomy specimens are subjected to standard grossing protocol including presence of calculi, cortico-medullary junction, hydro nephrosis, necrosis and abscess, adjacent renal parenchyma, cystic degenerative changes, and hemorrhage. The tissue was processed and stained according to standard operating procedure.<sup>(2)</sup> The microscopical features were documented including glomerular status with basement membrane, xanthomatous changes, necrosis, granuloma formation,

mucoid degenerative changes, pelvi-calyceal inflammatory changes. Correlation between histopathology with clinical profile and preoperative diagnosis were tabulated. XPN with calculi and XPN in adjunction with renal TB were made into two different groups and compared with clinical data of presentation. The results are tabulated and analyzed between the observed groups.

## Results and Observations

**Patient characteristics:** Among total number of 20 nephrectomy specimens analyzed, 18 cases satisfied the inclusion criteria. All the cases diagnosed to have calculi preoperatively, showed Xanthogranulomatous pyelonephritis changes on light microscope. None of the cases were diagnosed to have RTB preoperatively. Age and gender distribution is illustrated in Table 1.

**Gross features:** The specimens were measured which showed varying proportion. 8 cases showed features of 'contracted kidney' and 10 cases showed cystic degenerated kidney with classical bosselated appearance characterized by extensive fibrosis [Fig. 1]. On cut section, cortico-medullary junction was distorted in all the cases. Ten cases (n=18) showed classical yellow orange streaks grossly with cystic changes filled with grey white mucoid material [Fig. 2]. Pelvi-calyceal system was dilated in 8 of the cases. All the cases showed calculi of varying significant dimensions & staghorn type.

**Histopathological features:** All the H& E stained cases showed features of Xanthogranulomatous pyelonephritis with foamy macrophages [Xanthomatous Cells] with inflammatory cell infiltrate correlating with gross features. Coincidentally, sections from extensive sampling in 15 cases (n=18) revealed tuberculous foci showing amorphous granular caseating ill formed granuloma, Langhans giant cells in adjunction with Xanthogranulomatous microscopically as illustrated in Table 2; [Fig. 3] Sections from pelvic-calyceal system showed more granulomatous change and sections from renal parenchyma with cystic changes showed more caseous necrotic changes [Fig. 4].

**Clinical & Radiological Profile:** Based on the observations, clinical profile of the patients were interrogated which revealed history of diabetes mellitus, hypertension, weight loss, urinary tract infections, hematuria in varying proportions Table 3. Radiological findings showed varied features as described in Table 4, 5.

**Table 1: Age & gender distribution of cases**

Mean age (years)	No. of cases XPN with Renal TB(n=15)		p Value
	Male	Female	
45- 55 years [with renal calculi]	9	6	0.0496
40- 50 years [with recurrent UTI]	6	9	0.0496

**Table 2: Site distribution and histomorphological features**

Site/Foci distribution	Observed Histomorphological features	No. of Cases
Renal parenchyma & cortico-medullary junction	Cystic degenerative changes with granulomatous necrosis [diffuse pattern]	6
Pelvi-calyceal system	Mucoid degeneration with caseous necrosis [segmental pattern]	7
Pelvi-ureteric junction/hydronephrosis	granuloma with multinucleated giant cells [segmental & focal pattern]	2

**Table 3: Clinical profile and XPN Association**

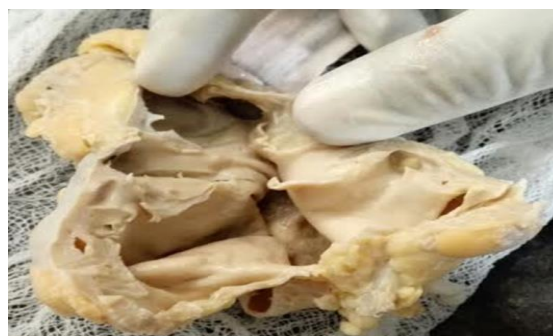Clinical profiles	XPN on histopathology (n= 18)	XPN in association of Renal TB on histology (n=15)	p value
Diabetes mellitus [ $> 5$ years duration] %	59.8	65%	0.0224
Weight loss (%)	41.9	59.6%	0.0211
Hematuria (%)	47.7	49.5%	0.0322
Proteinuria /edema (%) [nephrotic range]	55.2%	53.2%	0. 0453
Hypertension (%)	26.9%	28.9%	0.0753
Pulmonary TB	-	10.9%	0.0930

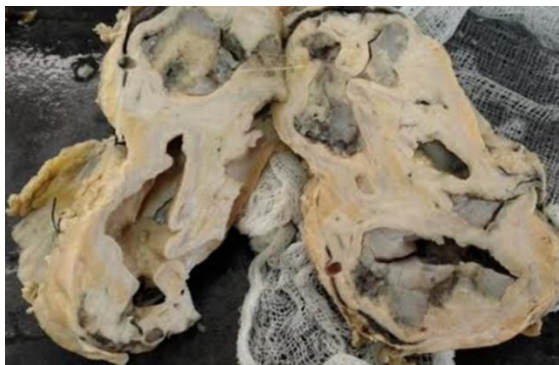**Table 4: Radio-histological diagnosis of calculi with XPN**

Radiological features	Calculi [staghorn type]	XPN on histopathology	XPN + Renal TB
Calculi (n=18)	15	5	10
CKD with hydronephrosis (n=8)	3	3	2

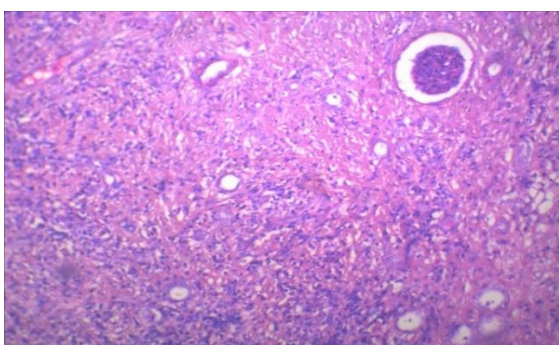
**Table 5: Preoperative diagnosis on radiology**

Radiological profile [pre-operative]	No. of cases	Percentage
CPN with calculi	15	80%
Perinephric abscess with calculi	03	16%
Renal TB	-	-
Renal malignancy	02	4%

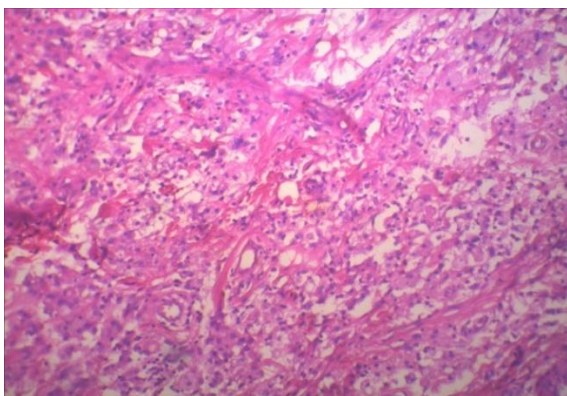
**Fig. 1: Shrunken flabby kidney with distorted Cortico-medullary junction and cystic changes**



**Fig. 2: “Contracted Kidney” with cystic degeneration filled with mucoid and showing orange-streaks-Xanthomatous reaction**



**Fig. 3: Ill Formed Granuloma with Periglomerular and Peritubular-H&E-40X. Inset: Caseous Necrosis Around Tubules; H&E40X**



**Fig. 4: Periglomerular And Peritubular Xanthomatous cells -H&E-40X. Inset: Xanthomatous cells Around Tubules with Langhans giant cells. H&E40X**

## Discussion

Xanthogranulomatous pyelonephritis is a chronic renal infection characterized by destructive granulomatous inflammation of renal parenchyma often associated with nephrolithiasis with a sequelae of “non-functioning kidney”.<sup>(2)</sup> The mean age of occurrence of XGP varies from 45 to 55 years which was in concordance with our study.<sup>(5)</sup> The present study showed mean age of 50 years with female

preponderance was observed by previous workers, coinciding with the present study.<sup>(3,5)</sup>

The exact etiology of XGP is still theoretical but it had been generally accepted that the disease process is associated with long-term obstruction and infection as proved in the present study as well.<sup>(6)</sup> Co morbid conditions were also noted including pregnancy, diabetes mellitus, rheumatoid arthritis, chronic viral hepatitis C, cirrhosis, and obesity as observed in the present study.<sup>(7)</sup>

The present study is in concordance with the observations by Kumar et al<sup>(11)</sup> which states that tuberculosis of renal parenchyma induces and stimulates adjacent granulomatous reaction of the renal tissue especially Xanthogranulomatous reaction.<sup>(11,12)</sup> CT and Ultrasound scan is the mainstay of diagnostic imaging for XGP. However differentiate from a renal abscess/tuberculosis or necrotic renal cell carcinoma (RCC) histopathological examination remains as gold standard method.<sup>(9)</sup>

Grossly the affected renal system becomes shrunken due to extensive fibrosis owning a term of ‘contracted kidney’ having many differentials including hydronephrosis, pelvic calculi, conditions like congenital type obstruction, radiation fibrosis, and carcinoma of the ureter.<sup>(5)</sup> In most instances as observed by researchers, the gross necrotic areas are assumed as inflammatory reaction to cystic and degenerative changes with cortical atrophy often missed without sampling. In the present study, extensive sampling was performed in these necrotic areas which proved to have Tubercular pathology.<sup>(6,9)</sup> Our study is in concordance with the work done by Fallatah et al, which proved extensive sampling of the necrosis in cystic areas reveal underlying renal TB.<sup>(8)</sup>

Microscopically, XPN is characterized by granulomatous mixed inflammatory infiltrate with fibrosis, xanthomatous histiocytes and cholesterol clefts in the background. The changes diffusely or focally involve renal parenchyma and even with involvement of perirenal soft tissue in severe cases.<sup>(12)</sup>

Researchers proved that sampling from the necrotic areas adjacent to xanthomatous streaks, cystic degeneration with mucoid areas show tubular neutrophils, lymphocytes, plasma cells, and multinucleated giant cells with well formed epithelioid cell granulomas admixed with xanthomatous foamy cells[FIG -4].<sup>(13,14)</sup> Similar findings were also observed in our study revealing renal TB which was left undiagnosed preoperatively. Presence of granulomas of the kidney are rare, with the most common entity being tuberculosis.<sup>(12,13)</sup> However other causes of granuloma includes fungal infection, sarcoidosis, interstitial nephritis, drug induced reaction with each entity having classical morphology and associated features.<sup>(14)</sup> The preoperative diagnostic sensitivity of renal tuberculosis ranges from 1-5% as proposed by previous workers which was reflected in the present study.

## Conclusion

Renal tuberculosis is an uncommon renal pathology often under diagnosed preoperatively. Hence combination of a nonfunctioning contracted kidney, a central calculus within a contracted renal pelvis and inflammatory changes with association Xanthogranulomatous pyelonephritis, should pose suspicion of renal tuberculosis must always be included in the differential diagnosis. Nephrectomy remains the treatment of choice and extensive sampling from the necrotic areas of the renal parenchyma adjacent to the foci of calculi and cystic degeneration from the must be taken from the nephrectomy specimen to reveal underlying renal tuberculosis guiding in postoperative treatment.

## References

1. Craig WD, Wagner BJ, Travis MD. Pyelonephritis Radiologic-pathologic review. *Journal of Radiographics*. 2008;28(1):255–277.
2. Schlagenhauer F, Uber E, Staphylmykosen D, Bindegewebes P. Xanthogranulomatous pyelonephritis: clinical experience with 41 cases. *J Pathol and Micro*. 2008;71(2):178–180.
3. Hartman DS, Davis JR, Goldman SM, Isbister SS, Sanders RC. Xanthogranulomatous pyelonephritis: Sonographic-pathologic correlation of 16 cases. *Journal of Ultrasound Med*. 1984;3(11):481–484.
4. Malek RS, Elder JS. Xanthogranulomatous pyelonephritis: a critical analysis of 26 cases and of the literature. *J Urol*. 1978;119(5):589–593
5. Malek R.S, Greene LF, DeWeerd JH, Farrow GM. Xanthogranulomatous pyelonephritis. *British J Urol*. 1972;44(3):296–308.
6. Loffroy R, Guiu B, Watfa J, Michel F, Cercueil JP, Krausé SM. Xanthogranulomatous pyelonephritis in adults: clinical and radiological findings in diffuse and focal forms. *Clin Radiol*. 200;62(9):884–890.
7. Ghazo AL, Ghalayini MF, Matalaka, Al-Kaisi IL, Khader YS. Xanthogranulomatous pyelonephritis: analysis of 18 cases. *Asian J Surg*. 2006;29(4):257–261.
8. Fallatah A, Tarakji M, Amuesi T. Xanthogranulomatous pyelonephritis: a retrospective study of 10 cases and review of the literature. *Saudi J Kidney Dis Transpl*. 2001;12(4):520–524.
9. Mittal BV, Badhe BP. Xanthogranulomatous pyelonephritis—A clinico-pathological study of 15 cases. *J Postgrad Med*. 1989;35(4):209–214.
10. Dwivedi US, Goyal NK, Saxena V. Xanthogranulomatous pyelonephritis: our experience with review of published reports. *ANZ J Surg*. 2006;76(11):1007–1009.
11. Kumar N, Jain S. Aspiration cytology of focal xanthogranulomatous pyelonephritis: a diagnostic challenge. *Diagn Cytopathol*. 2001;30(2):111–114.
12. Masoom S, Venkataraman E, Jensen S, Flanigan RS. Renal FNA-based typing of renal masses remains a useful adjunctive modality: Evaluation of 31 renal masses with correlative histology. *Journal of Cytopathology*. 2009;(2):50–55.
13. Mohanty A, Kim O. Non-functional right kidney in a 50-year-old woman: xanthogranulomatous pyelonephritis. *Arch Pathol Lab Med*. 2005.;129(12):125-29.
14. Nawaz H, Khan S, Hussain I. Xanthogranulomatous Pyelonephritis due to calculi: Report of 63 cases and review of literature. *JPMA*. 2005;(55):387–389.