

## Clinicohistological correlation of psoriasis and immunohistochemical expression of Ki 67

Prakashiny S<sup>1</sup>, Vindu Srivastava<sup>2,\*</sup>

<sup>1</sup>Assistant Professor, Kerala Medical College & Hospital, Palakkad, Kerala, <sup>2</sup>Associate Professor, Dept. of Pathology, Sree Balaji Medical College & Hospital, Chennai

**\*Corresponding Author:**

Email: vinsripath@gmail.com

### Abstract

Skin is considered as the largest organ of the body. Psoriasis is a chronic papillosquamous disorder of skin affecting 1-2% of population in all geographic areas.<sup>(4)</sup> There is a seven fold increase in the field of epidermal cell proliferation. Psoriasis is a disease characterized by chronic, recurrent exacerbation and remission that are emotionally and physically debilitating, therefore accurate diagnosis by histopathologist is essential. Psoriasis is enormously variable in its duration and extent. There are several morphological variants. Psoriasis has different clinical variants which mimics diverse dermatological condition. Histopathology is required to confirm the diagnosis and subtype the lesion. Recent advances in cell kinetics, immunology and molecular biology had increased our understanding of the etiopathogenesis of keratinocyte proliferation in this disorder. Ki 67 is a proliferative marker which is increased in keratinocytes of psoriatic patients.

In this study we have analysed various patterns of psoriasis in adults and paediatric age group with clinicohistopathological correlation. Immunohistochemical staining with Ki 67 was also done to study the proliferative index in psoriatic skin epidermis in both adult and paediatric age group.

**Keywords:** Psoriasis, Histopathology, ki 67, Keratinocytes, Itchy lesions

### Introduction

The term psoriasis was coined by Ferdinand van Hebra in 1841. It has also been described by Hippocrates. It is a proliferative and inflammatory disease of the skin which affects all type of population. The exact etiology and trigger for the disease are unknown. Environmental, genetic and immunological factors play a role. There may be many millions of people with potential to develop psoriasis, with only the correct combination of factors lead to the occurrence of this disorder. The epidermal transit time (the time it takes for a basal cell to mature and differentiates into corneocytes) is reduced in psoriasis from an average of 28 days to 7-8 days. The incidence of Psoriasis in India is 0.5 – 5.6%. The incidence varies worldwide due to variations in race, geographic and environment.<sup>(4,10,12)</sup>

Psoriasis may be divided into Psoriasis vulgaris, generalized pustular and localized pustular psoriasis. Guttate psoriasis, is a distinct form of psoriasis which follows an infection, especially due to beta haemolytic streptococci. Psoriatic erythroderma is a dermatological emergency and it can cause significant morbidity and mortality. Pustular psoriasis refers to a group of entities characterized by the development of multiple sterile pustules.

Clinically psoriasis vulgaris is characterized by pink to red papules and plaques of variable size, sharply demarcated, dry and covered with fine silvery scales. When the scales are removed by gentle scrapping, the bleeding points are seen which is called as Auspitz sign. It is one of the characteristic clinical feature of psoriasis.<sup>(12)</sup> Prognosis of psoriasis is varied

Psoriasis is characterized pathologically by hyperproliferation of keratinocytes and inflammation of the epidermis as well as dermis Fig. These changes are due to a T-lymphocyte mediated skin immune response to unidentified antigenic stimuli. Keratinocytes from psoriatic epidermis show rapid migratory and proliferative activities.<sup>(4)</sup>

The Ki-67 antigen, a 345-395 kD protein complex is expressed during all non-G0 phases of the cell cycle, and hence is a marker for those cells participating in cell proliferation.

The pool of proliferating keratinocytes is significantly expanded, because of the emergence of amplifying supra basal cells. These so-called transit cells, which normally undergo terminal differentiation, have renewed mitotic activity.

Childhood psoriasis is a well known entity. It differs from adult psoriasis, the guttate form being most prevalent. On the contrary, generalized pustular psoriasis patterns are rare in childhood, with less than 100 reported cases. Generally childhood psoriasis is twice prevalent in females compared to males. Infection (e.g. sore throat) is the most common precipitating factor. The earlier the age of onset, the more severe the disease will be.<sup>(4,10)</sup>

The microscopic picture of psoriasis is characterized by<sup>(4,12)</sup> parakeratosis, elongation and clubbing of rete ridges. The epithelium over the suprapapillary region is thinned. It is from these points that bleeding occurs when the scales are peeled off.

- Tortuous dilated capillaries extending high in the papillae are prominent.

- Intraepithelial microabscesses (Munros abscesses) are a common but not invariable finding.

Amin MM, Azim ZA.(2012)<sup>(1)</sup> did a immunohistochemical study of the association between osteopontin, Ki67, CD34 and histopathological features in Psoriasis. The study concluded that Osteopontin (OPN) expression in Psoriasis is related to Ki67 and CD34 expression supporting its role in the pathogenesis of psoriasis

### Materials and Method

The present study included 100 cases of clinically and histologically diagnosed as psoriasis. Clinical details were provided by Dermatology department and skin biopsy of the patient diagnosed or suspected as psoriasis was sent to pathology department for histopathological diagnosis in 10% neutral buffered formalin.

Haematoxylin and eosin stained sections of skin biopsy were prepared to assess the histopathological diagnosis.

Immunohistochemistry with Ki67 was used to study the proliferative index of skin epithelial cells in psoriasis.

### Observation

The clinical and histopathological correlation study of these patients and also a comparative study between pediatrics and adult age groups of these patients.

Out of 100 there were 86 cases of adult age group and 14 pediatric.(Chart 1) In adults there were 49 males and 33 females. In pediatrics age group there were 7 males and 7 females. Clinically the duration of disease was from seven days to five years. Out of 100 cases 86 cases were clinically diagnosed as psoriasis other 14 had different dermatological diagnosis which are confirmed histologically as psoriasis. Most common presentation was scaly itchy lesion. In two adult cases nail pitting was seen. It was also observed the onset of disease was earlier in female.

Histologically all cases showed elongated hyperkeratosis, parakeratosis with irregular elongation of rete ridges, dilated blood vessels in the suprapapillary dermis (Fig. 2) as compared to normal skin (Fig. 1). Similar histological findings were also seen in pediatrics skin biopsy(Fig. 3).

The most common type of psoriasis was psoriasis vulgaris.

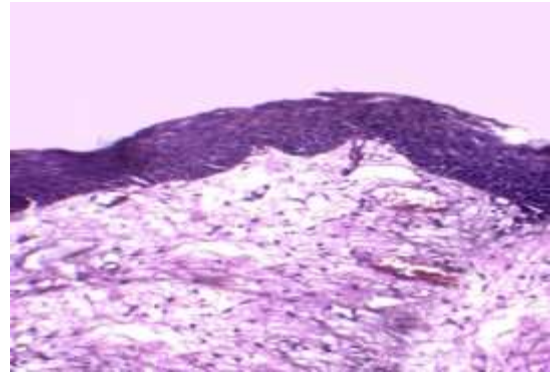


Fig. 1: H&E stained section of normal adult skin - low power view (100x)

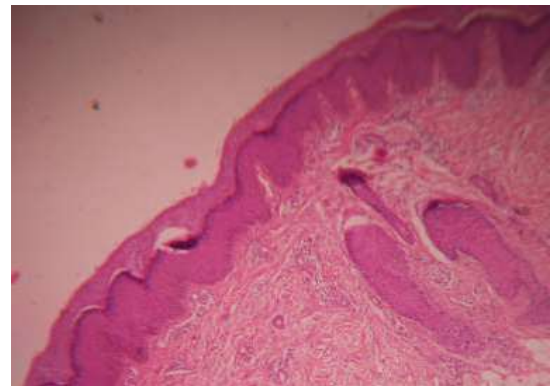


Fig. 2: H&E STAINED section of psoriasis vulgaris in adult showing hyperkeratosis, acanthosis, broad elongated rete pegs- low power view(100x)

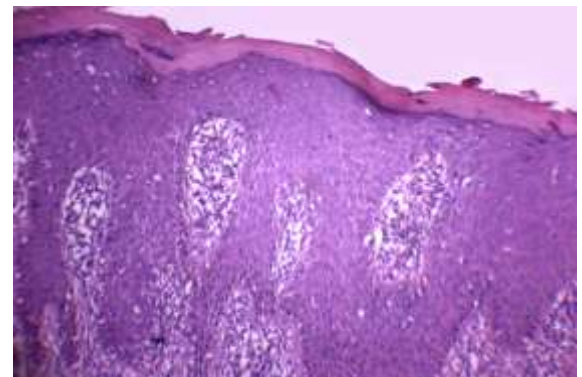
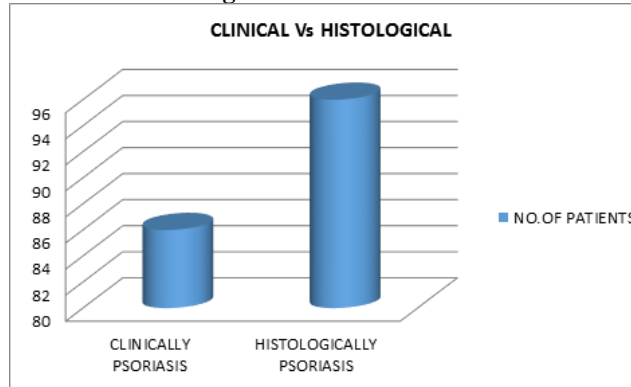


Fig. 3: H&E STAINED sections of psoriasis vulgaris in child, showing parakeratosis, broad elongated rete pegs and with dilated blood vessels in dermal papillae and aggregates of chronic inflammatory cells in upper dermis-low power view(100x)

**Clinical Vs Histological correlation**



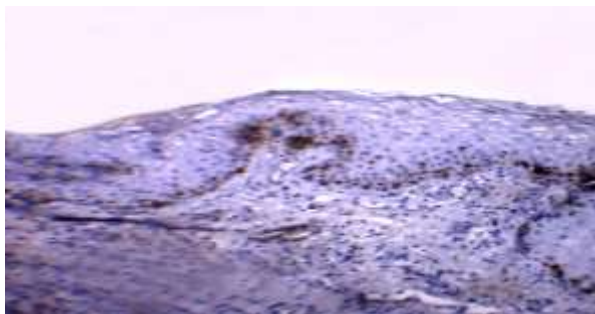
Expression of Ki 67 was indicated by presence of yellow to brown granules in the nucleus. Ki 67 scoring was done on staining pattern of nuclei and number of positive keratinocytes for ki67 positivity index is the percentage of Ki 67 positive cells.

In adult psoriatic patients the mean proliferative index was 20.68% (Fig. 6A, B) as against 6.0 of normal skin (Fig. 4A). Similar findings were seen in paediatric cases.(Fig. 7A, B).

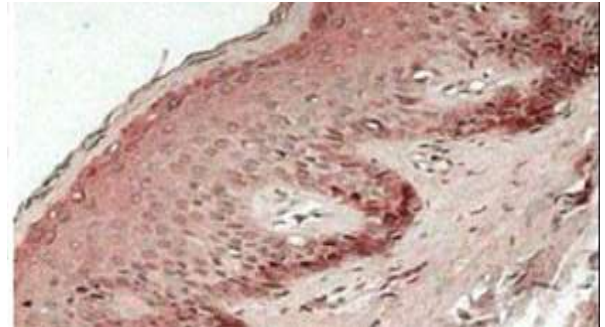
These findings are illustrated in Table 1.

**Table 1: Ki67 scoring in normal skin and those with psoriasis**

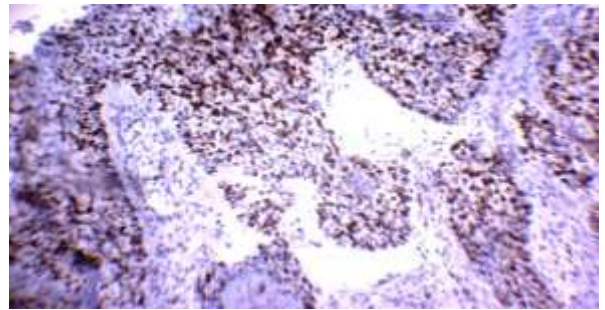
	Ki67 grade	Ki67 percentage (average)
Normal child	1	8%
Normal adult	1	6%
Psoriasis vulgaris-child	2	22.39%
Psoriasis vulgaris-adult	2	21.30%
Pustular psoriasis adult	2	14.92%



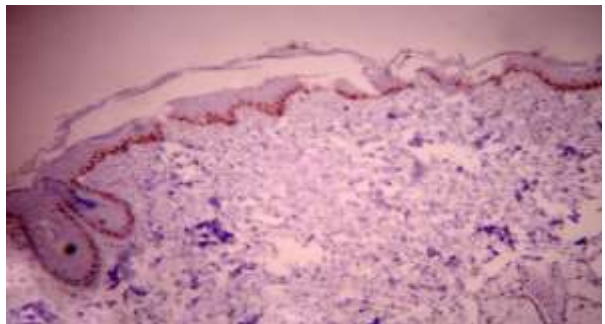
**Fig. 4A: IHC-Ki67 staining of normal adult skin- low power view(100x)**



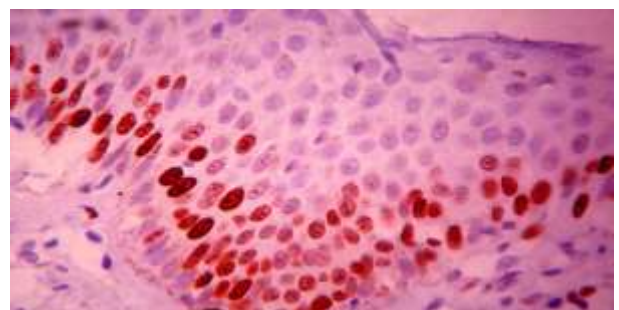
**Fig. 4B: IHC-Ki67 stained section of normal skin in child –low power view(100x)**



**Fig. 5: IHC-Ki67 stained section of squamous cell carcinoma as positive control**

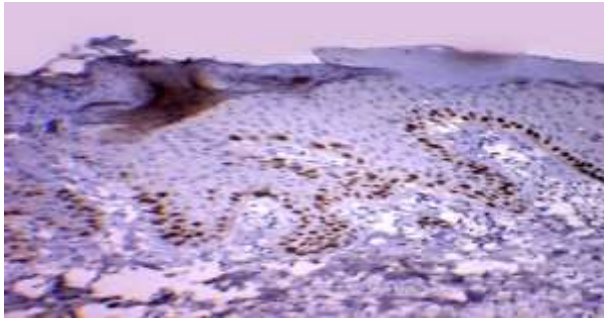


**Fig. 6: IHC Ki67 stained section of psoriasis vulgaris in adult showing increased positivity in the basal and suprabasal epidermal cells- low power view(100x)**

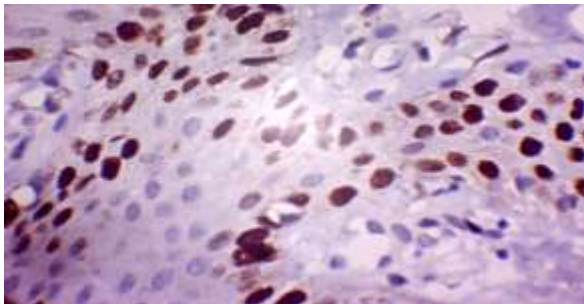


**Fig. 6A: IHC Ki67 stained section of psoriasis vulgaris in adult showing increased positivity in the basal and suprabasal epidermal cells-high power view (400x)**





**Fig. 7A: IHC KI67 staining in psoriasis vulgaris in a child shows increased positivity in basal and suprabasal epidermal cells-low power view(100x)**



**Fig. 7B: IHC ki67 staining in psoriasis vulgaris in a child shows increased positivity in basal and suprabasal epidermal cells-high power view(400x)**

## Discussion

Psoriasis is a genetically determined inflammatory and proliferative disease of the skin characterized by dull red sharply, demarcated scaly plaques. Many morphological variants of psoriasis are described which may create confusion in the diagnosis. Histopathology is required for the confirmation of the diagnosis.

David Elder<sup>(12)</sup> has considered histopathology as a gold standard for the diagnosis of most dermatological conditions including psoriasis.

Approximately 1-2% of the global population and 0.5-6% of Indian population are affected by this chronic disorder, which has a significant social and economic impact

Clinical features when considered alone may not be reliable as they vary with both disease duration and treatment. The histological material constitutes definite hard evidence which can be preserved and would continue to be available for future review, if necessary. Psoriasis can develop at any age, peak age of onset is 15 to 25 years according to Hensler T et al.<sup>(6)</sup> Psoriasis is common in younger age groups, most of the cases studied were between 20-40 years, third decade in particular.<sup>(7)</sup> Women had lower age of onset in young adult age group of 15-30 years. Males showed higher age of onset being above 50 years of age group. In case of adults our study showed M:F ratio as 1.48:1.

Hensler T et al, in the year 1985 reported, peak incidence of psoriatic patients were in the age group of 15-25 years.<sup>(6)</sup> Karumbaiah et al reported, in the year

2014, the peak incidence of psoriatic patients as in the age groups of 20-40 years.<sup>(7)</sup>

The occurrence of psoriasis was observed to be more in the younger age group of 15-30 years in female, whereas males are affected more in their elderly age of above 50 years. Psoriasis is relatively uncommon, but a burdensome disease in children. Nanda A, Kaur S, Kaur I, Kumar B (1990)<sup>(15)</sup> studied one hundred and twelve cases of childhood psoriasis, constituting 5% of all psoriasis patients over a period of nine years. There were 57 male and 55 female patients. Age of onset ranged from 1 month to 13 years, with a mean and median age of 7 years. The commonest form of psoriasis found was plaque (69.6%), followed by guttate (25.9%). Infection was the most common triggering factor, occurring in 15.2% of cases. Many of these findings are at variance with observations reported elsewhere for this age group. Al-Fouzani AS, Nanda A (1994)<sup>(15)</sup> studied one hundred ninety cases of childhood (age birth-12 yrs) psoriasis constituting 0.3% of the dermatologic outpatients. Girls outnumbered boys by a ratio of 1.5:1.

R Manoharan, Jayakar Thomas, P K Raneesha et al (2013)<sup>(14)</sup> did a study of childhood psoriasis in 344 psoriatic patients and reported the increased incidence of childhood psoriasis to 17.15%. The male female ratio in children was observed to be 1:1.03. Kumar et al, reported that psoriasis in children accounted for 12.5% of total psoriatic patients, in a study of 419 cases of psoriasis.<sup>(9)</sup> Age of onset ranged from 4 days to 14 year with an equal sex incidence in children.

In our study, 14% of cases were childhood psoriasis. Age group ranged from 3 years to 13 years. Sex incidence was found to be equal, in the ratio of 1:1, which is in agreement with the above studies.

Besides being, cosmetically disabling, psoriasis leads to morbidity due to pruritis and burning sensation. Okhandiar et al<sup>(16)</sup> reported 95% cases had pruritis. Bedi reported, itching was a significant complaint in 81% of psoriatic patients.<sup>(3)</sup> Kaur et al, reported pruritis complained by psoriatic patients to be 65%.<sup>(8)</sup>

In our study, 95% of psoriatic patient had itchy nature of lesion, which is compatible with the above studies.

Literature review<sup>(4,11,13)</sup> of histopathology of skin psoriatic lesions include: parakeratosis associated with focal orthokeratosis, hyperplasia with elongation of rete ridges and suprapapillary epidermal thinning. The rete ridges may be clubbed, branched or fused at their bases, with mononuclear leukocyte infiltrates in the lower half of the epidermis. Dilated, tortuous papillary blood vessels surrounded by a mixed mononuclear and neutrophil infiltrate as well as extravagated erythrocytes are seen. Invasion of the epidermis with leukocytes particularly in the suprapapillary region is usually evident. Spongiform pustule of Kogoj and Munro micro abscesses in the stratum corneum are seen in a good percentage of cases.

In our study, the most common histologic findings were hyperkeratosis (83.33%), parakeratosis (67.7%), acanthosis (71.8%), elongated rete pegs (59.37%), diminished or absent granular layer (39.58%),

suprapapillary thinning (39.58%), monomicroabscess (6.25), spongioform pustules of Kogoj (4.16%) (Fig. 1, 2) Dermal changes like inflammation and congested capillaries were found to be 75%.

**Table 2: Comparison of histologic features of Psoriasis**

Histologic Features	Karumbaiah et al	Younas M et al	Present Study
Hyperkeratosis	77.27%	100%	83.33%
Acanthosis	86.36%	100%	71.8%
Parakeratosis	72.72%	78.5%	67.70%
Suprapapillary thinning	40.90%	Majority of cases	39.58%
Munro microabscess	22.72%	71.4%	6.25%
Spongiform pustules	4.54%	42.8%	4.16%
Granular layer	22.72%	Majority of cases	39.58%
Dermal inflammation	81.81%	Majority of cases	75%
Vessel changes	86.36%	Majority of cases	75%

Weinstein GD, McCullough JL, Ross PA (1985).<sup>(17)</sup> These authors studied the cell proliferation kinetics of psoriatic epidermal cells and the results compared to similar studies for normal epidermis Fig. The cell kinetic basis for the pathophysiology of psoriasis consists of at least 3 proliferative abnormalities in comparison to normal epidermis.

WY Ma, L Zhuang et al,<sup>(18)</sup> in the year 2012, reported that ki67 positivity index of psoriatic patients as 26.47+- 3.66% as against the normal patients of 1.23+- 0.38%. Dorota Jesionek kupnika et al (2013),<sup>(5)</sup> observed increased expression of ki67 in psoriatic lesions. The ki67 positivity ranged from 0 to 30% in psoriatic patients as against 0 to 10% in normal skin.

In our study, the mean positivity index of ki67 was observed to be 20.93% in psoriasis which is in close relation with the above 2 studies.

Comparison between studies has been illustrated in Table 3.

**Table 3: Comparison of ki67 positivity index in Psoriasis**

Study	Year	Ki67 Positivity Index
WY MA et al	2012	26.47+-3.66%
Dorota Jesionek Kupnicka et al	2013	0-30%
Present study	2014	20.93%

## Summary

Psoriasis is chronic papillosquamous disease seen both in adult and paediatric population Duration of disease may be as less as one week to several years. The most common presentation is silvery scaly plaques. Clinicohistologic concordance of our study of 100 cases was 83. Histopathology is essential for the diagnosis of psoriasis along with clinical details. The morphological types of psoriasis can be identified by histopathology which is a key to better patient care. Histological confirmation helps in ruling out diagnostic dilemma to

psoriasis like alteration in skin, which often gives a confusion to the clinician. Immunohistochemistry with Ki67 showed the proliferative index of suprabasal epidermal cells in cases of adult psoriasis at the rate of 10-30% as against 6% in normal adult skin. In paediatric age group Ki67 index is at the rate of 12-28% as against 8% in normal skin of child. More studies would with ki 67 would be helpful to assess its usefulness as diagnostic and prognostic marker in psoriatic skin. Ki 67 positivity index can be used to assess disease severity and also in cases which needs further evaluation.

## References

- Amin MM, Azim ZA. Immunohistochemical study of osteopontin,ki67 and CD34 of Psoriasis in Mansoura, Egypt. Indian J Pathol Microbiol 2012;55:56-60.
- Anne Morris, Maureen Rogers, Gayle Fischer, and Katrina Williams. Childhood Psoriasis: A Clinical Review of 1262 Cases Pediatric Dermatology 2001 May/June; 18(3) 188.
- Bedi TR. Clinical profile of psoriasis in North India. Indian J Dermatol Venereol Leprol 1995;61:202-5.
- Camp. R.D.R. Chapter 35. Rooks Textbook of Dermatology; 2nd Edition.
- Dorota Jesionek-Kupnicka, Dorota chomiczewska-skora, Helena Rotsztejn. Influence of phototherapy in Psoriasis on ki67 Antigen Expression. Pol J Pathol 2013;2:96-103.
- Hensler T, Christophers E. Psoriasis of early and late onset: Characterization of two types of psoriasis vulgaris. J Am Acad Dermatol 1985;13:450-6.
- Karumbaiah K P et al; Sch. J. App. Med. Sci;2014;2(1c):298-302.
- Kaur I, Handa S, Kumar B. Natural history of psoriasis: a study from the Indian subcontinent. J Dermatol 1997;24:230-4.
- Kumar B, Jain R, Sandhu K, Kaur I, Handa S Epidemiology of childhood psoriasis: a study of 419 patients from northern India. Int J Dermatol. 2004 Sep;43(9):654-8.
- Lebwohl Mark Psoriasis The Lancet 2003;361:1197-204.
- Leigh IM, Pulford KA, Ramaekers FC, Lane EB Psoriasis: maintenance of an intact monolayer basal cell differentiation compartment in spite of hyperproliferation. Br J Dermatol. 1985 Jul;113(1):53-64.

12. Levers histopathology of skin Eighth Edition; Lippincot pg: 156-161.
13. Lumholt G. Psoriasis, Prevalence, Spontaneous Course and Genetics. Copenhagen: G.E.C., Gad; 1963. p. 31-6.
14. Manoharan R, Thomas J, Raneesha P K, Ragavi S, Manoharan D, Cynthia S. A study of childhood psoriasis. *Indian J Paediatr Dermatol* 2013;14:23-5.
15. Nanda A, Kaur S, Kaur I, Kumar B Childhood psoriasis: an epidemiologic survey of 112 patients. *Pediatr Dermatol.* 1990 Mar;7(1):19-21.
16. Okhandiar RP, Banerjee BN. Psoriasis in the tropics: An epidemiological survey. *J Indian Med Assoc* 1963;41:550-6.
17. Weinstein GD, Mccullough JL, Ross PA. Cell kinetic basis for pathophysiology of psoriasis. *J Invest Dermatol.* 1985 Dec; 85(6):579-83.
18. WY Ma, L Zhuang DxCai, H Zhong, C Zhao, Q Sun. Caveolin-1 Expression and clinical Severity in Psoriasis Vulgaris *Journal of International Medical Research* 2012;40(5):1745-1751.
19. Z Morris LF, Phillips CM, Binnie WH, et al. Oral lesions in patients with psoriasis: a controlled study. *Cutis.* 1992 May; 49(5):339-44.
20. Camp. R.D.R. Chapter 35. *Rooks Textbook of Dermatology*; 2nd Edition.