



## Case Report

# Cutaneous metastasis masquerading an internal malignancy, hilar cholangiocarcinoma – A case report and review of literature

Radhika S<sup>1\*</sup>, Ilavendiran S<sup>2</sup>, Narendhran RT<sup>3</sup>, Kavita Vijayakumar<sup>4</sup>, Anand Selva Kumar<sup>5</sup>

<sup>1</sup>Dept. of Pathology, Velammal Medical College Hospital and Research Institute, Madurai, Tamil Nadu, India

<sup>2</sup>Dept. of Dermatology, Velammal Medical College Hospital and Research Institute, Madurai, Tamil Nadu, India

<sup>3</sup>Dept. of Medical Gastroenterology, Velammal Medical College Hospital and Research Institute, Madurai, Tamil Nadu, India

<sup>4</sup>Senior Consultant Pathologist and Chief of Laboratory, Metropolis Healthcare Ltd, Chennai, Tamil Nadu, India

<sup>5</sup>Meenakshi Mission Hospital and Research Centre, Madurai, Tamil Nadu, India



## ARTICLE INFO

### Article history:

Received 12-10-2023

Accepted 15-12-2023

Available online 31-01-2024

### Keywords:

Metastasis

Cutaneous

Signet ring

Adenocarcinoma

## ABSTRACT

Cutaneous metastases can be a masquerade of an internal malignancy and is rare accounting for 0.7-0.9% of cancer patients. Cutaneous metastasis of adenocarcinoma histologic subtype indicates widespread disease and poor prognosis. Herein, we report an exceedingly rare case of cutaneous metastasis, possibly of pancreaticobiliary origin and review of literature on cutaneous metastasis. A 48-year-old woman presented with massive ascites since 4 months. Multiple asymptomatic skin nodules were noted. PET-CT showed extensive ill defined skeletal metastasis and low grade metabolically active ill-defined lesions in the bilateral adnexal region – suspicious for metastatic deposits. Upper gastrointestinal tract (GI) endoscopy and colonoscopy did not reveal any specific lesion. Biopsy from the nodule in the left forearm showed cords, a few vague acinar structures and singly lying cells including a few signet ring cells consistent with poorly differentiated adenocarcinoma with few signet ring cell features. On Immunostaining, the neoplastic cells showed diffuse membranous positivity for Cytokeratin (CK), Cytokeratin 7 (CK 7), CK19, CDX-2 and negative for TTF-1, CK20, PAX 8 and WT-1. This immunohistochemical profile favours an adenocarcinoma possibly of pancreaticobiliary origin. MR Cholangiopancreatogram showed ill-defined T2 hypointense diffusion restriction at perihilar region involving the confluence, cystic duct and common hepatic ducts – likely neoplastic etiology (Hilar cholangiocarcinoma – Bismuth – Corlette type II). Palliative chemotherapy and radiotherapy was initiated and the patient is on follow-up. This case emphasizes that there should be a strong suspicion of cutaneous metastases in case of any skin nodule with non pinchability of skin especially in old age as it could be the initial presentation of an underlying malignancy and it requires a multidisciplinary approach.

This is an Open Access (OA) journal, and articles are distributed under the terms of the Creative Commons Attribution-NonCommercial-ShareAlike 4.0 License, which allows others to remix, tweak, and build upon the work non-commercially, as long as appropriate credit is given and the new creations are licensed under the identical terms.

For reprints contact: [reprint@ipinnovative.com](mailto:reprint@ipinnovative.com)

## 1. Introduction

Cutaneous metastases can be a masquerader of an internal malignancy and can be encountered in 0.7-0.9% of cancer patients. They can be the first manifestation of a metastatic spread of an internal malignancy. In women, cutaneous

metastasis is commonly seen in breast carcinoma, colorectal carcinoma and malignant melanoma. In men, malignant melanoma, lung carcinoma and colorectal carcinoma are the most common causes of cutaneous metastases. Cutaneous metastases may be asymptomatic or be associated with pain and tenderness. Punch biopsy or excisional biopsy along with immunohistochemistry is necessary for a definitive diagnosis. Upto a third of cutaneous metastasis

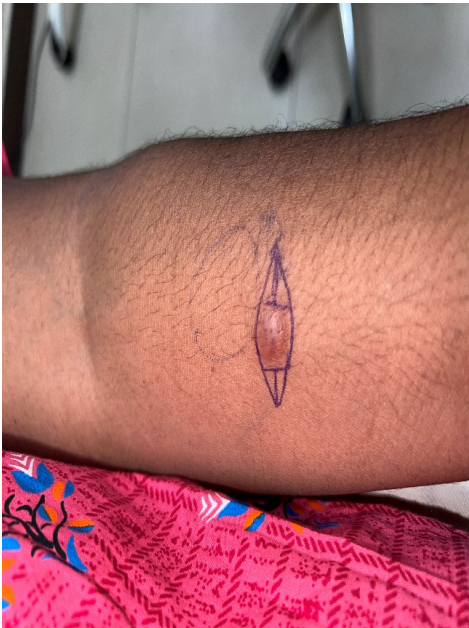\* Corresponding author.

E-mail address: [radhikaradix89@gmail.com](mailto:radhikaradix89@gmail.com) (Radhika S).

are diagnosed before or simultaneously with the primary tumour. The early clinical recognition of cutaneous metastasis is important so as to diagnose a previously unidentified primary tumour or it might be an early sign of recurrence of a malignant tumour. Diagnosis of cutaneous metastasis has therapeutic and prognostic implications and warrants a high index of suspicion together with a detailed clinical, radiological and histological correlation for the correct diagnosis.

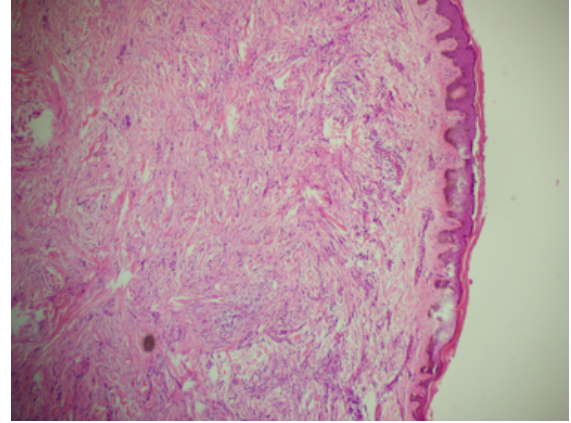
## 2. Case History

A 48 year lady presented with ascites and was incidentally noted to have multiple nodules in the skin (Figure 1). There was history of loss of appetite for almost 10 days. On examination, multiple well defined skin coloured nodules of size 0.5x0.2cm to 2x2cm were noted all over the body in the face, back, arms, forearms and face. Nodules were firm in consistency, fixed and the skin over the nodules was not pinchable. A clinical diagnosis of subcutaneous granuloma annulare/sarcoidosis/cutaneous metastasis/nodular vasculitis was suspected. Punch biopsy was done from nodule in the left forearm. Histopathological examination of the biopsy showed cords, a few vague acinar structures and singly lying cells including a few signet ring cells consistent with poorly differentiated adenocarcinoma with few signet ring cell features (Figures 2, 3 and 4). On Immunohistochemistry (IHC), the neoplastic cells showed positivity for Cytokeratin (Figure 5), Cytokeratin 7.

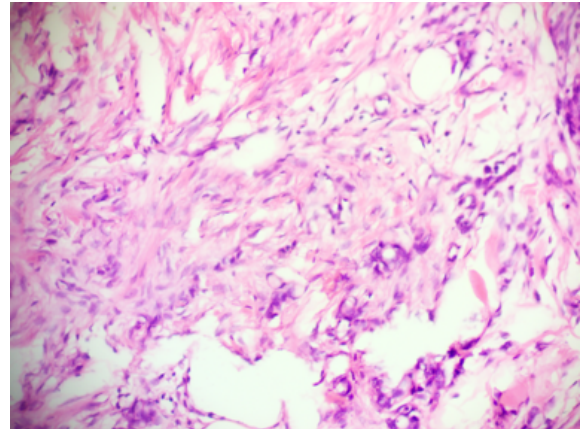


**Figure 1:** Skin nodule in left forearm

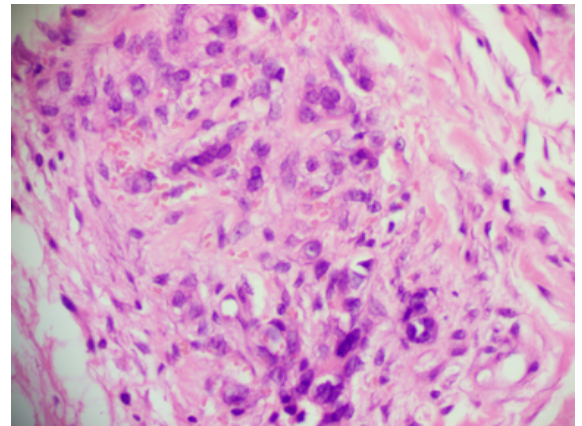
(CK 7), CK19 and CDX-2 and negative for TTF-1, CK20 and PAX 8 - which is possibly of pancreaticobiliary origin. PET-CT showed extensive ill defined skeletal



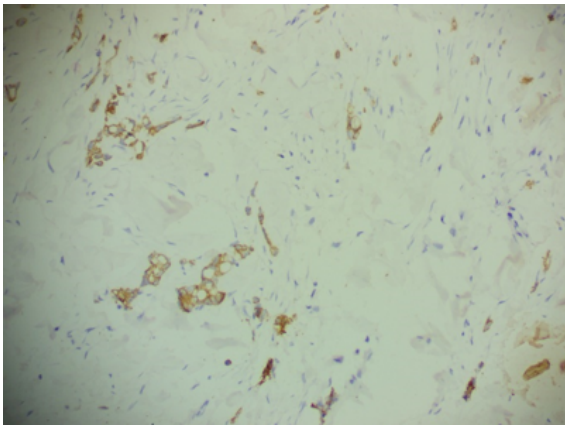
**Figure 2:** Skin biopsy showing collagenised dermis with atypical cells (40x)



**Figure 3:** Skin biopsy showing singly lying atypical cells and few vague acinar structures (100x)



**Figure 4:** Skin biopsy showing singly lying atypical cells and few vague acinar structures (200x)



**Figure 5:** Immunohistochemistry for Cytokeratin highlighting the singly lying atypical cells and few vague acinar structures (200x)

metastasis and low grade metabolically active ill-defined lesions in the bilateral adnexal region – suspicious for metastatic deposits. Palliative chemotherapy was initiated with Inj. Paclitaxel and Inj. Carboplatin AUC4 every 3 weeks and palliative radiotherapy for the symptomatic pelvic secondaries (37.5 Gy in 15 fractions) with weekly Carboplatin of AUC2. MR Cholangiopancreatogram showed ill-defined T2 hypointense diffusion restriction at perihilar region involving the confluence, cystic duct and common hepatic ducts – likely neoplastic etiology (Hilar cholangiocarcinoma – Bismuth – Corlette type II). Mammogram showed ill-defined irregular heterogenous hypochoic lesion at 12-1 O’ clock position of left breast, biopsy of which showed carcinoma - IHC was suggested to ascertain the exact origin of the tumour but it was not performed. Per abdominal examination showed ascites. Complete blood counts were within normal limits. Ascitic fluid analysis revealed a low SAAG, high protein fluid and negative for malignant cells. CA-125 was within normal limits. Liver function tests revealed normal serum bilirubin levels and elevated alkaline phosphatase levels.

### 3. Discussion

Cutaneous metastasis of internal malignancies is rare, accounting for 0.7%–0.9% of all malignancies and less than 4% of abdominal malignancies.<sup>1</sup> It can be the first manifestation of an underlying malignancy in 0.8% of the cases<sup>1</sup>. Carcinoma of unknown primary site (CUPS) is defined as histologically confirmed metastasis in the absence of an identifiable primary tumour. This can account for upto 3 to 5% cases.<sup>2</sup> Cutaneous metastasis in the absence of other distant metastases only occur in 6.4% to 7.8% of cases. The rate of cutaneous metastasis was 5.3% in a meta-analysis published in 2003 by Krathen et al. which reviewed 1080 cases of cutaneous metastasis in 20,380 cancer patients.<sup>3</sup>

In a study by Brownstein and Helwig, in men, the most common malignant tumours that metastasized to the skin were carcinoma of the lung (24%), colorectal carcinoma (19%), melanoma (13%), and oral squamous cell carcinoma (12%), whereas, in women, the most common tumours were breast cancer (69%), colorectal carcinoma (9%), melanoma (5%), and carcinoma of the ovary (4%).<sup>4</sup> Kauffman and Sina suggested that metastatic spread of adenocarcinoma to the skin and subcutaneous tissue could be caused by lymphatic and hematogenous spread, direct extension, or implantation during surgery.<sup>5</sup>

Cutaneous metastasis usually presents as a rapidly growing mobile, round or oval nodules of firm or elastic consistency or as an ulcerated lesion. Various clinical forms of cutaneous metastasis includes telangiectatic carcinoma, Zosteriform or herpetiform metastasis.<sup>6</sup> Face and scalp are most commonly affected by metastases. Gastrointestinal cancers often give rise to metastases in the abdomen and pelvis which can spread along the urachus to produce umbilical nodules known as Sister Mary Joseph’s nodules.<sup>7</sup> Sister Mary Joseph’s nodule or umbilical metastasis presents as single or multiple, indurated umbilical or periumbilical nodules that can sometimes ulcerate or have a friable appearance. Clown nose is cutaneous metastasis on the tip of the nose, typically from a carcinoma of the lung or breast. Renal cell carcinoma typically metastasizes to the scalp and can be confused with hemangiomas or pyogenic granulomas due to high vascularity. Cutaneous metastasis from hepatocellular carcinoma often occurs on the fingers, palms, soles or the back. Extensive cutaneous involvement of metastatic breast cancer can simulate cellulitis (carcinoma erysipeloides) or a breast-plate of armor (“en cuirasse” pattern). Cuirasse metastatic carcinoma is characterized by diffuse morphea-like induration of the skin. Pain and pruritus may be the associated features, unlike cutaneous metastases, which usually present as asymptomatic, painless, firm or doughy skin-colored papules or nodules.<sup>8</sup> Thus, the site of cutaneous metastasis can suggest a possible origin of the primary tumour. Detailed evaluation of clinical presentation with emphasis on cytomorphological features, immunohistochemistry and imaging aids in identification of an unknown primary.

The differential diagnosis of cutaneous metastasis based on the clinical findings includes both benign (dermatofibroma, pyogenic granuloma, epidermal cyst, adnexal tumours) and malignant (basal or squamous cell carcinoma, melanoma, Merkel cell tumour, angiosarcoma).<sup>6</sup> Histological clue which is suggestive of cutaneous metastasis includes the presence of neoplastic cells within the lymphatics or blood vessels, localisation of the lesion in the deep reticular dermis and hypodermis and the presence of neoplastic cells running along the bundles of collagen. Metastatic tumours typically develop as round

nodules located in the dermis or hypodermis and are not usually in contact with the epidermis. This Grenz zone is much more common in metastatic lesions. Fibrosis and inflammation may be evident. As cutaneous metastasis are usually asymptomatic, active screening is essential. Histopathological examination and immunohistochemistry is required in correlation with the radiological findings in order to ascertain the exact site of the primary tumour.

Recent reports have found that in cases of metastatic malignancies of unknown primary origin, primary sites are identifiable in only 20-25% of cases before death.<sup>9</sup> The mean survival after the diagnosis of cutaneous metastasis is 50% at 6 months. Benmously et al. and Schoenlaub et al. reported a better survival in cases of breast cancer than in other types of cancer.<sup>10</sup>

#### 4. Conclusion

Early recognition of cutaneous metastases can facilitate prompt and accurate diagnosis resulting in early treatment. Cutaneous metastatic lesions may, therefore, have therapeutic and prognostic implications. A high index of suspicion is warranted to timely diagnose such manifestations of hidden malignancies with a combination of detailed clinical, histo-cytological and imaging evaluation.

#### 5. Conflict of Interest

None.

#### 6. Source of Funding

None.

#### References

1. Gupta N, Malik D, Verma R, Belho ES, Manocha A. Cutaneous metastasis from visceral organs: 18F-fluorodeoxyglucose positron emission tomography-computed tomography scan aiding in localizing primary site. *Indian J Nuclear Med.* 2019;34(3):205–8.
2. Pathania V, Sandhu S, Tripathy DM, Oberoi B. Cutaneous metastasis: a prelude to a sinister outcome. *Asian J Oncol.* 2020;6(1):35–40.
3. Dehal A, Patel S, Kim S, Shapera E, Hussain F. Cutaneous metastasis of rectal Cancer: A case report and literature review. *Perm J.* 2016;20(1):74–8.
4. Sharma G, Kumar P, Veerwal H, Singh P, Gupta S, Dhingra V, et al. Cutaneous Metastases as Initial Presentation of Lung Carcinoma. *Cureus.* 2021;13(5):e15344. doi:10.7759/cureus.15344.
5. Dehal A, Patel S, Kim S, Shapera E, Hussain F. Cutaneous metastasis of rectal Cancer: A case report and literature review. *The Permanente Journal.* 2016;20(1):74–8.
6. Martínez M, Parra-Blanco V, Izquierdo J, Fernández RR. Metástasis cutáneas de origen visceral. *Actas Dermo-Sifiliográficas.* 2013;104(10):841–53.
7. Tso S, Brockley J, Recica H, Ilchyshyn A. Sister Mary Joseph's nodule: an unusual but important physical finding characteristic of widespread internal malignancy. *Br J Gen Pract.* 2013;63(615):551–2.
8. Lakshmi C, Pillai SB, Sharma C, Srinivas C. Carcinoma en cuirasse of the breast with zosteriform metastasis. *Indian J Dermatol.* 2010;76(2):215. doi:10.4103/0378-6323.60544.
9. Lido P, Paolino G, Feliziani A, Santurro L, Montuori M, Sanctis F, et al. Cutaneous metastasis of unknown primary presenting as massive and invasive abdominal lesion: an elective approach. *An Bras Dermatol.* 2015;90(6):879–82.
10. Mekheal E, Kania B, Hawran RA, Kumari P, Kumar V, Maroules M. Carcinoma erysipeloïdes: an underdiagnosed phenomenon of cutaneous metastases of breast cancer. *American Journal of Case Reports.* 2022;24.

#### Author biography

**Radhika S**, Assistant Professor

**Ilavendiran S**, Assistant Professor

**Narendhran RT**, Consultant Gastroenterologist & Head of Department

**Kavita Vijayakumar**, Senior Consultant Pathologist and Chief of Laboratory

**Anand Selva Kumar**, Radiation Oncologist

**Cite this article:** Radhika S, Ilavendiran S, Narendhran RT, Vijayakumar K, Kumar AS. Cutaneous metastasis masquerading an internal malignancy, hilar cholangiocarcinoma – A case report and review of literature. *IP J Diagn Pathol Oncol* 2024;9(1):69-72.