

Content available at: <https://www.ipinnovative.com/open-access-journals>

IP Journal of Diagnostic Pathology and Oncology

Journal homepage: <https://www.jdpo.org/>

Case Report

Case report: Pediatric acute lymphoblastic leukemia with trisomy 5 as sole cytogenetic abnormality

Nidhi R^{1*}, Vinod G², Shrivalli BS¹, Vishal Ashok¹

¹Dept. of Cytogenetics, Neuberger Anand Reference Laboratory, Bangalore, Karnataka, India

²Dept. of Pediatric Hematology Oncology, Kauvery Hospital, Temur, Tamil Nadu, India



ARTICLE INFO

Article history:

Received 20-07-2023

Accepted 16-09-2023

Available online 05-12-2023

Keywords:

Acute lymphoblastic leukemia

Aneuploidy

Trisomy 5

ABSTRACT

Acute lymphoblastic leukemia (ALL) is the most common malignancy in childhood and represents about 75 -80% of ALL in pediatric age group. ALL is characterised by uncontrolled proliferation of abnormal, immature lymphocytes and their progenitors and replacing the bone marrow elements and other lymphoid organs by leukemic cells (ALL blasts). The 5 year survival rate for childhood ALL is about 90% overall, children in lower risk groups have a better prognosis than those in higher risk group. Risk assessment is mainly based on cytogenetic and molecular factors in addition, clinical symptoms and signs, White blood cell count at diagnosis are all recognized for stratification. In present case the cytogenetic analysis showed the presence of trisomy 5 as a sole numerical abnormality. Trisomy 5 accounts for aneuploidy change in the cytogenetic analysis. The gain or loss of whole chromosome, ie aneuploidy is a major genomic insult in human cancers. Aneuploidy is observed in ~90% of solid tumors and ~60% of hematological malignancies. The increased gene expression in trisomy 5 causes chromosomal instability (CIN), microsatellite instability (MIN) and genomic instability which inturn causes the cancer genome to undergo evolution, adaptation and favors tumor progression in patients with B cell acute lymphoblastic leukemia.

This is an Open Access (OA) journal, and articles are distributed under the terms of the [Creative Commons Attribution-NonCommercial-ShareAlike 4.0 License](https://creativecommons.org/licenses/by-nc-sa/4.0/), which allows others to remix, tweak, and build upon the work non-commercially, as long as appropriate credit is given and the new creations are licensed under the identical terms.

For reprints contact: reprint@ipinnovative.com

1. Introduction

Acute lymphoblastic leukemia (ALL) is the most common malignancy in childhood and represents about 75 -80% of ALL in pediatric age group. The incidence of childhood ALL is around 3-4 cases per 100,000 leukemia. The peak incidence is between 2-5 years of age.¹ ALL is characterised by uncontrolled proliferation of abnormal, immature lymphocytes and their progenitors and replacing the bone marrow elements and other lymphoid organs by leukemic cells (ALL blasts).²

The 5 year survival rate for childhood ALL is about 90% overall, children in lower risk groups have a better prognosis than those in higher risk group.³ Risk assessment

is mainly based on cytogenetic and molecular factors in addition, clinical symptoms and signs, White blood cell count at diagnosis are all recognized for stratification.⁴ Early medullary response to induction therapy is determined by the level of minimal residual disease (MRD) at the end of induction therapy.⁵

ALL is characterised by the presence of recurrent chromosomal abnormalities and cytogenetic studies are essential for diagnosis and prognosis. High hyperdiploidy (>50 chromosomes) and ETV6-RUNX1 occur in 25-30% of Childhood ALL and are associated with favorable outcome. Hypodiploidy (< 44), BCR-ABL1 and KMT2A rearrangements account for 2-5% and are associated with high risk group in childhood ALL.⁶ The chromosomal gain or loss are generally accompanied by additional cytogenetic aberrations that reflects the disease progression in ALL.⁷

* Corresponding author.

E-mail address: drnidhir@neubergeranand.com (Nidhi R).

In this case we report a rare childhood ALL case having numerical abnormality of chromosome 5 (trisomy 5) as a sole cytogenetic abnormality.

2. Case Report

8yr old boy presented to pediatric OPD with a history of fever, leg pain, and skin rashes for the past 2 days. On examination palor, skin ecchymosis and petechial rashes, generalized lymphadenopathy, and hepatosplenomegaly were noted. Blood investigations revealed low hemoglobin, thrombocytopenia and high White blood cell (WBC) counts.

The bone marrow aspiration showed cellular smears with no megakaryocytes seen. Lymphoblasts with a high N:C ratio, oval to irregular nuclei, open chromatin, and scant cytoplasm account for 55% of total cells. Normal marrow elements are suppressed.

The immunophenotyping showed a population of blasts expressing CD19, CD10, CD34 (Heterogenous), CD123(Moderate to Dim), CD38, CD58, CD73, CD24 (Heterogenous), HLADR, CD22, CD66c and cytoplasmic CD79a. Other markers of T cell and myeloid differentiation were negative. Antibody to TSLP receptor (CRLF2) was Negative. DNA ploidy analysis by flow cytometry using FxCycle Violet staining showed features of diploidy.

2.1. Cytogenetics

2.2. Banding

Bone marrow aspirates were incubated in RPMI medium overnight at 37°C in 5% CO₂, the cell cycle was arrested by treating with Colcemid. The cells were harvested using hypotonic solution and fixed with carnoy's fixative [methanol: acetic acid::3:1]. Chromosomes were banded using trypsin Giemsa staining and analyzed as per ISCN 2020 guidelines. G banding analysis of BMA revealed a numerical abnormality of chromosome 5, trisomy 5(47,XY,+5) in 20 metaphases and with normal clones(46,XY) in 10 metaphases.

2.3. Fluorescence in situ hybridization analysis (FISH)

Fluorescence in situ Hybridization analysis was performed on interphase cells and metaphases using XL 5q31/5q33/5p15 deletion probe which consists of an aqua-labelled probe hybridizing to a region at 5p15.2-15.3, an orange-labelled probe hybridizing to the EGR1 gene region at 5q31.2 and a green-labelled probe hybridizing to the RPS14 gene region at 5q32-33.1. Cytogenetic preparation of BMA slides, denaturing of probe/chromosomes, hybridization, and washing of slides were done as per manufacturer guidelines.

FISH results were analyzed using a Zeiss microscope equipped with DAPI, Fluorescence Isocyanate (FITC), and Tetramethylrhodamine B Isocyanate (TRITC) fluorescence

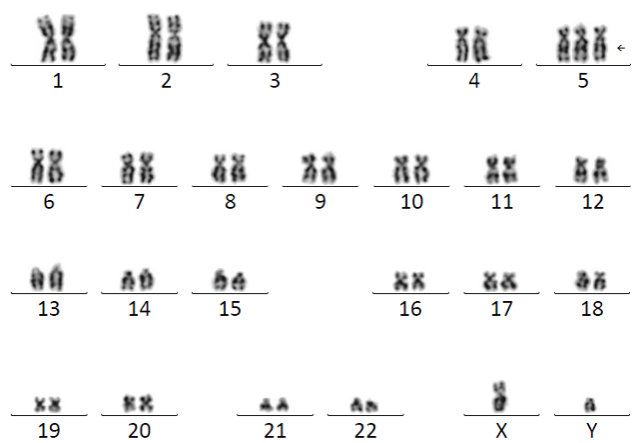


Figure 1: Karyotype: 47,XY,+5(20)/46,XY(10)

filters. Metaphase and interphase FISH analysis showed 3 copies of 5p15.2-15.3(Blue), EGR1 gene at 5q31.2 (Red), and a RPS14 gene at 5q32-33.1(Green), confirming the diagnosis of trisomy 5.

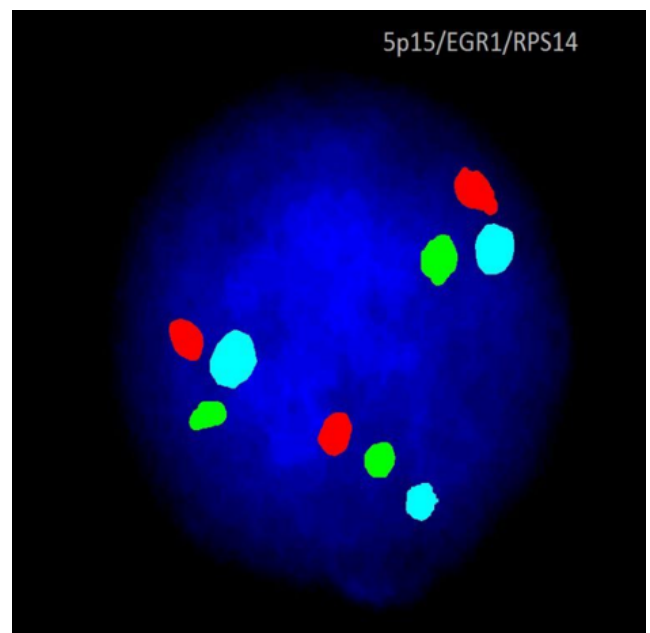


Figure 2: Fluorescence in situ Hybridization: showed 3 copies of 5p15.2-15.3 (Blue), EGR1 gene (Red) and a RPS14 gene (Green) confirming trisomy 5.

3. Discussion

Childhood ALL cases mainly presents with fever, leg pain, ecchymosis, petechial rashes and hepatosplenomegaly.⁸ The fever is indicative of infections which can occur because of shortage of normal white blood cells (WBC's). Patients having leukemia often have high WBC's but most

of these are leukemia cells and they don't protect against infection and there aren't enough normal white blood cells. The thrombocytopenia causes ecchymosis and petechial rashes. The leg pain is caused by build up of leukemia cells near the surface of the bone or inside the joint.⁸

Diagnosis of ALL is established by the presence of >20% lymphoblasts in the bone marrow and Immunophenotyping showed positive for B cell ALL CD markers.

Cytogenetic analysis is an essential tool for diagnosis, prognostification and to assess risk stratification in patients with ALL. The karyotype showed trisomy 5 as an sole numerical abnormality. Trisomy 5 accounts for aneuploidy change in the cytogenetic analysis. The gain or loss of whole chromosome, ie aneuploidy is a major genomic insult in human cancers. Aneuploidy is observed in ~90% of solid tumors and ~60% of hematological malignancies.⁹ Aneuploidy is often associated with activation of degradation pathways and cytoplasmic protein aggregates with impairment in protein folding, DNA repair, transcription, RNA processing, alteration in autophagosomes and thereby causing genomic instability. The increased gene expression in trisomy 5 causes chromosomal instability (CIN), microsatellite instability (MIN) and genomic instability which inturn causes the cancer genome to undergo evolution, adaptation and favors tumor progression in patients with B cell acute lymphoblastic leukemia.¹⁰

4. Conclusion

Acute lymphoblastic leukemia is the most common form of leukemia in children. The cytogenetic analysis plays a major role in diagnosis, prognosis and risk stratification by identifying recurrent and as well as random chromosomal abnormalities in ALL. Trisomy 5 is a rare cytogenetic abnormality in ALL. The increased gene expression in trisomy 5 causes chromosomal instability (CIN), microsatellite instability (MIN) and genome instability in lymphoblasts. The prognosis of ALL with trisomy 5 still remains unknown due to its rarity and it requires more studies for establishing the risk stratification.

5. Conflicts of Interest

None.

6. Source of Funding

None.

References

1. Bathia S, Robinson L. Nathan and Oski's Hematology of Infancy and childhood. 6th edn. In: Nathan D, Orkin S, Ginsburg D, Look A, editors. Epidemiology of leukemia in childhood. Saunders: Philadelphia; 2003. p. 1081.
2. Puckett Y, Chan O. Acute Lymphocytic Leukemia. and others, editor. Treasure Island (FL): StatPearls Publishing; 2023.
3. American Cancer Society. Cancer Facts & Figures. Atlanta, Ga: American Cancer Society; 2018. Available from: <https://www.cancer.org/research/cancer-facts-statistics/all-cancer-facts-figures/cancer-facts-figures-2018.html>.
4. Smith M, Arthur D, Camitta B, Carroll AJ, Crist W, Gaynon P, et al. Uniform approach to risk classification and treatment assignment for children with acute lymphoblastic leukemia. *J Clin Oncol*. 1996;14(1):18–24.
5. Borowitz MJ, Devidas M, Hunger SP, Bowman WP, Carroll AJ, Carroll WL, et al. Clinical significance of minimal residual disease in childhood acute lymphoblastic leukemia and its relationship to other prognostic factors: a Children's Oncology Group Study. *Blood*. 2008;111(12):5477–85.
6. Hunger SP, Mullighan CG. Redefining ALL classification: toward detecting high-risk ALL and implementing precision medicine. *Blood*. 2015;125(26):3977–87.
7. Greenberg PL, Tuechler H, Schanz J, Sanz G, Garcia-Manero G, Solé F, et al. Revised international prognostic scoring system for myelodysplastic syndromes. *Blood*. 2012;120(12):2454–65.
8. Rabin KR, Gramatges MM, Margolin JF, Poplack DG. Principles and Practice of Pediatric Oncology. 7th edn. In: Pizzo P, Poplack D, editors. Acute Lymphoblastic Leukemia. Philadelphia Pa: Lippincott Williams & Wilkins; 2016.
9. Duijf PH. Cancer cells preferentially lose small chromosomes. *Int J Cancer*. 2013;132(10):2316–26.
10. Stingle S, Stoehr G, Peplowska K, Cox J, Mann M, Storchova Z, et al. Global analysis of genome, transcriptome and proteome reveals the response to aneuploidy in human cells. *Mol Syst Biol*. 2012;8:608. doi:10.1038/msb.2012.40.

Author biography

Nidhi R, HOD

Vinod G, Senior Consultant

Shrivalli BS, Technical

Vishal Ashok, Technical

Cite this article: Nidhi R, Vinod G, Shrivalli BS, Ashok V. Case report: Pediatric acute lymphoblastic leukemia with trisomy 5 as sole cytogenetic abnormality. *IP J Diagn Pathol Oncol* 2023;8(4):234-236.