

Content available at: <https://www.ipinnovative.com/open-access-journals>

IP Journal of Diagnostic Pathology and Oncology

Journal homepage: <https://www.jdpo.org/>

## Original Research Article

## Prevalence of odontogenic tumors: A retrospective study of an institute of Rajasthan

Garima Mehra<sup>1</sup>, Madhvi Sanwelka<sup>1,\*</sup>, Manju Mehra<sup>1</sup><sup>1</sup>Dept. of Oral pathology, National Institute of Medical Sciences & Research, Jaipur, Rajasthan, India

## ARTICLE INFO

## Article history:

Received 20-05-2023

Accepted 14-08-2023

Available online 28-08-20

## Keywords:

Odontogenic tumor

Mandible

Maxilla

Ameloblastoma

## ABSTRACT

**Introduction:** Odontogenic tumors are a heterogeneous group of lesions with variable clinical and pathohistological features. The purpose of this study was to investigate the epidemiological behavior of this heterogeneous group of tumors across a 2 year period and to compare these data with those in the literature.

**Materials and Methods:** A retrospective study was made of cases of odontogenic tumors recorded at our institution between January 2021 to December 2022. The variables gender, age, anatomical site, histological type and symptoms were analyzed in 30 histopathology reports.

**Result:** Out of 30 cases, males show predominant cases 60% (18/30 cases) and females show 40% cases (12/30 cases). Male: female ratio is 1.5:1. According to age, the most involved age group was found to be of 11-20 years which showed highest number of cases (36.7%). Out of 30 cases, most frequent odontogenic tumor was found to be ameloblastoma (46.7%).

**Conclusion:** There is a slight predominance of odontogenic tumors in men and during the first decades of life; most of them occur in the mandible. There were statistically significant differences among the variables histological type and symptoms.

This is an Open Access (OA) journal, and articles are distributed under the terms of the [Creative Commons Attribution-NonCommercial-ShareAlike 4.0 License](https://creativecommons.org/licenses/by-nc-sa/4.0/), which allows others to remix, tweak, and build upon the work non-commercially, as long as appropriate credit is given and the new creations are licensed under the identical terms.

For reprints contact: [reprint@ipinnovative.com](mailto:reprint@ipinnovative.com)

## 1. Introduction

Odontogenic tumors are a heterogeneous group of lesions with variable clinical and pathohistological features. The biological behavior of these tumors includes hamartomatous proliferation, non-aggressive benign tumors, and aggressive and malignant tumors.<sup>1</sup> There has been considerable interest in odontogenic tumors by oral pathologists, who have studied and categorized these tumors for decades. These tumors are 2.5% of all biopsied lesions in oral pathology.<sup>2,3</sup> Although many retrospective studies have been conducted all over the world but unanswered question still remain about the relative frequency and the incidence of certain odontogenic tumors.<sup>4</sup> The geographical

distribution of these lesions is variable. 2 Many studies in different part of the world have shown differences in the relative prevalence of these tumors.<sup>5</sup> Various attempts at classification of these tumors have been published to define diagnostic criteria, given the diversity of lesions that may arise from odontogenic tissues.<sup>1</sup> The first classification of these tumors was published in 1971, based on a 5-year joint effort coordinated by the World Health Organization (WHO).<sup>5</sup> An updated edition of this classification was published in 1992.<sup>6</sup> A new classification was proposed in 2005, which included the odontogenic keratocyst as a benign odontogenic tumor.<sup>7</sup> The purpose of this study was to investigate the epidemiological behavior of this heterogeneous group of tumors across a 2 year period and to compare these data with those in the literature.

\* Corresponding author.

E-mail address: [madhvisanwalka00@gmail.com](mailto:madhvisanwalka00@gmail.com) (M. Sanwelka).

## 2. Materials and Methods

A retrospective study was made of cases of odontogenic tumors recorded at our institution between January 2021 to December 2022. All cases of all gender and age were included in this study. All cases who were diagnosed with odontogenic tumor were also included in this study. Data was analysed for gender, age, anatomical site and histological type in 30 histopathology reports. Bone related lesions were excluded from this study.

In case of recurrent tumors, where diagnosis were different in two slides, histological appearance of both were assessed and one common diagnosis was made and considered as single case. The diagnoses were reassessed and adapted to the 2005 WHO classification.<sup>7</sup> After the sample was obtained, a database was generated using the SPSS (v. 13.0) statistics software and statistical data was analysed. This study was granted permission by the Research Ethics Committee of our institution.

## 3. Result

Out of 30 cases, males show predominant cases 60% (18/30 cases) and females show 40% cases (12/30 cases). Male: female ratio is 1.5:1. (Table 1)

According to age, the most involved age group was found to be of 11-20 years which showed highest number of cases (36.7%), followed by 21-30 years (20%), 0-10 years (16.7%), 51-60 years (10%). Equal number of cases were found in age group of 31-40 years and 41-50 years (6.6%) and least was found to be in 61-70 years (3.3%). No cases were found after age of 70 years. (Table 2). Out of 30 cases maximum cases were found to be involving mandible (60%) and 40% involving maxilla (Table 3).

Out of 30 cases, most frequent odontogenic tumor was found to be ameloblastoma (46.7%) followed by Keratocystic odontogenic tumor (20%), Odontoma (13%), Calcifying epithelial odontogenic tumor (10.4%), Adenomatoid odontogenic tumor (6.7%) and least was found to be Myxoma (3%) as seen in Figure 1.

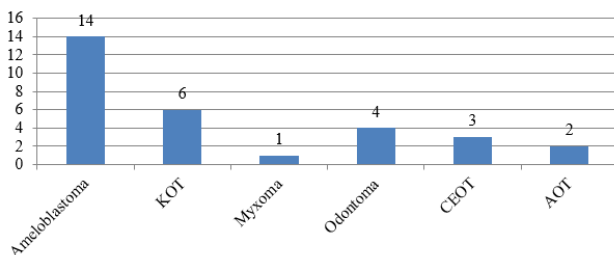


Fig. 1: Distribution of lesions

## 4. Discussion

Literature showed numerous reports on incidence of odontogenic tumors from different parts of world. After studying these papers some conclusions were made which are

1. Benign tumors are more common than malignant tumors.
2. Ameloblastoma, odontoma, CCOT, KCOT myxoma are common tumors among them.
3. Calcifying epithelial odontogenic tumor is relatively uncommon but higher incidence is found in Iranian and South Indian population.

The incidence of odontogenic tumor was slightly higher in males (Table 1) this finding has not been demonstrated study done by Mosqueda-Taylor et al.<sup>8</sup> But studied done by Ahlfors et al,<sup>9</sup> Mullapudi et al,<sup>10</sup> Verkhede et al,<sup>11</sup> Gill S et al,<sup>12</sup> Luo HY et al,<sup>13</sup> De costa et al,<sup>14</sup> Tawfik MA et al<sup>15</sup> and Johnson NR et al<sup>16</sup> showed male predominance.

The ameloblastoma was the most common tumor in this study (46.7%) (Table 2); its frequency is similar to other studies done by Oduyoka et al<sup>17</sup> (58%), Lu et al.<sup>18</sup> (59%), Mullapudi et al,<sup>10</sup> Verkhede et al,<sup>11</sup> Gill S et al,<sup>12</sup> Tawfik MA et al<sup>15</sup> and Adebayo et al.<sup>19</sup> (48%). In our study, the frequency of ameloblastoma was higher in males (57.2%) (Table 1), as also seen in studies conducted in Nigeria<sup>19</sup> and Turkey;<sup>20</sup> Studies done in Africa showed that the prevalence of this tumor is higher in the second to fifth decades of life,<sup>19,21</sup> and that they are located preferably in the mandible,<sup>18,21</sup> both of which were seen in our study also (Tables 2 and 3).

As of 2005, a new classification included the odontogenic keratocyst as one of the odontogenic tumors, renaming it as a keratocystic odontogenic tumor. The reasons includes its clinical behavior, having high recurrence rate after simple enucleation, the histological appearance, and the presence of tumor markers like proliferating cell nuclear antigen (PCNA), Ki67, BCE2, matrix metalloproteinase (MMP) 2 and 9, and p53.<sup>22</sup> This was found to be the second most prevalent lesion in this study (20%) (Table 2). However study done by Pandiar D et al<sup>23</sup> had highest prevalence of KOT in their study, and also found that it is affecting mandible and vast majority affected posterior region including ramus and angle of mandible.

Reichert et al stated in his study that the average age of initial diagnosis in industrialized countries is 39.1 years compared with 27.7 years from developing countries and hypothesized that ameloblastoma develops 10 to 15 years earlier in developing countries than in industrialized countries.<sup>24</sup> Dodge proposed that this variation among

**Table 1:** Distribution of patients according to gender.

Histological type	Male	Percentage	Female	Percentage	Total
Ameloblastoma	8	57.2	6	42.8	14
Keratocystic odontogenic tumor (KOT)	4	66.7	2	33.3	6
Myxoma	1	100	0	0	1
Odontoma	2	50	2	50	4
Calcifying epithelial odontogenic Tumor (CEOT)	2	66.7	1	33.3	3
Adenomatoid odontogenic tumor (AOT)	1	50	1	50	2
Total	18		12		30

**Table 2:** Distribution of patients according to Age of patients with odontogenic tumors.

Histological type	Age (in years)								Total	%
	0-10	11-20	21-30	31-40	41-50	51-60	61-70	71-80		
Ameloblastoma	1	3	5	1	1	2	1	0	14	46.7
Keratocystic odontogenic tumor	4	0	0	1	0	1	0	0	6	20
Myxoma	0	1	0	0	0	0	0	0	1	3.3
Odontoma	0	3	1	0	0	0	0	0	4	13.3
Calcifying epithelial odontogenic Tumor	0	2	0	0	1	0	0	0	3	10
Adenomatoid odontogenic tumor	0	2	0	0	0	0	0	0	2	6.7
Total	5	11	6	2	2	3	1	0	30	100

**Table 3:** Anatomical sites of odontogenic tumors.

Histological type	Anatomical site				Total
	Mandible		Maxilla		
	Number of cases	%	Number of cases	%	
Ameloblastoma	10	71.5	4	28.5	14
Keratocystic odontogenic tumor	4	66.7	2	33.3	6
Myxoma	0	0	1	100	1
Odontoma	1	25	3	75	4
Calcifying epithelial odontogenic Tumor	2	66.7	1	33.3	3
Adenomatoid odontogenic tumor	1	50	1	50	2
Total	18		12		30

countries may be due to the poor nutrition and healthcare in developin contries which leads to accelerated aging process.<sup>25</sup>

Odontoma is considered to be a tumor-like malformation (hamartoma) rather than a true odontogenic neoplasm of dental tissue and this tumor accounts for the fourth most common tumor. This was the most common of these tumors in the Americas, as reported by Ochsenius et al.<sup>26</sup> Mosqueda- Taylor et al.<sup>3</sup> and Daley et al.<sup>27</sup> Odontomas are least frequent in Africans<sup>6</sup> and Chinese.<sup>18</sup> There were 4 cases of odontomas in our study (50%) (Table 1). The lower incidence of odontomas in Africans is probably due to the lack of symptoms in many of these lesions or by their genetic factors.<sup>6</sup> This neoplasm was diagnosed mostly in patients aged below 30 years. Some published papers have also reported that new odontomas are discovered

up to the third decade of life.<sup>8,14</sup> Odontomas were more prevalent in the maxilla (75%) (Table 3) and has similar incidence in both males and females (Table 1); this is similar with findings of Ladeinde et al<sup>5</sup> who also reported no sex predilection in their study but different to the findings of Santos et al.<sup>28</sup> which showed higher incidence in females. This relative less number of cases of odontoma in our study is may be due to the fact that odontoma are usually asymptomatic and the patients do not seek medical assistance everytime. Furthermore, some cases may go to ENT specialists and thus all the excised specimen are not submitted for histopathological examination.

The incidence of the adenomatoid odontogenic tumor was 6.7% of all odontogenic tumors in our study (Table 2). Some papers have reported that this tumor is more frequently found in the maxilla<sup>21,28</sup> and in female

patients.<sup>21</sup>(Table 1); these findings were different in our study in our study, in which 50% of these lesions were found in the maxilla and 50% in mandible (Table 3) and equally present in both males and female (Table 1), all in the second decade of life (2 cases) (Table 2).

The calcifying epithelial odontogenic tumor was seen in 3 cases (10.7%) (Table 2); there was a slightly higher incidence in males (66.7%) (Table 1), and 66.7% of these cases were in the mandible (Table 3). These findings are similar to those in most studies<sup>28</sup>except for Hiroyuki et al<sup>21</sup> report. This neoplasm is usually found accidentally in routine exams.<sup>19</sup>

It is essential to define the epidemiology of these tumors to improve our knowledge about their behavior, which allows us to optimize the diagnosis and therapy.

Limitation of this study is that it is a one institute study with limited number of cases in this region, more such study should be done with multi institute study to know incidence of odontogenic tumors in more details.

## 5. Conclusion

There is a slight predominance of odontogenic tumors in men and during the first decades of life; most of them occur in the mandible. Statistically significant differences among the variables histological type and symptoms were found. In India, specifically in this study, which was done in a region where population miscegenation is significant, there were some differences compared to published studies undertaken in other parts of the world.

## 6. Conflict of Interest

None as stated by authors.

## 7. Source of Funding

None as stated by authors.

## References

- Buchner A, Merrell PW, Carpenter WM. Relative frequency of central odontogenic tumors: a study of 1,088 cases from Northern California and comparison to studies from other parts of the world. *J Oral Maxillofac Surg.* 2006;64(9):1343–52.
- Antunes AA, Silva JL, Silva PV, Antunes AP. Tumores odontogênicos: Análise de 128 casos. *Rev Bras Cir Cabeça Pescoço.* 2006;35(3):160–3.
- Mosqueda-Taylor A, Ledesma-Montes C, Caballero-Sandoval S, Portilla-Robertson J, Rivera LRG, Meneses-García A, et al. Odontogenic tumors in Mexico: a collaborative retrospective study of 349 cases. *Oral Surg Oral Med Oral Pathol Oral Radiol Endod.* 1997;84(6):672–5. doi:10.1016/s1079-2104(97)90371-1.
- Simon ENM, Merx MAW, Vuhahula E, Ngassapa D, Stoelinga PJW. A 4-year prospective study on epidemiology and clinicopathological presentation of odontogenic tumors in Tanzania. *Oral Surg Oral Med Oral Pathol Oral Radiol Endod.* 2005;99(5):598–602.
- Ladeinde AL, Ajayi OF, Ogunlewe MO, Adeyemo WL, Arotiba GT, Bamgbose BO, et al. Odontogenic tumors: a review of 319 cases in a Nigerian teaching hospital. *Oral Surg Oral Med Oral Pathol Oral Radiol Endod.* 2005;99(2):191–5.
- Kramer IRH, Pindborg JJ, Shear M. WHO histological typing of odontogenic tumours. 2nd Edn. Geneva: Springer-Verlag; 1992.
- Barnes L, Everson J, Reichart P. World Health Organization Classification of Tumours: Pathology and Genetics of Tumours of the Head and Neck. Lyon, France: International Agency for Research on Cancer; 2005.
- Mosqueda-Taylor A, Irigoyen-Camacho ME, Diaz-Franco MA, Torres-Tejero MA. Odontogenic cysts. Analysis of 856 cases. *Med Oral.* 2002;7(2):89–96.
- Ahlfors E, Larsson A, Sjögren S. The Odontogenic keratocyst: A benign cystic tumor. *J Oral Maxillofac Surg.* 1984;42(1):10–9.
- Mullapudi SV, Putcha UK, Boindala S. Odontogenic tumors and giant cell lesions of jaws: a nine year study. *World J Surg Oncol.* 2011;9:68.
- Varkhede A, Tupkari JV, Sardar M. Odontogenic tumors: a study of 120 cases in an Indian teaching hospital. *Med Oral Patol Oral Cir Bucal.* 2011;16(7):895–9.
- Gill S, Chawda J, D J. Odontogenic tumors in Western India(Gujarat): Analysis of 209 cases. *J Clin Exp Dent.* 2011;3(2):78–83.
- Luo HY, Li TJ. Odontogenic tumors: a study of 1309 cases in a Chinese population. *Oral Oncol.* 2009;45(8):706–11.
- da Costa D, Maurício AS, de Faria PAS, da Silva LE, Mosqueda-Taylor A, Lourenço SQC, et al. Odontogenic tumors: a retrospective study of four Brazilian diagnostic pathology centers. *Med Oral Patol Oral Cir Bucal.* 2012;17(3):389–94.
- Tawfik MA, Zyada MM. Odontogenic tumors in Dakahlia, Egypt: analysis of 82 cases. *Oral Surg Oral Med Oral Pathol Oral Radiol Endod.* 2010;109(2):97–73.
- Johnson NR, Savage NW, Kazoullis S, Batstone MD. A prospective epidemiological study for odontogenic and non-odontogenic lesions of the maxilla and mandible in Queensland. *Oral Surg Oral Med Oral Pathol Oral Radiol.* 2013;115:515–22.
- Odukoya O. Odontogenic tumors: Analysis of 289 Nigerian cases. *J Oral Pathol Med.* 1995;24(10):454–7.
- Lu Y, Xuan M, Takata T, Wang C, He Z, Zhou Z, et al. 10.1016/s1079-2104(98)90208-6. *Oral Surg Oral Med Oral Pathol Oral Radiol Endod.* 1998;86(6):707–14.
- Adebayo ET, Ajike SO, Adekeye O. A review of 318 odontogenic tumors in Kaduna, Nigeria. *J Oral Maxillofac Surg.* 2005;63(6):811–9.
- Olgac V, Koseoglu BG, Aksakalli N. Odontogenic tumours in Istanbul: 527 cases. *Br J Oral Maxillofac Surg.* 2006;44(5):386–8.
- Hiroyuki O, Hirosugu Y, Tilakaratne WM. Odontogenic Tumors in Sri Lanka: Analysis of 226 Cases. *J Oral Maxillofac Surg.* 2007;65(5):875–82.
- Pogrel MA. The keratocystic odontogenic tumor. *Oral Maxillofac Surg Clin North Am.* 2013;25(1):21–30.
- Pandier D, Shameena PM, Sudha S, Varma S, Manjusha P, Banyal VS, et al. Odontogenic Tumors: A 13-year Retrospective Study of 395 Cases in a South Indian Teaching Institute of Kerala. *Oral Maxillofacial Pathol J.* 2015;6(2):602–8.
- Reichart PA, Philipsen HP, Sonner S. Ameloblastoma: biological profile of 3677 cases. *Eur J Cancer B Oral Oncol.* 1995;31(2):86–99.
- Dodge OG. Tumors of the jaw, odontogenic tissues and maxillary antrum (excluding burkitt lymphoma) in Uganda Africans. *Cancer.* 1965;18(2):205–15.
- Ochsenius G, Ortega A, Godoy L, Pëafiel C, Escobar E. Odontogenic tumors in Chile: A study of 362 cases. *J Oral Pathol Med.* 2002;31(7):415–20.
- Daley TD, Wysocki GP, Pringle GA. Relative incidence of odontogenic tumors and oral and jaw cysts in a Canadian population. *Oral Surg Oral Med Oral Pathol.* 1994;77(3):276–80.

28. Santos JN, Pinto LP, Figueiredo C, Souza LB. Odontogenic tumors- Analysis of 127 cases. *Pesqui Odontol Bras*. 2001;15(4):308–13.

**Manju Mehra**, Professor

### **Author biography**

**Garima Mehra**, Consultant

**Madhvi Sanwelka**, Assistant Professor

**Cite this article:** Mehra G, Sanwelka M, Mehra M. Prevalence of odontogenic tumors: A retrospective study of an institute of Rajasthan. *IP J Diagn Pathol Oncol* 2023;8(3):141-145.