

Content available at: <https://www.ipinnovative.com/open-access-journals>

IP Journal of Diagnostic Pathology and Oncology

Journal homepage: <https://www.jdpo.org/>

Original Research Article

Clinicopathological profile of triple negative breast cancer in a tertiary health care centre of India

Gulshan Patel¹, Saqib Ahmed^{2,*}, Ruhi Hasan³, Mahboob Hasan¹¹Dept. of Pathology, Jawaharlal Nehru Medical College, AMU, Aligarh, Uttar Pradesh, India²Dept. of Pathology, Shri Guru Ram Rai Institute of Medical and Health Sciences, Dehradun, Uttar Pradesh, India³Dept. of Microbiology, Government Doon medical College, Dehradun, Uttarakhand, India

ARTICLE INFO

Article history:

Received 13-07-2023

Accepted 02-08-2023

Available online 28-08-2023

Keywords:

Aggressive behaviour

Estrogen receptor

Her2Neu

Progesterone receptor

ABSTRACT

Introduction: Breast carcinoma is one of the most common malignancies affecting women in developing countries. It is divided into several subtypes, including triple negatives. TNBCs are found to have an aggressive behaviour and have a metastatic potential leading to an overall poorer prognosis.

Aims and Objective: The aim was to study the clinicopathological profile of TNBC patients including parameters like age, site, tumour size, histopathological type, histologic grade, lymphovascular invasion and nodal invasion and TNM Staging was done to study the overall prognosis.

Materials and Methods: A four year retrospective study was conducted on ninety seven cases of breast carcinoma which were further classified based on immunohistochemical staining into four subtypes. The clinicopathological details and the histomorphological features of these patients were studied.

Results: Of the 208 cases, 97 cases were diagnosed as TNBC. The average age at presentation was 45 years. Most of the cases showed Nottingham Modification of Scarff Bloom-Richardson (NMBR) grade 3 (66%) and stage II (50.7%). Lymph node metastasis and Lymphovascular invasion was seen in 62% and 24.7% of cases. Infiltrating ductal carcinoma (not otherwise specified) type (94.8%) was the most common histological type.

Conclusion: TNBC have an aggressive behaviour compared to other subtypes with higher SBR grade. Lymphovascular invasion and nodal metastasis.

This is an Open Access (OA) journal, and articles are distributed under the terms of the [Creative Commons Attribution-NonCommercial-ShareAlike 4.0 License](https://creativecommons.org/licenses/by-nc-sa/4.0/), which allows others to remix, tweak, and build upon the work non-commercially, as long as appropriate credit is given and the new creations are licensed under the identical terms.

For reprints contact: reprint@ipinnovative.com

1. Introduction

Breast cancer accounts for 11.6% cases of all malignancy with 2.1 million cases of newly diagnosed female breast cancer cases in the year 2018.¹ In India, Breast cancer is the most common cancer in women and accounts for 27% of all cancer in women.² Triple Negative Breast Carcinomas (TNBCs) are group of tumors that does not express the genes for Estrogen receptor (ER), Progesterone receptor (PR), and Human epidermal growth factor receptor 2 (HER2/neu), accounting for 15-20% of all breast

carcinomas.³ Prevalence of TNBC in India is considerably higher as compared to Western countries with a ratio of 1:3 having a triple-negative disease.⁴ TNBCs are highly aggressive subtype of breast cancer, majorities are in young aged patients, are of high grade with limited treatment options and very poor prognosis.⁵ Few of the risk factors associated with TNBC are prior history of breast cancer, Asian ancestry, and a BRCA1 or BRCA2 mutation.⁶ Thus, this study the clinicopathological features of triple negative breast carcinoma by histomorphological features of triple negative breast cancer; analysing various parameters such as the age, site, tumour size, clinical features and treatment outcomes in triple negative breast cancer; and by comparing

* Corresponding author.

E-mail address: saqibahmed.mail@gmail.com (S. Ahmed).

these clinicopathological features in luminal A, luminal B, Her2 positive and triple negative tumours.

2. Materials and Methods

This study was a four year retrospective study which was carried out on two hundred eight cases of breast carcinoma and was undertaken in the Department of Pathology. Complete clinical details including history, clinical examination, gross examination along with relevant investigations were recorded in each case. Related paraffin blocks were obtained from the record section and routine Haematoxylin and eosin (H & E) staining and immunohistochemical studies were done. The tumours were classified as Luminal A (HR +ve, HER2/neu-ve), Luminal B (HR +ve, HER2/neu +ve), Her 2 Positive (HR -ve, HER2/neu +ve) and Triple negative breast Cancer (HR -ve, HER2/neu-ve). Out of two hundred and eight cases, ninety seven cases were of triple negative cancer. The clinicopathological details and histomorphological features of TNBCs were reviewed. The morphological parameters analysed were tumour size, tumour site, histological type, histological grade, lymph node status and the stage (TNM staging) along with lymphovascular and nodal involvement. The study was approved by Institutional Ethics Committee.

2.1. Inclusion criteria

Specimen labeled as TNBC.

2.2. Exclusion criteria

Tissues not enough for immunostaining, prior chemotherapy or radiotherapy.

3. Observations and Results

In the present study, most of the cases were premenopausal women i.e. 59 (60.8%) and 38 (39.1%) cases were postmenopausal women. (Figure 1) Highest incidence of TNBC cases were observed in age group of 41-50 years (42%) followed by 23.7% cases in age group of 31-40 years. Least cases were distributed in the age group of 60 years and above. (Figure 2).

Majority of the cases occurred in the right breast (52%) while 48% occurred in the left breast.(Figure 3) Most common site involved in our study was upper outer quadrant, in 61/97 (70.1%) cases, followed by upper inner quadrant in 12 (12.4%) cases. (Table 1)

Most of the TNBC cases in our study have size of between 2 to 5 cm in diameter i.e. in 65/97 (67.0%) of TNBC cases followed by tumor size >5cm in 16/97 (19.3%) cases and only 5/97 (5.2%) cases had size ≤2cm. (Figure 4).

Out of 97 TNBC cases, 92 (94.8%) cases are diagnosed with invasive carcinoma (NST) and 3 (3.1%) case of carcinoma with medullary features and 2 (2.1%) case

of metaplastic carcinoma. (Table 2). Among 97 TNBC cases, 64(66.0%) cases were of grade 3, 30 (30.9%) cases were of grade 2 and rest 3(3.1%) cases were of grade 1. (Figure 5). Lympho-vascular invasion were found in 24.7%TNBC cases whereas, no evidence of tumor cells in lympho-vascular channel was found in 75.3% TNBC cases. Out of 97 TNBC cases, we received 71 cases along with lymph nodes. Among these 71 TNBC cases, 44 (62%) cases were found to be lymph node positive for tumor cells while rest 27 (38%) were negative for any lymph node involvement by tumor cells. (Table 3). Out of 44 lymph node(s) positive cases, 1-3 lymph nodes metastasis was seen in 30 (68.2%) cases,. 4 to 9 lymph nodes were involved in 11 (25.0%) cases and ≥10 lymph nodes were involved in 3 (6.8%) cases. Out of 71 TNBC lymph node positive TNBC cases, 36 (50.7%) were of stage II, followed by 33 (46.5%) cases were of stage III and rest 2 (2.8%) cases were of stage I. Out of 71 TNBC cases most cases are of stage IIB, 22 (31.0%) followed by equal number of stage IIA and stage IIIA i.e.16 (22.5%) then stage IIIB, 12 (16.9%) > stage IIIC, 3 (4.2%) > stage IA 2 (2.8%) and no cases are of stage IB.

Table 1: Showing distribution of TNBC cases according to the quadrant of the breast involved

Site	Number of cases
Upper Outer Quadrant	61 (70.1%)
Upper Inner Quadrant	12 (12.4%)
Lower Outer Quadrant	8(8.3%)
Lower Inner Quadrant	4(4.1%)
Central	5 (5.1%)
Total	97 (100%)

Table 2: Distribution of TNBC cases according to the histopathological type

Histomorphological Type	Number of cases
Invasive Ductal Carcinoma	92 (94.8%)
Metaplastic Carcinoma	2 (2.1%)
Carcinoma with Medullary like Features	3 (3.1%)
Total	97

Table 3: Showing distribution of TNBC cases according to the lympho-vascular invasion and lymph node involvement

Lymphovascular invasion	Number of cases
Present	24 (24.7%)
Absent	73 (75.3%)
Total	97
Lymph Node(s) Involvement	Number of cases
Present	44 (62%)
Absent	27 (38%)
Total	71

Table 4: Distribution of TNBC cases according to the stage

TNM stage		Total number of cases
I	IA	2 (2.8%)
	IB	0 (0%)
	Total	2 (2.8%)
II	IIA	16 (22.5%)
	IIB	22 (31.0%)
	Total	36 (50.7%)
III	IIIA	16 (22.5%)
	IIIB	12 (16.9%)
	IIC	3 (4.2%)
Total	33 (46.5%)	
Total	Total	97 (100%)

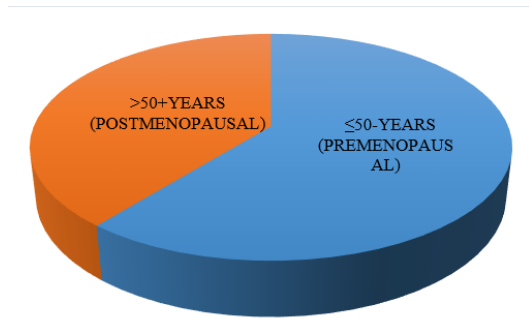


Fig. 1: Showing TNBC cases distribution according to menopausal status

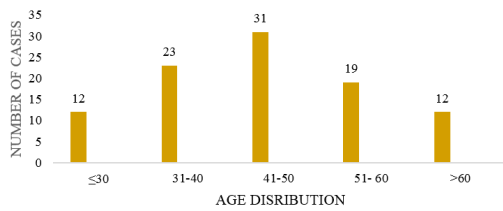


Fig. 2: Showing distribution of TNBC cases according to the age

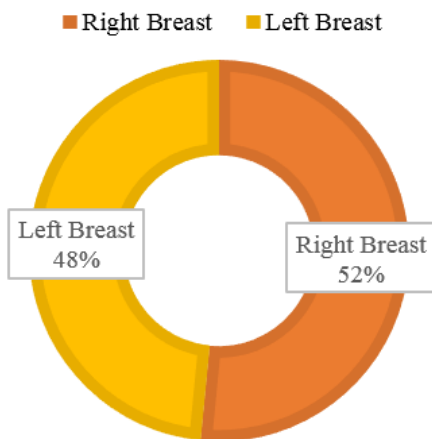


Fig. 3: Showing distribution of TNBC cases according to the laterality of the breast involved

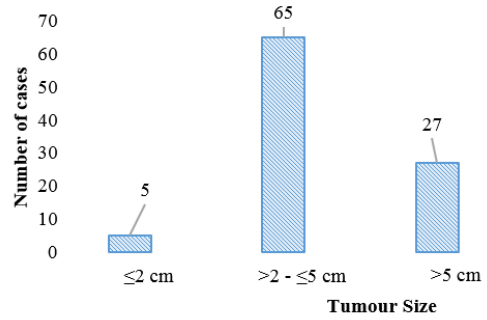


Fig. 4: Showing distribution of TNBC cases according to the tumor size.

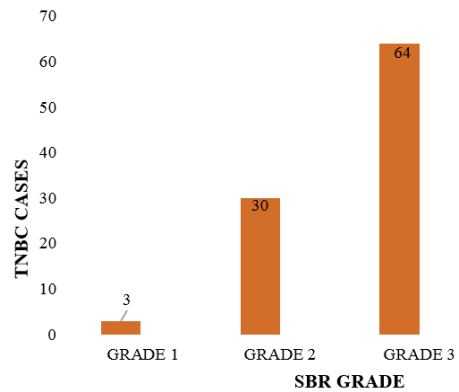


Fig. 5: Showing distribution of TNBC cases according to the SBR grade

4. Discussion

In this study, TNBC cases were found to be more common in premenopausal women 68.0%. Similar to a study in southern India with 72.6% of patients below 50 years of age.⁵ However, Liu Yin et al., found that 53.1% cases were in postmenopausal women⁷ median age of 45 years was a similar finding in similar studies by Lakshmaiah et al.⁵ Higher incidence of TNBC was seen in the right breast similar to studies by Suresh et al.,⁸ but Left sided TNBC cases were more in studies done by Lakshmaiah et al.,⁵ but no bilateral cases noted. This showed that the occurrence of bilateral TNBC is higher in Western females as compared to Indian females. Upper outer quadrant followed by upper inner quadrant is found to be a common site for occurrence of TNBCs.^{9,10} Most common tumor size in our study was found to be size of 2 to 5 cm (67.0%) similar to study by Nassima et al., with majority of patients having a tumor larger than 3 cm. Most common histopathological type of the TNBC in this study was invasive carcinoma (NST) i.e. (94.8%) similar findings were observed by Lakshmaiah et al.,⁵ Pareja et al.,²⁰¹⁶¹¹ with infiltrating ductal carcinoma (93.54%) as the most common type. TNBC of Grade 3 followed by 2 and 1 are the usual findings¹² but grade 2 is

found be more common in some studies.¹³ Triple Negative Breast Carcinoma is found to have an increased association with lympho-vascular invasion as compared to non TNBC cases.¹⁴ Similarly Lymph node involvement is found to be more common in TNBC as compared to non TNBC cases.⁵ However in a similar study by LiuYin et al., majority of cases were node-negative.⁷ Most of the TNBC cases are associated with 1-3 lymph node(s) (N1) involvement similar to our study.⁵ TNM stage II is the most common stage of the TNBC similar to study by Lakshmaiah et al.⁵ However, Agarwal et al., 2015 observed TNM stage III to be the most common stage in 47.5% of the TNBC cases.¹⁴

5. Conclusion

TNBC are common in premenopausal women with a median age of 45 years showing a greater involvement of right breast in the upper outer quadrant usually ranging between the size of >2 - ≤5 cm. TNBCs are usually associated with a higher grade and shows lymphovascular and nodal involvement and thus a overall poor prognosis. Infiltrating ductal carcinoma (not otherwise specified) type (94.8%) was the most common histomorphological type in TNBC cases.

6. Source of Funding

None.

7. Conflict of Interest

None.

References

1. Bray F, Ferlay J, Soerjomataram I, Siegel RL, Torre LA, Jemal A, et al. Global cancer statistics 2018: GLOBOCAN estimates of incidence and mortality worldwide for 36 cancers in 185 countries. *CA Cancer J Clin.* 2018;68(6):394–424.
2. The burden of cancers and their variations across the states of India: the Global Burden of Disease Study 1990-2016. *Lancet Oncol.* 2018;19(10):1289–306.
3. Chen JQ, Russo J. ERalpha-negative and triple negative breast cancer: molecular features and potential therapeutic approaches. *Biochim Biophys Acta.* 2009;1796(2):162–75. doi:10.1016/j.bbcan.2009.06.003.
4. Sandhu GS, Erqou S, Patterson H, Mathew A. Prevalence of Triple-Negative Breast Cancer in India: Systematic Review and Meta-Analysis. *J Glob Oncol.* 2016;2(6):412–21.
5. Lakshmaiah KC, Das U, Suresh TM, Lokanatha D, Babu GK, Jacob LJ, et al. A Study of Triple Negative Breast Cancer at a Tertiary Cancer Care Center in Southern India. *Ann Med Health Sci Res.* 2014;4(6):933–7.
6. Yeh J, Chun J, Schwartz S, Wang A, Kern E, Guth AA, et al. Clinical Characteristics in Patients with Triple Negative Breast Cancer. *Int J Breast Cancer.* 2017;p. 1796145. doi:10.1155/2017/1796145.
7. Yin L, Shuang H, Sheng C, Liang H, Sun XJ, Yang WT. The Prognostic Value of Nodal Staging in Triple-Negative Breast Cancer - A Cohort from China. *Sci Rep.* 2018;8(1):9007. doi:10.1038/s41598-018-23999-8.
8. Suresh P, Batra U, Doval DC. Epidemiological and clinical profile of triple negative breast cancer at a cancer hospital in North India. *Indian J Med Paediatr Oncol.* 2013;34(2):89–95.
9. Rummel S, Varner E, Shriver CD, Ellsworth RE. Evaluation of BRCA1 mutations in an unselected patient population with triple-negative breast cancer. *Breast Cancer Res Treat.* 2013;137(1):119–25. doi:10.1007/s10549-012-2348-2.
10. Nassima B, Jessie D, Jed D, Chloe D, Joel E, Virginie C, et al. Triple negative breast cancer: Early stages management and evolution, a two years' experience at the department of breast cancer of CHSF. *Clin J Obstet Gynecol.* 2020;3:65–78. doi:10.29328/journal.cjog.1001052.
11. Pareja F, Geyer F, Marchiò C. Triple-negative breast cancer: the importance of molecular and histologic subtyping, and recognition of low-grade variants. *Breast Cancer.* 2016;2:16036. doi:10.1038/npjbcancer.2016.36.
12. Rakha EA, El-Sayed ME, Green AR, Lee AH, Robertson JF, Ellis IO, et al. Prognostic markers in triple-negative breast cancer. *Cancer.* 2007;109(1):25–32.
13. Rao C, Shetty J, Prasad HL. Immunohistochemical profile and morphology in triple-negative breast cancers. *Journal of Clinical and Diagnostic Research.* 2013;7(7):1361–65.
14. Agarwal G, Nanda G, Lal P, Mishra A, Agarwal A, Agrawal V, et al. Outcomes of Triple-Negative Breast Cancers (TNBC) Compared with Non-TNBC: Does the Survival Vary for All Stages? *World J Surg.* 2016;40(6):1362–72.

Author biography

Gulshan Patel, Senior Resident

Saqib Ahmed, Assistant Professor  <https://orcid.org/0000-0002-7256-7175>

Ruhi Hasan, Junior Resident  <https://orcid.org/0000-0002-6130-971X>

Mahboob Hasan, Professor

Cite this article: Patel G, Ahmed S, Hasan R, Hasan M. Clinicopathological profile of triple negative breast cancer in a tertiary health care centre of India. *IP J Diagn Pathol Oncol* 2023;8(3):137-140.