

Content available at: <https://www.ipinnovative.com/open-access-journals>

IP Journal of Diagnostic Pathology and Oncology

Journal homepage: <https://www.jdpo.org/>

Case Report

Bilateral multifocal papillary renal cell carcinoma on autopsy: A case report

Ruchi Agarwal¹, Kulwant Singh¹, Monika Yadav^{2,*}, Yogesh Kumar³,
Bharat B Sidana¹

¹Dept. of Pathology, Bhagat Phool Singh Government Medical College for Women, Khanpur Kalan, Sonapat, Haryana, India

²Dept. of Pathology, Lady Hardinge Medical College, New Delhi, India

³Dept. of Forensic Medicine and Toxicology, Bhagat Phool Singh Government Medical College for Women, Khanpur Kalan, Sonapat, Haryana, India



ARTICLE INFO

Article history:

Received 13-02-2023

Accepted 30-03-2023

Available online 22-06-2023

Keywords:

Bilateral
Multifocal
Papillary
Renal

ABSTRACT

Renal cell carcinoma arises from the epithelium of the renal tubules and accounts for approximately 3% of adult malignancies. Tumours occur most often in older individuals usually in sixth and seventh decades of life. Bilateral multifocal papillary type of RCC is rare and its presence should prompt the suspicion of some underlying hereditary genetic predisposition thus thorough cytogenetic evaluation and detailed family history could help in finding the etiology. Bilateral RCC could be synchronous or metachronous. We hereby present the autopsy findings of a case of sudden death of a 65 years old male. On histopathological evaluation, both kidneys showed papillary variant of renal cell carcinoma as an incidental finding.

This is an Open Access (OA) journal, and articles are distributed under the terms of the [Creative Commons Attribution-NonCommercial-ShareAlike 4.0 License](https://creativecommons.org/licenses/by-nc-sa/4.0/), which allows others to remix, tweak, and build upon the work non-commercially, as long as appropriate credit is given and the new creations are licensed under the identical terms.

For reprints contact: reprint@ipinnovative.com

1. Introduction

The most common solid lesion of the kidney is renal cell carcinoma (RCC) which accounts for approximately 3% of all malignancies in adults.¹ Clinical suspicion of RCC is uncommon and only 10% of patients present with classical triad of hematuria, flank pain and flank mass.² Papillary renal cell carcinoma (PRCC) was first reported in 1976 by Mancilla-Jimenez and is a primary malignant tumour of the renal tubular epithelium.³

PRCC is a slow-growing neoplasm accounting for 5-15% of renal carcinoma and has a relatively favourable prognosis.⁴ The mean age of presentation of PRCC ranges from sixth to seventh decade with male predominance.² Major etiologic factors associated are lifestyle changes such as smoking, obesity and hypertension, first-degree relative with kidney cancer as well as familial cancer syndromes

mainly Von Hippel-Lindau syndrome.⁴

Bilateral RCCs are rare accounting for 3-5% in the epidemiology of the disease and greatly challenging for the surgeons to balance between oncological principles vis-à-vis exploiting renal function to circumvent renal replacement therapy.⁴ The main pathophysiology behind bilateral RCC is either as a consequence of spread from the primary RCC or a de novo process which remains still unclear regardless of whether the disease is metachronous. However, a contralateral tumour is considered to be a new primary RCC especially in absence of any evidence of distant disease.⁵

Clinical suspicion of bilateral renal cell carcinoma is extremely rare. Majority are incidentally detected on imaging studies performed for other purposes.⁴ Metastasis to adrenal glands is most commonly seen however PRCC can also metastasise to other organs such as lungs.⁶

Genetically, PRCC is typically associated with gain of chromosome 7 or 17 and loss of chromosome Y.⁷ Grossly,

* Corresponding author.

E-mail address: monikayadavpgims@gmail.com (M. Yadav).

it is usually well-circumscribed tumour with a fibrous pseudocapsule and cut surface is variable with areas of hemorrhage, necrosis, and cystic degeneration.⁷ PRCC is classified into two morphological subtypes mainly type I (PRCC1) having small-cell size with pale cytoplasm and type II (PRCC2) having large cell size with eosinophilic cytoplasm.⁷

Immunohistochemical stains will typically show positivity for CK7, CD10, AE1/ AE3, CAM5.2, EMA, vimentin, RCC antigen, AMACR, and 34bE12, and negativity for CA IX.1.⁷ Bilateral renal malignant tumours are still considered to be rare and very few cases are reported in literature.⁶ We hereby present a case of bilateral multifocal PRCC because of its rarity.

2. Case Report

The postmortem viscera of a 65 years old male with history of sudden death were received in the Department of Pathology, Bhagat Phool Singh Government Medical College for Women, Khanpur Kalan, Sonapat, Haryana. Organs including brain, heart, left kidney and piece of right kidney, pieces of both lungs, liver and spleen were received fixed in 10% formalin for histopathological examination. Post-mortem papers revealed no significant history of illness before death.

Left kidney weighed 126g and measured 12 x 4 x 2 cm whereas piece of right kidney weighed and measured 48 g and 9 x 5.5 x 1.5cm respectively. Grossly, the left kidney was enlarged in size with external surface showing a cyst at upper pole and multiple yellowish nodules on the surface. Cyst at the upper pole measures 5 x 4 cm filled with clear fluid with wall thickness measuring 0.1 cm. Cut surface showed multiple yellowish nodules in the cortex of variable size measuring from 2.5cm to 0.2 cm in diameter. Medulla of kidney was not involved by nodules. Piece of right kidney had grossly unremarkable external surface but cut section showed few yellowish nodules of variable size measuring 0.2 to 0.5cm in diameter (Figure 1).

Hematoxylin and eosin stained microsections from left kidney cyst show flattened lining epithelium along with fibrocollagenous tissue. Surrounding renal parenchyma show foci of interstitial chronic inflammatory infiltrate with focal tubular atrophy. Microsections from yellowish nodules revealed features of papillae lined by cuboidal cells having scant to moderate amount of eosinophilic cytoplasm with round nuclei showing mild pleomorphism and occasional mitotic figures per high power field along with numerous psammoma bodies (Figure 2a-d). Histological features were suggestive of papillary renal cell carcinoma. Von-Kossa stain was positive in psammoma bodies. Similarly, microsections from piece of right kidney showed foci of papillary renal cell carcinoma along with chronic interstitial inflammation and congestion. Other special stain like periodic acid schiff was negative. Immunohistochemical

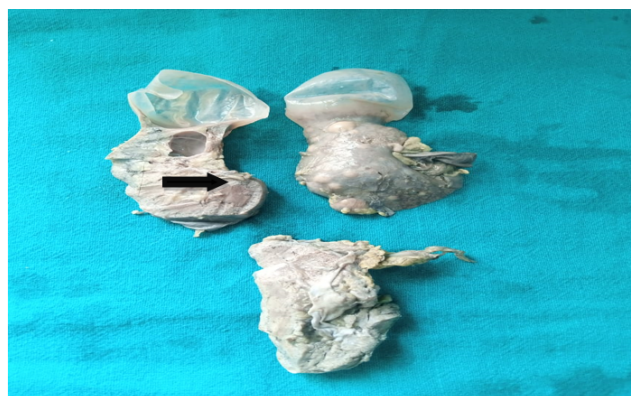

Fig. 1: Gross specimen of Left Kidney (black arrow) cut surface showing multiple yellowish nodules with a large cyst at upper pole. Piece of right kidney was grossly unremarkable.

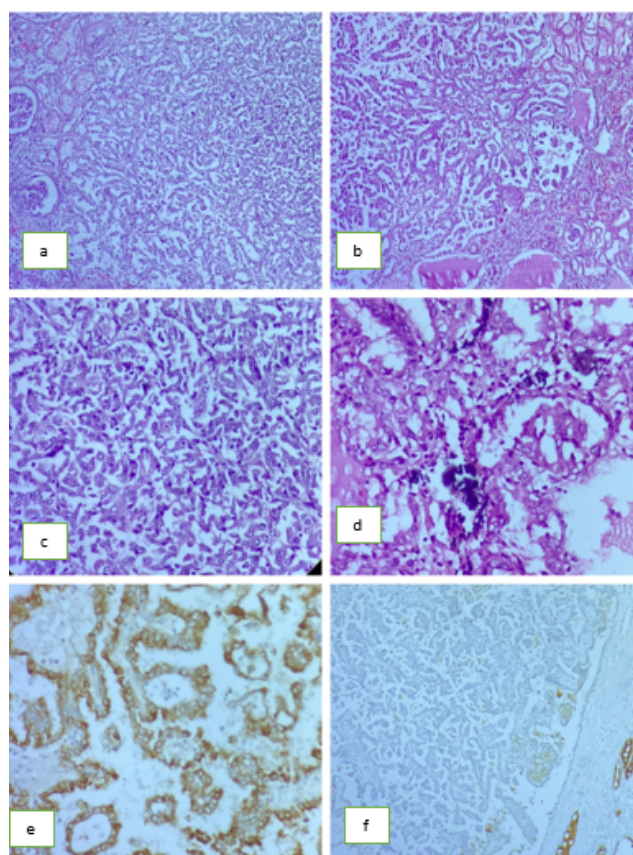


Fig. 2: a-b: Microphotograph examined show unencapsulated tumor area showing papillary architecture along with surrounding normal renal parenchyma (H&E 4X, 10X); c-d: Individual tumor cells show moderate amount of eosinophilic cytoplasm with round nuclei few showing prominent nucleoli along with many psammoma bodies (H&E 40X); e: On immunohistochemistry CK7 show cytoplasmic positivity (IHC, 40X); f: Immunohistochemical stain for CD10 is negative (IHC, 10X).

staining showed positivity for pan-CK and negativity for CD 10 and TTF-1 (Figure 2e,f).

Grossly remaining organs submitted were unremarkable. Microscopic examination from brain, lung, liver and spleen showed unremarkable histology whereas heart showed foci of areas of fibrosis thus suggestive of chronic ischemic heart disease along with fibrous cap atheroma in both right and left coronary arteries.

3. Discussion

PRCC is most common type of non-clear RCC in adults which arises from renal tubular epithelium.^{7,8} It has become second most common independent and clinicopathological type which accounts for 15 to 20% of renal cell carcinoma cases.³

The worldwide incidence in per lakh year is 4.7 and 2.5 in males and females respectively, resulting in around 210,000 new cases annually. The prevalence of non-hereditary sporadic multifocal RCC is estimated to be 6.8% in which the occurrence of bilateral multifocal tumours is found to be approximately 11.7%.⁹ Multifocality is defined as the presence of two or more tumours present in the same kidney, regardless of histology or timing of detection, in the absence of extra-renal metastatic disease in patients not known to have familial disease or hereditary syndromes.⁹

Two familial syndromes associated with increased risk of PRCC are hereditary papillary RCC (HPRCC) and hereditary leiomyomatosis RCC (HLRCC).² HPRCC is an autosomal dominant syndrome caused by mutation of the MET gene on chromosome 7q31 thus leading to increase in proliferative activity resulting invasion, aggressiveness and angiogenesis.² Targeted therapy with MET inhibitors in metastatic HPRCC such as foretinib and tivantinib is given.¹⁰ HLRCC syndrome is caused by an inactivating mutation of the fumarate hydratase (FH) gene which encodes the enzyme that converts fumarate to malate in the Krebs cycle and characterised by early age of onset, type 2 PRCC, cutaneous and uterine leiomyomas.²

Characteristically, PRCC is more encountered in chronic disease patients, especially evident in cases with a prolonged history of renal disease.¹¹ On radiographic evaluation, it appears cystic along with solid-appearing tumour at the periphery most of the central tumour cells are suspended in hemorrhagic fluid.² Grossly, it is most often bilateral, multifocal with soft and friable consistency due to abundant hemorrhage and necrosis with potential to metastasize to regional lymph nodes.² Abdominal CECT remains the most preferred imaging modality for evaluating their clinical staging and operability.⁴

Delahunt and Eble in 1997 first described type-1 and type-2 subtypes of PRCC based on their cytological features with a relatively dense packing of nuclei with scarce cytoplasm imposes PRCC1 and papillae with pseudolayering cells with abundant, eosinophilic cytoplasm,

round nuclei with irregular shape and prominent nucleoli in PRCC2.¹¹

In a study done by Pan et al on 102 patients of PRCC of which 42 cases were PRCC1 and 60 type II. The clinicopathological features and oncologic outcomes of the patients were evaluated in which univariate analysis showed that subtype, symptoms, TNM, stage grouping, WHO/ISUP grading and surgical methods have poor prognosis in the patients with PRCC2. However, multivariate analysis revealed that only stage grouping was the independent risk factor.³

Mikhaylenko described a young patient with 7 and 10 primary papillary renal cell carcinomas in the left and right kidneys, respectively. The patient did not have a family history of any of the known hereditary cancer syndromes. Tumors were resected and their molecular genetic analysis revealed the germline heterozygous missense variant in MET: c.3328G>A.¹⁰

In another study done on 267 patients by Gargouri et al found that PRCC was found in 12.7% of patients operated for renal tumors during the study period. The patients' mean age was 62.4 years with a male predominance. All tumors were unilateral with no clinical or radiological sign suggestive of this histological type. Treatment consisted of radical nephrectomy and nephron-sparing surgery in 74% and 26% of the cases, respectively. Histopathological examination of 267 cases of renal tumors revealed 20 cases with PRCC1 and 14 PRCC2. The 5-year overall and disease-free survival rates were 73.3% and 92% respectively.¹²

Histomorphological differential diagnosis of PRCC are clear cell RCC, clear cell papillary RCC, Xp11 translocation RCC and metastasis from other sites like thyroid and ovary, all these can be differentiated on immunohistochemistry.⁷

The limitation of our case study was relevant clinical details like family history, other investigations such as radiographic, cytogenetic analysis and previous treatment modality of patient could not be obtained.

4. Conclusion

Sporadic bilateral multifocal RCC is both clinically and technically challenging to diagnose and manage. Careful gross examination is essential in cases of multiple nodules in kidney and possibility of PRCC should be kept in all cases of multiple solid or cystic nodules. Despite the complex diagnostic and challenging surgical considerations, good functional and oncologic outcomes need to be achieved. Bilateral papillary renal cell carcinoma in autopsy is a rare case till date.

5. Conflict of Interest

There are no conflicts of interest in this article.

6. Source of Funding

None.

References


1. Ustuner M, Yaprak B, Teke K, Ciftci S, Kart M, Yildiz K, et al. Coexisting Papillary and Clear Renal Cell Carcinoma in the Same Kidney. *Case Rep Urol*. 2014;p. 575181. doi:10.1155/2014/575181.
2. Ofori EO, Alhassan BAB, Ayabilah EA, Maison POM, Asamani AA, Atawura H, et al. An unusual outcome of papillary renal cell carcinoma with lung metastases: a case report and review of literature. *African Journal of Urology*. 2021;27. doi:10.1186/s12301-020-00103-z.
3. Pan H, Ye L, Zhu Q, Yang Z, Hu M. The effect of the papillary renal cell carcinoma subtype on oncological outcomes. *Scientific Rep*. 2020;10:21073. doi:10.1038/s41598-020-78174-9.
4. Jategaonkar PA, Jategaonkar SP, Yadav SP, Mehra S. Bilateral Multi-Focal Sporadic Papillary Renal Cell Carcinoma: A Unique Surgical Challenge. *JCDR*. 2016;10:PL1–2. doi:10.7860/JCDR/2016/19179.8134.
5. Syed JS, Nguyen KA, Holford TR, Hofmann JN, Shuch B. Risk Factors for Metachronous Bilateral Renal Cell Carcinoma: A Surveillance, Epidemiology, and End Results Analysis. *Cancer*. 2019;125(2):232–8. doi:10.1002/cncr.31689.
6. Stigsson L, Ekelund L, Karp W. Bilateral Concurrent Renal Neoplasms: Report of Eleven Cases. *AJR*. 1979;132:37–42.
7. Zhao J, Eyzaguirre E. Clear Cell Papillary Renal Cell Carcinoma. *Arch Pathol Lab Med*. 2019;143(9):1154–8. doi:10.5858/arpa.2018-0121-RS.
8. Saleeb RM, Farag M, Ding Q, Downes M, Bjarnason G, Brimo F, et al. Integrated Molecular Analysis of Papillary Renal Cell Carcinoma and Precursor Lesions Unfolds Evolutionary Process from Kidney Progenitor-Like Cells. *Am J Pathol*. 2019;189(10):2046–60. doi:10.1016/j.ajpath.2019.07.002.
9. Sorbellini M, Bratslavsky G. Decreasing the indication for radical nephrectomy: a study of multifocal renal cell carcinoma. *Front Oncol*. 2012;2:84. doi:10.3389/fonc.2012.00084.
10. Mikhaylenko DS, Klimov AV, Matveev VB, Samoylova SI, Strelnikov VV, Zaletaev DV, et al. Case of Hereditary Papillary Renal Cell Carcinoma Type I in a Patient With a Germline MET Mutation in Russia. *Front Oncol*. 2020;9:1566. doi:10.3389/fonc.2019.01566.
11. Okoń K. Molecular Biology, Histopathological Diagnosis and Prognosis. *Pol J Pathol*. 2008;59(3):129–76.
12. Gargouri MM, Ayari Y, Chehida MB, Ouanes Y, Sellami A, Rhouma SB, et al. Clinical and pathological features of papillary renal cell carcinoma and prognostic value of its type-1 and type-2 subtypes. *Afr J Urol*. 2016;22(3):149–52.

Author biography

Ruchi Agarwal, Professor  <https://orcid.org/0000-0002-9004-4589>

Kulwant Singh, Professor  <https://orcid.org/0009-0006-4036-8530>

Yogesh Kumar, Associate Professor  <https://orcid.org/0009-0005-6235-4351>

Bharat B Sidana, Post Graduate Student  <https://orcid.org/0009-0003-3126-3997>

Cite this article: Agarwal R, Singh K, Yadav M, Kumar Y, Sidana BB. Bilateral multifocal papillary renal cell carcinoma on autopsy: A case report. *IP J Diagn Pathol Oncol* 2023;8(2):89-92.