

Content available at: <https://www.ipinnovative.com/open-access-journals>

IP Journal of Diagnostic Pathology and Oncology

Journal homepage: <https://www.jdpo.org/>

## Original Research Article

# Histopathological correlation in oral biopsies in clinically diagnosed pediatric oral lesions: A 12-year institutional archival study

Rakesh K Gupta<sup>1</sup>, Shugufta Shafi<sup>1,\*</sup>, Rubeena Anjum<sup>1</sup>, Mandeep Kaur<sup>1</sup>

<sup>1</sup>Dept. of Oral & Maxillofacial Pathology & Oral Microbiology, Indira Gandhi Govt. Dental College, Jammu, Jammu and Kashmir, India



## ARTICLE INFO

## Article history:

Received 07-04-2023

Accepted 09-06-2023

Available online 22-06-2023

## Keywords:

Cysts

Reactive lesions

Oral biopsies

Pediatric population

## ABSTRACT

**Aim:** The present study was aimed to determine the histopathological correlation in lesions of oral cavity in children aged 14 years and below received for diagnosis in the Oral Pathology Department of the Indira Gandhi Government Dental College Jammu, J&K.

**Materials and Methods:** The archives of the Department of Oral Pathology and Microbiology were retrospectively analyzed. Biopsy records of all oral lesions from pediatric patients, aged 0–14 years, from Department Of Oral and Maxillofacial Pathology & Oral Microbiology, Indira Gandhi Government Dental College Jammu, J&K, from 2011 to 2022 were considered. Descriptive statistical analysis and using computer software Pearson's Chi-square test was performed.

**Results:** 36 biopsies (4.9%) belonged to pediatric population out of the total 727 biopsies that were received during the period. Females (64%) showed greater prevalence compared to males (36%). Affected age group seen were between 10–14 years. The most common category of lesions diagnosed were cysts and the odontogenic tumors were the least seen. Mandible showed more predilection compared to maxilla in jaws which was most common location involved, followed by the gingiva, palate, lower lip and labial mucosa. On comparing the histopathological diagnosis, dentigerous cysts (22%) were the most common followed by radicular cysts (17%), fibrous hyperplasia (14%), pyogenic granuloma (11%), central giant cell granuloma (8%), hyperplasia of minor salivary glands (5.6%) and percentage of aneurysmal bone cyst, peripheral giant cell granuloma, peripheral ossifying fibroma, central ossifying fibroma, juvenile ossifying fibroma, cementoblastoma, ameloblastoma and necrotic bone all was equal (2.8%). A statistically significant association of age and gender was seen with the category of the lesion.

**Conclusion:** The lesions were more common in the mandible with a female predilection and in age group >10 years. The majority of oral and maxillofacial lesions detected in pediatric population were benign similar to the previous reports.

This is an Open Access (OA) journal, and articles are distributed under the terms of the [Creative Commons Attribution-NonCommercial-ShareAlike 4.0 License](https://creativecommons.org/licenses/by-nc-sa/4.0/), which allows others to remix, tweak, and build upon the work non-commercially, as long as appropriate credit is given and the new creations are licensed under the identical terms.

For reprints contact: [reprint@ipinnovative.com](mailto:reprint@ipinnovative.com)

## 1. Introduction

Children which represent the future of the world, and thus, ensuring their healthy growth and development should be a major concern of all countries worldwide. Newborns and children are vulnerable to malnutrition and infectious diseases, many of which can be effectively prevented

or treated. It is estimated that in low- and middle-income countries (249 million) about 43% of the pediatric population that are younger than 5 years are at risk of not reaching their developmental potential.<sup>1</sup>

Due to the low frequency of hard tissue and soft tissue anomalies in oral region in children, the diagnosis is challenging. These lesion differs in distribution of age, sex, common location in oral cavity and origin of the lesion from

\* Corresponding author.

E-mail address: [beigshugufta@gmail.com](mailto:beigshugufta@gmail.com) (S. Shafi).

the others.<sup>2</sup>

The prevalence of these diseases among different regions of the world shows considerable variation as racial and environmental specificities, and the lifestyle of each population may be the influencing factors. The majority of studies regarding oral conditions have been limited to investigation of caries, periodontal disease, dental trauma, clefts and malocclusion in children, despite the suggestions made by World Health Organization (WHO) regarding the epidemiologic assessment of oral lesions.<sup>3</sup>

In children there is limited data available on the lesions such as jaw cysts, odontogenic tumors, benign and malignant neoplasms, and salivary gland pathologies.<sup>4</sup> Earlier studies conducted internationally such as one conducted by Skinner et al. over 14 year period in which they documented epidemiological information in the age group of 0–19 years old from 1525 biopsied oral lesions;<sup>5</sup> however, Jones and Franklin reported lesions in the age group of 0–16 years with the longest follow-up data (30 years) and the number of lesions being highest (4406).<sup>6</sup> Few studies that have been conducted in India on oral lesions in children which include one from Salem, Tamil Nadu, where Krishnan et al. analyzed 97 cases in 0–15 year age group in their 10 year period<sup>7</sup> and other in which they analyzed 540 cases aged 0–12 years over 10 year period conducted by Heera et al. from South Kerala.<sup>8</sup> However, upto date no such study has been reported in the Jammu & Kashmir region of India.

## 2. Aims and Objectives

1. To evaluate retrospectively, the pediatric oral biopsies received between 2011-2022 years in the Department Of Oral and Maxillofacial Pathology & Oral Microbiology, Indira Gandhi Government Dental College Jammu, J&K
2. To evaluate the total number of pediatric oral biopsies obtained below  $\leq 14$  years.
3. To evaluate the incidence of pediatric oral lesions in Jammu region of J&K.
4. To classify the pediatric oral pathologies based on age, sex and site predilection.
5. To identify the histopathological correlation in oral biopsies in clinically diagnosed pediatric oral lesions.

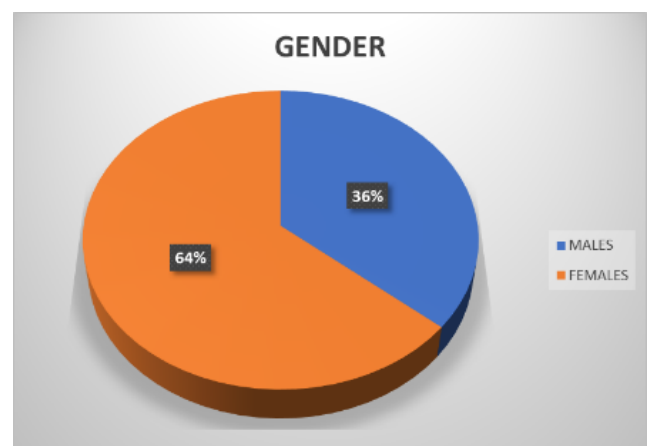
## 3. Materials and Methods

Archives of biopsy requisition form of pediatric patients between 0 and 14 years age group were retrieved from the Department of Oral and Maxillofacial Pathology & Oral Microbiology, Indira Gandhi Government Dental College Jammu, J&K, during the time period from January 2011 to December 2022. Information regarding the patients biodata including age, gender, location, provisional and histopathological diagnosis were collected and data was

calculated. Biopsies were grouped under four classes, that included jaw cysts, reactive lesions, fibro-osseous lesions and odontogenic tumors. Requisition forms with incomplete clinical information or missing diagnosis were excluded. In case of different diagnoses, the first diagnosis was recorded. In patients with double biopsy, diagnosis of the second biopsy was considered. Children were sorted under three age groups, i.e. < 5 years, 5-10 years, > 10 years, respectively. Data were tabulated and analyzed by descriptive statistics using the IBM, SPSS 20.0, Chicago, USA.

## 4. Results

In this study period of 12 years, 727 biopsies were received of which 36 (4.9%) belonged to pediatric population. Prevalence was more in females (64%) compared to males (36%) [Figure 1]. The age group 10–14 years was commonly affected and below 5 years were the least affected [Figure 2]. Mandible showed greater predilection compared to maxilla among the jaws were the most common location, which was followed by the gingiva, palate, lower lip and labial mucosa [Figure 3]. The fibromas as the provisional diagnosis were the most common pathologies which were received followed by dentigerous cysts, radicular cysts, mucoceles and pyogenic granulomas [Figure 4]. Histopathologically, dentigerous cysts (22%) were the most common followed by radicular cysts (17%), fibrous hyperplasia (14%), pyogenic granuloma (11%), central giant cell granuloma (8%), hyperplasia of minor salivary glands (5.6%) and equal percentage of aneurysmal bone cyst, peripheral giant cell granuloma, peripheral ossifying fibroma, central ossifying fibroma, juvenile ossifying fibroma, cementoblastoma, ameloblastoma, necrotic bone (2.8%) [Figure 5] [Table 1].



**Fig. 1:** Percentage distribution of cases according to gender shown in pie chart

Cysts were the most common lesions that were seen, out of which dentigerous cysts formed majority, followed

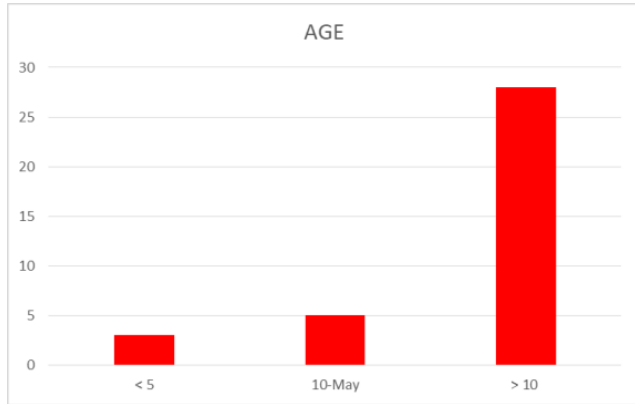


Fig. 2: Case distribution according to age shown in bar chart

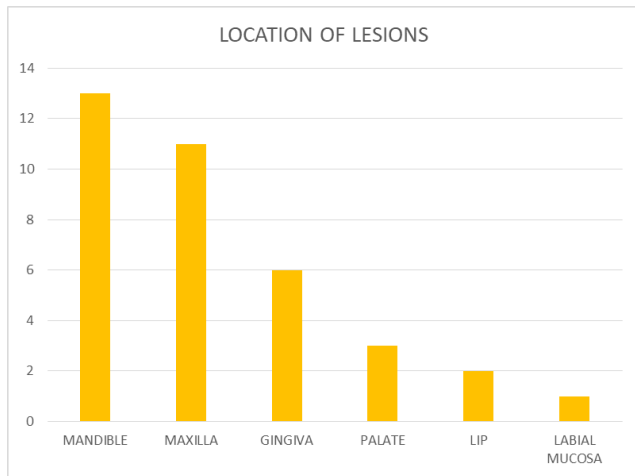


Fig. 3: Common pediatric lesions according to location in the oral and maxillofacial region shown in bar chart

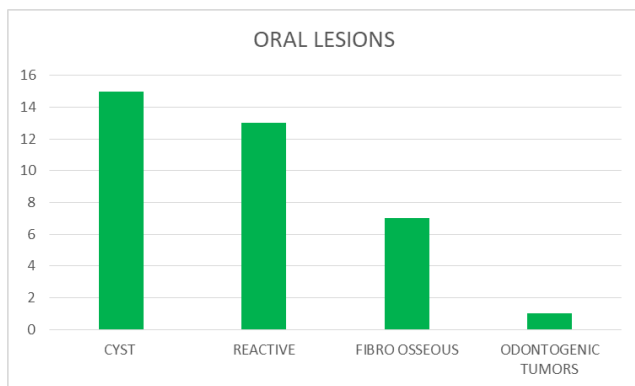


Fig. 4: Common pediatric oral lesions prevalence in different categories shown in bar chart

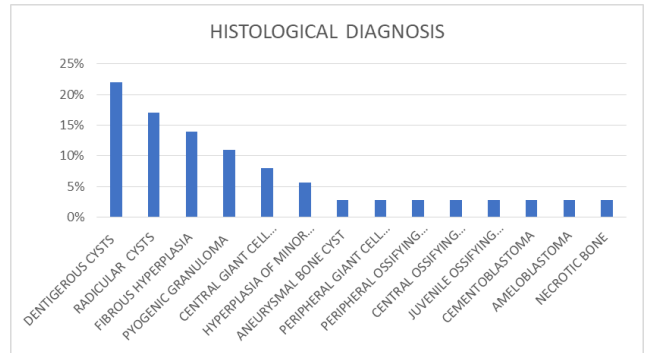
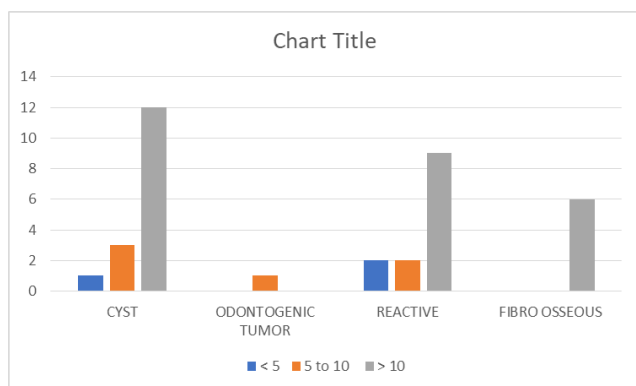


Fig. 5: Prevalence of histologically diagnosed pediatric oral lesions in different categories shown in bar chart

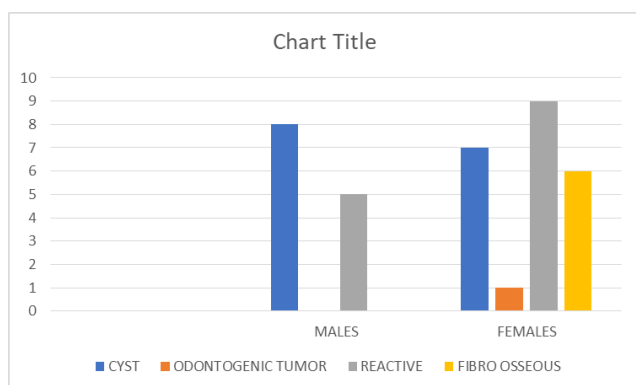
Table 1: Percentage distribution of biopsies according to histological diagnosis

S.No.	Histological Diagnosis	(% Age)
1	Dentigerous cysts	22%
2	Radicular cysts	17%
3	Fibrous hyperplasia	14%
4	Pyogenic granuloma	11%
5	Central giant cell granuloma	8%
6	Hyperplasia of minor salivary glands	5.6%
7	Aneurysmal bone cyst	2.8%
8	Peripheral giant cell granuloma	2.8%
9	Peripheral ossifying fibroma,	2.8%
10	Central ossifying fibroma	2.8%
11	Juvenile ossifying fibroma	2.8%
12	Cementoblastoma	2.8%
13	Ameloblastoma	2.8%
14	Necrotic bone	2.8%

by radicular and aneurysmal bone cysts. Among reactive lesions most commonly diagnosed were fibrous hyperplasia, followed by pyogenic granuloma, hyperplasia of minor salivary glands, peripheral giant cell granuloma and peripheral ossifying fibroma. Among fibroosseous lesions central giant cell granulomas were diagnosed the most, followed by central ossifying fibroma, juvenile ossifying fibroma, cementoblastoma and necrotic bone. Among odontogenic tumors only ameloblastoma was diagnosed [Figure 5]. Age showed a significant association with the diagnosis where cysts, reactive and fibroosseous were seen in majority of the patients aged greater than 10 years age group. In the age group of 5-10 years again majority of the cases diagnosed were cysts, followed by reactive lesions and odontogenic tumors. In age group less than 5 years majority cases diagnosed were reactive lesions and cysts [Figure 6]. There was also significant association between gender and diagnosis with reactive lesions, fibroosseous lesions and odontogenic tumors were seen more in females and cysts were seen more in males [Figure 7].



**Fig. 6:** Distribution of age in common oral lesions in pediatric population shown in bar chart



**Fig. 7:** Distribution of gender among the common oral lesions in pediatric population shown in bar chart

## 5. Discussion

Many studies have been done worldwide and in India regarding the histopathological correlation of oral pediatric lesions. Pediatric biopsies account about <10% of overall cases in literature referred for histopathology services in most of the foreign and Indian studies that are available.<sup>8</sup> However, prevalence between 11% and 27.2% was found by many authors.<sup>9</sup> Prevalence of 4.9%, was seen in our study on comparing the total number of biopsies referred to the department. These pathologies were reported in mixed dentition in children aged above 10 years as mentioned in previous studies.<sup>7,10–14</sup> In our study, age group were further divided into three groups, namely <5 years, 5–10 years and >10 years but the age group between 10–14 years accounted for most of the pathologies. To determine the age interval for occurrence of these pathologies, difficulties among the pediatric population could be partly because there has been variations in the age range considered for pathologies in various studies.<sup>8</sup> The incidence of these pathologies among males and females was reported to be equal in most of the studies,<sup>6,12</sup> but occurrences in females is more in the studies reported in India.<sup>7,8</sup> This study also reported the

pediatric oral pathologies to be more prevalent in females (64%) as compared to males (36%). Also in this study most commonly affected site was mandible which is in harmony with the previous three studies reported in South India.<sup>7,8,15</sup> Studies of Maia<sup>16</sup> et al., and Lima<sup>10</sup> et al., reported maxilla as the most common site, but in our study mandible was found to be more affected than maxilla.

### 5.1. Cysts

In our study, dentigerous cysts were the most common followed by radicular/ periapical cysts. Dentigerous cysts were also the most common in the studies reported by Monique Maria Melo Mouchrek et al.,<sup>9</sup> Kittipong Dhanuthai et al.,<sup>17</sup> and Sumithra Das et al.<sup>12</sup>. A single case of aneurysmal bone cyst was also seen in our study. Thus majority of diagnosis was formed by the cysts (42%), mostly seen in children that were above 10 years. Krishnan et al. and Heera et al also showed cysts forming the majority of the diagnosis in there studies.<sup>7,8</sup>

### 5.2. Reactive lesions

In our study percentage of reactive lesions was 36%, which was more in females and in children of age group above 10 years. Most commonly diagnosed was fibrous hyperplasia, followed by pyogenic granuloma, hyperplasia of minor salivary glands, peripheral giant cell granuloma and peripheral ossifying fibroma. According to Mouchrek MM et al.,<sup>9</sup> inflammatory fibrous hyperplasia was the commonest lesion. According to Gultekin et al.,<sup>18</sup> peripheral giant cell granuloma was the most common lesion. Pyogenic granuloma was found to be the highest in this category by Saravani et al.<sup>4</sup>

### 5.3. Fibroosseous lesions

They formed 19.2% of pathologies with majority being central giant cell granulomas, followed by central ossifying fibroma, juvenile ossifying fibroma, cementoblastoma and necrotic bone. In the second and third decades of life these lesions are more common and it could be a reason that in children below 14 years of age lesser number of these lesions were being observed. Saxena et al.,<sup>19</sup> studied pediatric jaw tumours and have reported 9 cases of fibrous dysplasia which was not seen in our study.

### 5.4. Odontogenic tumors

Odontogenic tumors constitute about 2.8% of pediatric pathologies with only one case each of ameloblastoma. Krishnan et al.<sup>4</sup> and Dhanuthai et al. in their studies showed ameloblastoma to be the most common in this category.<sup>18</sup> However reported in the odontogenic category, odontomas have been majority in the international studies [4,5,9-11,17-19] and Indian studies.<sup>8,15</sup>

## 6. Conclusion

Our study is an attempt to study the common pediatric oral pathologies reported to Department Of Oral and Maxillofacial Pathology & Oral Microbiology, Indira Gandhi Government Dental College Jammu, J&K, from 2011 to 2022. The majority of the oral pathologies detected were benign. This study will throw some light regarding the prevalence and characteristics of the lesions prevailing in the pediatric population in Jammu region of J&K which in turn will be useful for the general dentist, researchers, surgeons, and pediatric dentists in diagnosing and managing these lesions appropriately to seek better health care and contribute to the data regarding pediatric oral biopsies.

## 7. Conflict of Interest

There are no conflicts of interest in this article.

## 8. Source of Funding

None.

## References

- Lu C, Black MM, Richter LM. Risk of poor development in young children in low-income and middle-income countries: an estimation and analysis at the global, regional, and country level. *Lancet Glob Health*. 2016;4(12):916–22.
- Flaitz CM. Differential Diagnosis of Oral Lesions and Developmental Anomalies. In: Cosamassimo P, Fiells HW, Mctigne D, Nowak A, editors. *Pediatric Dentistry Infancy through Adolescence*. 5th edn.. vol. 63043. St. Louis: Missouri: Elsevier Inc; 2013. p. 11.
- Siadati S, Seyedmajidi M, Sharbatdaran M. Frequency of different oral lesions in children and adolescents in Babol, Northern Iran. *Caspian J Intern Med*. 2013;4(4):773–6.
- Saravani S, Kadeh H, Amirabadi F, Keramati N. Clinical and histopathological profiles of pediatric and adolescent oral and maxillofacial biopsies in a Persian population. *Int J Pediatr*. 2015;3(1):381–90.
- Skinner RL, Davenport WD, Weir JC, Carr RF. A survey of biopsied oral lesions in pediatric dental patients. *Pediatr Dent*. 1986;8(2):163–7.
- Jones AV, Franklin CD. An analysis of oral and maxillofacial pathology found in children over a 30-year period. *Int J Paediatr Dent*. 2006;16(1):19–30. doi:10.1111/j.1365-263X.2006.00683.x.
- Krishnan R, Ramesh M, Paul G. Retrospective evaluation of pediatric oral biopsies from a dental and maxillofacial surgery centre in. *J Clin Diagn Res*. 2014;8(1):221–3. doi:10.7860/JCDR/2014/6805.3930.
- Heera R, Bharathan R, Padmakumar SK, Rajeev R, Sivakumar R. Oral and maxillofacial biopsy reports of children in south Kerala population: A 20-year retrospective study. *Int J Sci Stud*. 2016;4(8):104–8. doi:10.17354/ijss/2016/579.
- Mouchrek MMM, Gonçalves LM, Bezerra-Júnior JRS, Maia ES, Silva RA, Cruz MD, et al. Oral and maxillofacial biopsied lesions in Brazilian pediatric patients: A 16-year retrospective study. *Rev Odonto Cienc*. 2011;26(3):222–6. doi:10.1590/S1980-65232011000300005.
- Gda SL, Fontes ST, De Araújo L, Etges A, Tarquinio SB, Gomes AP, et al. A survey of oral and maxillofacial biopsies in children: A singlecenter retrospective study of 20 years in Pelotas&#8209;Brazil. *J Appl Oral Sci*. 2008;16(6):397–402. doi:10.1590/s1678-77572008000600008.
- Lei F, Chen J, Lin L, Wang W, Huang H, Chen C, et al. Retrospective study of biopsied oral and maxillofacial lesions in pediatric patients from Southern Taiwan. *J Dent Sci*. 2014;9(4):351–8. doi:10.1016/j.jds.2013.03.002.
- Das S, Das AK. A review of pediatric oral biopsies from a surgical pathology service in a dental school. *Pediatr Dent*. 1993;15(3):208–11.
- Hussein AA, Darwazeh AM, Jundi SH. Prevalence of oral lesions among Jordanian children. *Saudi J Oral Sci*. 2017;4(1):12–7. doi:10.4103/1658-6816.200135.
- Vale EB, Perez FM, Rodrigues GL, Carvalho EJ, Castro JF, Perez DE, et al. A review of oral biopsies in children and adolescents: A clinicopathological study of a case series. *J Clin Exp Dent*. 2013;5(3):144–9. doi:10.4317/jced.51122.
- Salian V, Shetty P. Clinicopathologic trends in pediatric oral biopsies: A 10-year institutional archival study. *Int J App Basic Med Res*. 2019;9(1):44–8. doi:10.4103/ijabmr.IJABMR\_253\_18.
- Maia DM, Merly F, Castro WH, Gomez RS. A survey of oral biopsies in Brazilian pediatric patients. *ASDC J Dent*. 2000;67(2):128–31.
- Dhanuthai K, Banrai M, Limpanaputtajak S. A retrospective study of paediatric oral lesions from Thailand. *Int J Paediatr Dent*. 2007;17(4):248–53. doi:10.1111/j.1365-263X.2007.00828.x.
- Gültelkin SE, Tokman B, Türkseven MR. A review of paediatric oral biopsies in Turkey. *Int Dent J*. 2003;53(1):26–32. doi:10.1111/j.1875-595x.2003.tb00652.x.
- Saxena S, Kumar S, Pundir S. Pediatric jaw Tumours: Our experience. *J Oral Maxillofac Pathol*. 2012;16(1):27–30. doi:10.4103/0973-029X.92969.

## Author biography

**Rakesh K Gupta**, Principal

**Shugufta Shafi**, Post Graduate

**Rubeena Anjum**, Professor and HOD

**Mandeep Kaur**, Assistant Professor

**Cite this article:** Gupta RK, Shafi S, Anjum R, Kaur M. Histopathological correlation in oral biopsies in clinically diagnosed pediatric oral lesions: A 12-year institutional archival study. *IP J Diagn Pathol Oncol* 2023;8(2):68-72.