

Content available at: <https://www.ipinnovative.com/open-access-journals>

IP Journal of Diagnostic Pathology and Oncology

Journal homepage: <https://www.jdpo.org/>

## Case Report

# Primary vaginal villous adenoma – A rare case report

Rakesh Rajiv Patkar<sup>1</sup>, Shilpa Mishra<sup>1,\*</sup>, Amrita Neelakantan<sup>1</sup>

<sup>1</sup>Dept. of Pathology, Plus Care Internationals Pvt. Ltd, Mumbai, Maharashtra, India



### ARTICLE INFO

#### Article history:

Received 16-08-2022

Accepted 11-11-2022

Available online 14-01-2023

#### Keywords:

Villous adenoma

Vaginal mass

Vaginal vault

### ABSTRACT

Villous adenomas are known to occur in gastrointestinal tract; however, they are very rare in female genital tract. The pathogenesis is unclear but their origin from cloacal remnants has been hypothesized. Here we report a rare incidental case of primary villous adenoma with high grade dysplasia arising from vaginal vault in a 28-year-old female who presented with abnormal vaginal bleeding. The importance of reporting this lies in its pre-malignant behaviour and benign looking clinical appearance.

This is an Open Access (OA) journal, and articles are distributed under the terms of the [Creative Commons Attribution-NonCommercial-ShareAlike 4.0 License](https://creativecommons.org/licenses/by-nc-sa/4.0/), which allows others to remix, tweak, and build upon the work non-commercially, as long as appropriate credit is given and the new creations are licensed under the identical terms.

For reprints contact: [reprint@ipinnovative.com](mailto:reprint@ipinnovative.com)

## 1. Introduction

Primary villous adenomas of vaginal vault with enteric type morphology are very rare as compared to their gastrointestinal counterparts and they may have malignant potential.<sup>1,2</sup> Villous adenomas usually arise in colon and rectum and are premalignant.<sup>3</sup> Their origin in the vagina is speculated to be from cloacal remnants or acquired intestinal metaplasia.<sup>3,4</sup> Morphologically vaginal adenomas are similar to similar to gastro-intestinal adenomas and can be tubular, tubulo-villous, and villous type.<sup>1,5</sup> There may be varying degrees of dysplasia based on morphological and cytological criteria similar to their intestinal counterparts classified as low grade and high grade. This influences the rate of premalignant to malignant conversion in a statistically significant manner. The current case had vaginal villous adenoma with high grade dysplasia. Due to unusual location these can possess a diagnostic dilemma if there is lack of understanding of this specific entity. It would be prudent to note that only a handful of cases, approximately less than 10, have been reported in English literature (specific to this entity of primary villous adenoma of the

vagina).

## 2. Case Report

A 28-year-old woman presented with abnormal vaginal bleeding. On gynaecological examination a soft well-defined polypoidal growth measuring 1 x 1 x 1 cm was noted at posterior vaginal vault. The patient did not have any other similar lesions elsewhere and she had no other systemic illness. The polyp was excised and we received fragmented congested tissue bits for histopathology. The sample was processed entirely and slides were stained with haematoxylin and eosin.

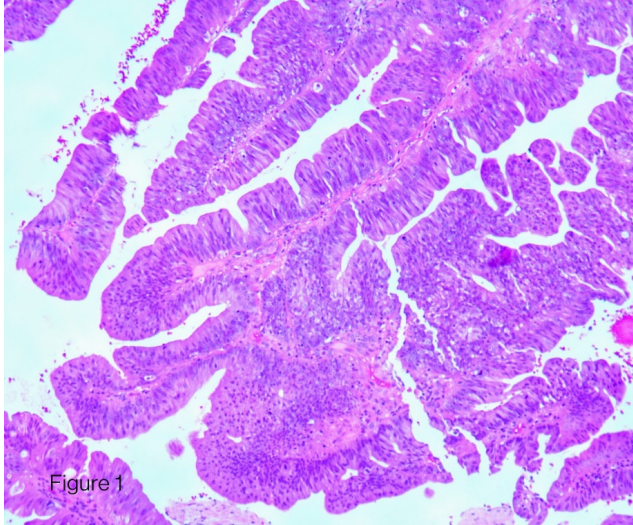
### 2.1. Microscopic findings

Sections studied showed epithelial finger-like projection (intestinal type) formed by fibro-vascular cores lined by dysplastic epithelium (villous architecture from). The epithelium was pseudostratified columnar with moderate amounts of eosinophilic cytoplasm. Nuclei were elongated to ovoid with vesicular chromatin and prominent nucleoli. At places the thickness of epithelium was increased and nuclei occupied the full thickness. Loss of nuclear polarity was noted. Mitotic activity was brisk with atypical mitosis.

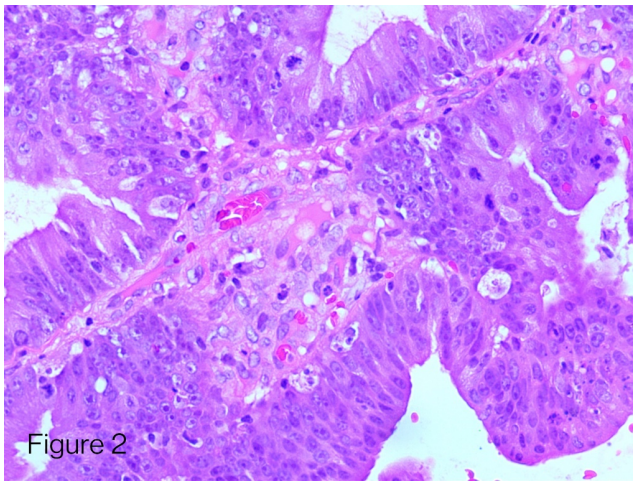
\* Corresponding author.

E-mail address: [mishra.sm012@gmail.com](mailto:mishra.sm012@gmail.com) (S. Mishra).

Fibrovascular stroma showed chronic inflammation and invasion into the stroma and stalk was absent. Based on above findings diagnosis of primary vaginal villous adenoma with high grade dysplasia was made (Figures 1, 2, 3, 4 and 5).



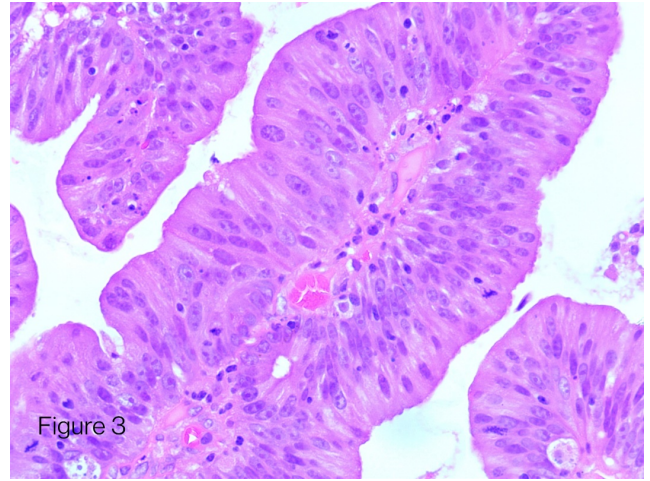
**Fig. 1:** (100x): Branching villi lined by columnar epithelium with elongated, stratified nuclei.



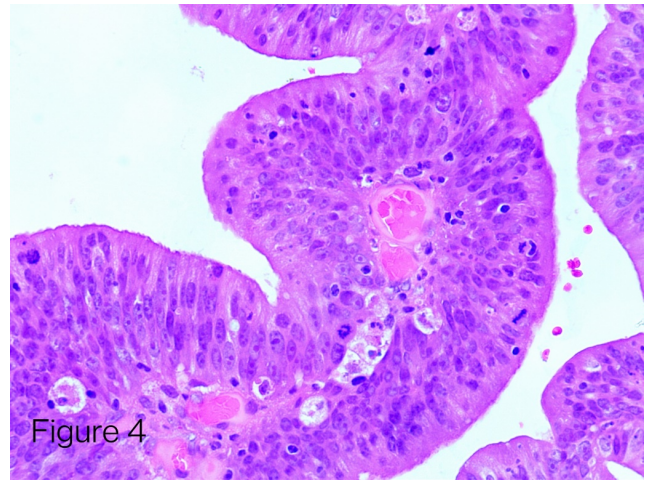
**Fig. 2:** (400x): Dysplastic columnar epithelium showing vesicular nuclei and prominent nucleoli.

### 3. Discussion

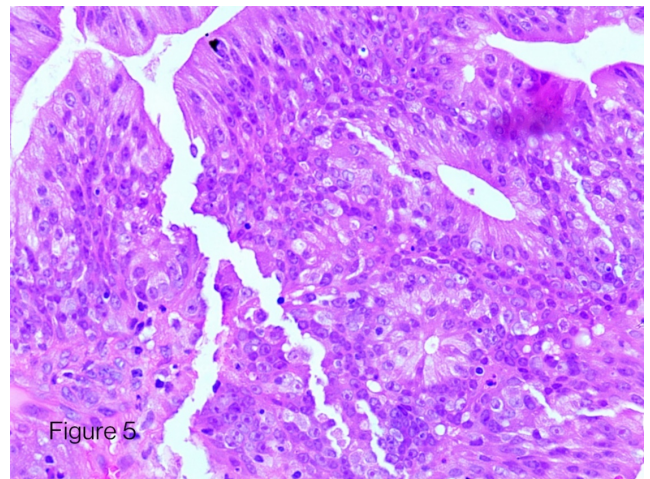
Tubulo-villous adenomas are a common occurrence in gastro-intestinal tract; however they are rare in other sites. A few case reports of primary villous adenoma with intestinal type morphology arising from urinary bladder, urethra and cervix have been described as well.<sup>4,6</sup> Villous adenoma of endodermal origin with involvement of rectovaginal septum



**Fig. 3:** (400x): High grade dysplasia, with increased mitosis and atypical mitotic activity.



**Fig. 4:** (400x): Dysplasia with increased mitosis.



**Fig. 5:** (400x): Cytoarchitectural disorganisation with tubulo-villous component.

in a 72-year-old female was first described in 1987.<sup>7</sup>

In the present case; the polypoidal lesion was arising from the posterior vaginal vault. Posterior vaginal wall was the common site for enteric type lesions and intestinal type adenocarcinomas in few previous studies.<sup>2,8</sup>

As per discussion by Shivaprakash et al and Pena-Fernandez et al the origin of these lesions is speculated to be from cloacal remnants.<sup>3,5</sup> Other theories for origin of glandular lesion in vagina are dysplasia following intestinal metaplasia (acquired), outgrowing contiguous gastrointestinal neoplasm or metastasis from a distant gastrointestinal neoplasm.<sup>9</sup> Few studies suggest that tissue of mullerian origin may undergo intestinal metaplasia. The vagina is derived embryologically from the urogenital sinus and enteric type tumors may arise from cloacal remnants.<sup>4</sup>

Villous adenomas may eventually develop into adenocarcinomas and Creswell et al have described their relation with diethylstilbesterol (DES) exposure in utero.<sup>1</sup> Our case did not have the above risk factor.

The current case which we describe in this study had a polypoidal lesion; quite similar to previous studies.<sup>5–10</sup> The morphology in the current case was similar to villous adenomas arising in gastrointestinal tract. As per discussion by Pena-Fernandez the tubulo-villous pattern was more common in vagina than pure villous architecture.<sup>5</sup> Our case showed a purely villous pattern. These villi were lined by dysplastic columnar epithelium which stratified and had a central fibrovascular core. These findings were similar to the case described by Shivaprakash et al.<sup>3</sup> Due to paucity of data it is not possible to state the exact rate of conversion of this known but rare premalignant lesion in this anatomic site; more studies would be required for the same. In the same note we would like to add that there is paucity of molecular data however APC, K-RAS, p53 or BRAF genes are implicated in their colonic counterparts.<sup>5,11</sup>

#### 4. Conclusion

Primary villous adenomas of vagina are exceedingly rare compared to gastro-intestinal adenomas. They are hypothesized to originate from adenosis or cloacal remnants in the rectovaginal septum. Owing to their pre-malignant behaviour and unusual location meticulous clinical and histopathological correlation is advised. Regular close follow up of the patients with intestinal tumors outside gastro-intestinal system is advised to rule out any associated syndrome or primary gastrointestinal neoplasms.

#### 5. Source of Funding

None.

#### 6. Conflict of Interest

None Declared.

#### References

1. Creswell ML, Ilagan CJ, Downs SG, Dainty LA, Kowalczyk K, Shaw NM, et al. Giant primary vaginal tubulovillous adenoma: A case report and review of literature. *Urol Case Rep.* 2021;38:101734. doi:10.1016/j.eucr.2021.101734.
2. Lu W, Zhang X, Lu B. Benign intestinal glandular lesions in the vagina: a possible correlation with implantation. *Diagn Pathol.* 2016;11(1):52. doi:10.1186/s13000-016-0503-5.
3. Shivaprakash HN, Jayashree K, Girish M. Villous adenoma: a rare tumor of vaginal vault. *Indian J Pathol Microbiol.* 2008;51(2):265–6. doi:10.4103/0377-4929.41684.
4. Cobanoglu U, Ozoran Y. Tubulo-villous adenoma of the vagina - case. *Aegean Pathol J.* 2004;1:47–9.
5. Peña-Fernández M, Abdulkader-Nalib I, Novo-Domínguez A, Turrado-Sánchez EM, Brea-Fernández A, Sebio-Lago L, et al. Vaginal tubulovillous adenoma: a clinicopathologic and molecular study with review of the literature. *Int J Gynecol Pathol.* 2013;32(1):131–6. doi:10.1097/PGP.0b013e31824fe2c8.
6. Micheal H, Sutton G, Hull MT, Roth LM. Villous adenoma of the uterine cervix associated with invasive adenocarcinoma: a histologic, ultrastructural, and immunohistochemical study. *Int J Gynecol Pathol.* 1986;5(2):163–9.
7. Ciano PS, Antoniolio DA, Critchlow J, Burke L, Goldman H. Villous adenoma presenting as a vaginal polyp in a rectovaginal polyp. *Hum Pathol.* 1987;18(8):863–6. doi:10.1016/s0046-8177(87)80063-1.
8. Staats PN, Mccluggage WG, Clement PB, Young RH. Primary intestinal-type glandular lesions of the vagina: clinical, pathologic, and immunohistochemical features of 14 cases ranging from benign polyp to adenoma to adenocarcinoma. *Am J Surg Pathol.* 2014;38(5):593–603.
9. Mortensen BB, Nielsen K. Tubulo-villous adenoma of the female genital tract: a case report and review of literature. *Acta Obstet Gynecol Scand.* 1991;70(2):161–3. doi:10.3109/00016349109006201.
10. Can B, Gün S, Aydin O, Kandemir B. Primary intestinal-type adenoma of the vagina arising directly from endocervical-type adenosis: a case report. *J Reprod Med.* 2012;57(1-2):68–73.
11. Shuangshoti S, Teerapakpinyo C. Tubulovillous Adenoma of Vagina With Both KRAS and APC Mutations: Case Report. *Int J Gynecol Pathol.* 2019;38(5):498–501.

#### Author biography

**Rakesh Rajiv Patkar**, Head & Consultant

**Shilpa Mishra**, Consultant  <https://orcid.org/0000-0002-0831-5096>

**Amrita Neelakantan**, Pathologist

**Cite this article:** Patkar RR, Mishra S, Neelakantan A. Primary vaginal villous adenoma – A rare case report. *IP J Diagn Pathol Oncol* 2022;7(4):255-257.