

Content available at: <https://www.ipinnovative.com/open-access-journals>

IP Journal of Diagnostic Pathology and Oncology

Journal homepage: <https://www.jdpo.org/>

## Case Report

# Sino-nasal and pharyngeal mass- Immunohistochemistry cuts the gordian knot

Geethamala K<sup>1,\*</sup>, Meena N Jadhav<sup>1</sup>, Sneha K<sup>1</sup>, Nirmala BL<sup>1</sup>, Rekha M Haravi<sup>1</sup>, Shirish Patil<sup>2</sup>

<sup>1</sup>Dept. of Pathology, Belgaum Institute of Medical Sciences, Belagavi, Karnataka, India

<sup>2</sup>Dept. of ENT, Belgaum Institute of Medical Sciences, Belagavi, Karnataka, India



### ARTICLE INFO

#### Article history:

Received 16-09-2022

Accepted 07-10-2022

Available online 14-01-2023

#### Keywords:

Extra skeletal Ewing sarcoma

Ethmoid sinus

Immunohistochemistry

### ABSTRACT

Sinonasal and pharyngeal mass lesion of Extraskelatal Ewing sarcomas (EWSs) are extremely rare. Herein we present a case of EWSs of ethmoid sinus extending into nasal and pharyngeal spaces mimicking as angiofibroma clinically. Histopathological examination in conjunction with immunohistochemistry puzzled out the diagnostic dilemma.

This is an Open Access (OA) journal, and articles are distributed under the terms of the [Creative Commons Attribution-NonCommercial-ShareAlike 4.0 License](https://creativecommons.org/licenses/by-nc-sa/4.0/), which allows others to remix, tweak, and build upon the work non-commercially, as long as appropriate credit is given and the new creations are licensed under the identical terms.

For reprints contact: [reprint@ipinnovative.com](mailto:reprint@ipinnovative.com)

## 1. Introduction

The anatomic area of sinuses, nasal cavity and pharynx are the rare sites of benign and malignant tumors of various histopathologic origins.<sup>1</sup> The presenting symptomatology of all these tumors is similar; hence need multidisciplinary approach for diagnosis and further management. A diligent histopathological examination is necessary to decide on the nature of the lesion.<sup>1</sup> Primary Ewing Sarcomas (EWSs), a highly malignant, small and round cell tumor of bone. Extraskelatal Ewing Sarcomas (EWSs) of the head and neck region are infrequent, accounting for only 4–9% of all EWSs.<sup>2,3</sup> Literature search reveals sinonasal and pharyngeal sites of EWSs are extremely rare.<sup>2–6</sup> Herein, we present a case of EWSs of ethmoid sinus mimicking as angiofibroma clinically.

## 2. Case Report

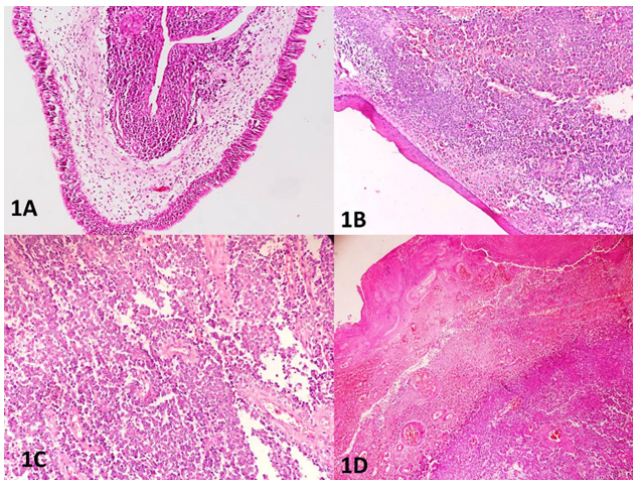
A 17 year old college going student, had complaints of difficulty in breathing, nasal obstruction and intermittent episodes of mild epistaxis past 2 months. On consultation

with general physician, taken a course of antibiotics but to vain, hence referred to higher center for further evaluation. At our hospital otorhinolaryngology department, clinical examination showed reddish polypoidal mass filling both the nasal cavities extending into pharynx with no external nasal deformity, nasal or facial swelling. His past history was unremarkable. Considering the age and clinical manifestations, the case was clinically diagnosed as polypoidal nasopharyngeal mass and was further referred to radioimaging. Computed tomography with contrast revealed a mass arising from ethmoid sinus involving sphenoid sinus and nasopharynx of both sides eroding greater wing of sphenoid bone with no intracranial extension. Mass was seen involving parapharyngeal, infratemporal spaces, cavernous sinus but internal carotid artery spared. Magnetic resonance imaging done showed similar findings and reported as sinonasal pharyngeal mass diagnosed as angiofibroma. Further transnasal endoscopic biopsy was done; biopsies of polypoidal masses were done and sent for histopathological examination. No immediate complications or excessive bleeding occurred post-procedure and patient was stable. In the pathology department, we received two containers

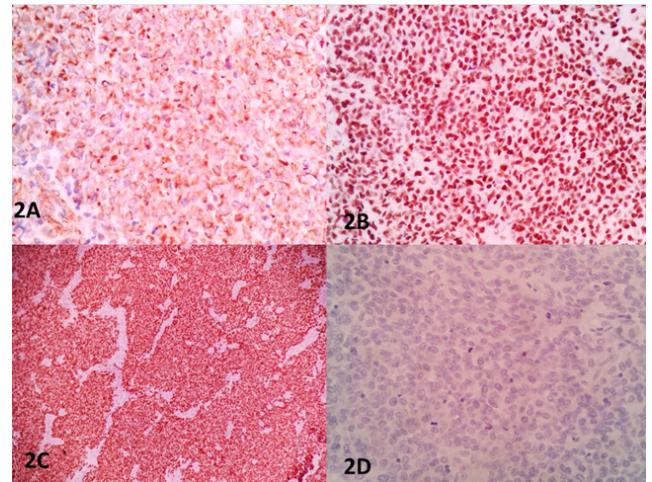
\* Corresponding author.

E-mail address: [drgeethamala@gmail.com](mailto:drgeethamala@gmail.com) (Geethamala K).

labelled as right and left sinonasal pharyngeal growth biopsy consisting of multiple grey-white to grey-brown soft tissue fragments largest measuring 3x1.5x1cm and smallest measuring 1.5x1x1cm. Microscopy revealed biopsy fragments of tissue lined by respiratory epithelium with focal squamous metaplasia, ulceration and underlying tumor tissue. The tumor cells were arranged in sheets, lobules, nests separated by thin fibrovascular septae and few singly scattered cells. These individual cells were round to oval with increased nucleo-cytoplasmic ratio, vesicular to hyperchromatic nuclei, indistinct nucleoli, few with open chromatin and cytoplasmic borders. Tumor emboli, areas of necrosis and hemorrhage were seen. Also seen were foci of bony trabeculae, cartilage, seromucinous glands, thick walled blood vessels and nerve bundles. Stroma was made up of fibrocollagenous tissue. (Figure 1A,B,C,D) Histopathological diagnosis of small round cell tumor with differential diagnosis of sinonasal undifferentiated carcinoma, olfactory neuroblastoma and small cell undifferentiated neuroendocrine tumor. Immunohistochemistry (IHC) was advised for further confirmation. The tumor was Immunoreactive for vimentin, CD-99, NKX2.2 and FLI1 and was negative for TLE1, EMA, S-100, INSM1, Synaptophysin, CD-31, CD-34, ERG and pancytokeratin (AE1/AE3). (Figure 2A,B,C,D) Hence was finally diagnosed as Extraskeletal Ewing sarcoma of ethmoid sinus.



**Fig. 1:** **A:** Microscopy showing biopsy fragments of tissue lined by respiratory epithelium and underlying tumor tissue. (H&E, 10x); **B:** Microscopy showing biopsy fragments of tissue with focal squamous metaplasia and underlying tumor tissue. (H&E, 10x); **C:** Microscopy showing the tumor cells arranged in sheets, lobules, nests separated by thin fibrovascular septae and few singly scattered cells. (H&E, 10x); **D:** Microscopy showing the tumor cells and extensive areas of necrosis. (H&E, 10x)



**Fig. 2:** **A:** Microscopy showing immunoreactivity for CD 99 diffuse membranous positivity of tumor cells. (IHC, 100x); **B:** Microscopy showing immunoreactivity for NKX2.2 nuclear positivity of tumor cells. (IHC, 100x); **C:** Microscopy showing immunoreactivity for FLI1 nuclear positivity of tumor cells. (IHC, 100x); **D:** Microscopy showing immunonegative for TLE1, EMA, S-100, INSM1, Synaptophysin, CD-31, CD-34, ERG and pancytokeratin (AE1/AE3) of tumor cells. (IHC, 100x)

### 3. Discussion

EWS is a highly malignant, small, round cell tumor that originates from the primitive neuroectodermal cells. It was first described by James Ewing in 1921.<sup>2</sup> Angervall and Enzinger introduced the term Extraskeletal Ewing sarcoma as an entity in 1975.<sup>2,3</sup> EEWSs most commonly occur in chest wall, lower extremities, paravertebral region and less frequently in pelvis, retroperitoneum and upper extremities. EEWSs of the head and neck region are extremely rare, accounting for only 4–9% of all EWSs.<sup>4,5</sup>

Literature search reveals EEWSs is found more commonly in older patients, the average age being 20-30 years and equal distribution between sexes as compared to EWSs being more in males and age range between 10-20 years.<sup>4-6</sup> Our index case was 17 year old, much younger compared to other studies.<sup>6,7</sup> 12.5% patients with EEWS of the head and neck region have metastases to lung as the commonest site at diagnosis. In our case, the patient did not have metastasis.<sup>4-7</sup>

The clinical manifestations of EEWSs of nasal and paranasal sites can present with nonspecific symptoms such as nasal obstruction, rhinorrhea and epistaxis making the diagnosis difficult.<sup>4-8</sup> In the present study, the age of presentation, sex and nasal mass raised the diagnosis of angiofibroma clinically. Based on clinical and radiological examination alone, it is difficult to differentiate EEWSs from similar tumors arising from the sinonasal tract; similar to our case, where it was diagnosed as juvenile angiofibroma.

EEWS presents a wide histological spectrum which requires histopathological examination, immunohistochemistry and cytogenetic analysis to make definitive diagnosis.<sup>9,10</sup> Microscopically, tumor cells are arranged in sheets and islands separated by dense fibrous septae. The tumor cells are uniform small round cells with round nuclei, finely stippled chromatin and inconspicuous nucleoli. Cells show scant clear or eosinophilic cytoplasm with indistinct cytoplasmic membranes. In the sinonasal tract, the differential diagnosis includes all tumors that are composed of small round cells such as sinonasal undifferentiated carcinoma, olfactory neuroblastoma, lymphoma, poorly differentiated carcinomas, melanoma and Ewing family tumors (EFT).<sup>9,10</sup> Similar differential diagnosis on histopathology was offered in our case.

On immunohistochemical examination, the neoplastic cells express strong and diffuse membranous CD99 positivity in nearly 90-95% of all cases. Nuclear positivity for FLI-1 and NKX2.2 are seen in large percentage of cases. Epithelial, neuroendocrine and hematolymphoid markers are typically absent.<sup>9-11</sup> In our case too, the immunohistochemistry showed the small blue cells with immunoreactivity for vimentin, CD99, FLI-1, NKX2.2. Negative for TLE1, EMA, S-100, INSM1, Synaptophysin, CD-31, CD-34, ERG and pancytokeratin (AE1/AE3) markers. The cytogenetic analysis of EFTs show t(11,22)(q24;q12) translocation as the most common diagnostic translocation, accounting for more than 85% of cases.<sup>10,12</sup> Other diagnostic translocations involving the Ewing sarcoma locus on chromosome 22 are translocations of t(21,22)(q22;q12) and t(7,22)(p22;q12).<sup>10,12</sup> However, in our case, we did not perform the cytogenetic test in view of costs related issues. Therefore, the final diagnosis of EEWS was made based on the histopathological features and confirmation by immunohistochemical markers expression.

Recommended treatment protocol of sinonasal EEWS include combined strategy of surgical excision with negative margins and modern neoadjuvant chemotherapy and/or radiotherapy. If surgically, negative margins are not attainable as it is difficult in sinonasal areas; local regional control with radiotherapy is preferred treatment modality.<sup>13,14</sup> Studies show combined treatment management has increased the overall 5-year survival rate 20 to 70%.<sup>13,14</sup> In our case, the patient was surgically treated and referred to cancer center for chemotherapy and radiotherapy as per oncologist prospective. Patient was lost to follow up subsequently.

#### 4. Conclusion

Sinonasal and pharyngeal masses pose conundrum due to myriad of differential diagnosis specially, if they microscopically present as small round cell tumor family. The present case highlight, the importance of histopathological examination in conjunction with

immunohistochemistry puzzled out the diagnostic dilemma.

#### 5. Source of Funding

This research did not receive any specific grant from funding agencies in the public, commercial, or not-for-profit sectors.

#### 6. Conflicts of Interest

None to declare.

#### References

- Whaley JT, Indelicato DJ, Morris CG, Hinerman RW, Amdur RJ, Mendenhall WM, et al. Ewing tumors of the head and neck. *Am J Clin Oncol.* 2010;33(4):321–6.
- Ewing J. Diffuse endothelioma of bone. *Pathol Soc.* 1921;21:17–24.
- Ludwig JA. Ewing sarcoma: historical perspectives, current state-of-the-art, and opportunities for targeted therapy in the future. *Curr Opin Oncol.* 2008;20(4):412–8. doi:10.1097/CCO.0b013e328303ba1d.
- Siegal GP, Oliver WR, Reinius WR, Gilula LA, Foulkes MA, Kissane JM, et al. Primary Ewing's sarcoma involving the bones of head and neck. *Cancer.* 1987;60(11):2829–40. doi:10.1002/1097-0142(19871201)60:11<2829::aid-cnrc2820601139>3.0.co;2-s.
- Allam A, El-Husseinty G, Khafaga Y, Kandil A, Gray A, Ezzat A, et al. Ewing's sarcoma of the head and neck: a retrospective analysis of 24 cases. *Sarcoma.* 1999;3(1):11–5. doi:10.1080/13577149977811.
- Lin JK, Liang J. Sinonasal ewing sarcoma: A case report and literature review. *Perm J.* 2018;22:17–086. doi:10.7812/TPP/17-086.
- Satish D, Nanadakumar R, Balasubramanya AM, Mathew N. A rare case of Ewing's sarcoma in the sinonasal tract. *Int J Otorhinolaryngol Head Neck Surg.* 2018;4(1):304–7.
- Yeshvanth SK, Ninan K, Bhandary SK, Lakshinarayana KP, Shetty JK, Makannavar JH, et al. Rare case of extraskelatal Ewings sarcoma of the sinonasal tract. *J Cancer Res Ther.* 2012;8(1):142–4. doi:10.4103/0973-1482.95197.
- Iezzoni JC, Mills SE. "Undifferentiated" small round cell tumors of the sinonasal tract: differential diagnosis update. *Am J Clin Pathol.* 2005;124:110–21. doi:10.1309/59RBT2RK6LQE4YHB.
- Unni K. Pathology and genetics of tumours of soft tissue and bone. vol. 5; 2002. Available from: <https://publications.iarc.fr/Book-And-Report-Series/Who-Classification-Of-Tumours/Pathology-And-Genetics-Of-Tumours-Of-Soft-Tissue-And-Bone-2002>.
- Mccuiston A, Bishop JA. Usefulness of NKX2.2 immunohistochemistry for distinguishing Ewing sarcoma from other sinonasal small round blue cell tumors. *Head Neck Pathol.* 2018;12(1):89–94. doi:10.1007/s12105-017-0830-1.
- Cin PD, Qian X, Cibas ES. The marriage of cytology and cytogenetics. *Cancer Cytopathol.* 2013;121(6):279–90. doi:10.1002/ency.21270.
- Iwamoto Y. Diagnosis and treatment of Ewing's sarcoma. *J Clin Oncol.* 2007;37(2):79–89.
- Penmaraju G, Parab A, Singh A. Radiation treatment in a rare case of sinonasal ewing's sarcoma: A case report. *J Radiat Cancer Res.* 2020;11(3):115–9.

#### Author biography

**Geethamala K**, Assistant Professor

**Meena N Jadhav**, Associate Professor

**Sneha K**, Senior Resident

**Nirmala BL**, Senior Resident

**Rekha M Haravi**, Associate Professor and HOD

**Shirish Patil**, Senior Resident

**Cite this article:** Geethamala K, Jadhav MN, Sneha K, Nirmala BL, Haravi RM, Patil S. Sino-nasal and pharyngeal mass- Immunohistochemistry cuts the gordian knot. *IP J Diagn Pathol Oncol* 2022;7(4):244-247.