

Content available at: <https://www.ipinnovative.com/open-access-journals>

IP Journal of Diagnostic Pathology and Oncology

Journal homepage: <https://www.jdpo.org/>

## Original Research Article

## Histopathological study of lesions of appendix

Yasmin Altaf Momin<sup>1</sup>, Alka Vikas Gosavi<sup>1</sup>, Aasawari Arun Waje<sup>2</sup>,  
Samrin Fatima Siraj Khan<sup>1,\*</sup><sup>1</sup>Dept. of Pathology, Government Medical College, Miraj, Maharashtra, India<sup>2</sup>Dr. R. N. Cooper Municipal General Hospital, Mumbai, Maharashtra, India

## ARTICLE INFO

## Article history:

Received 31-10-2022

Accepted 16-12-2022

Available online 14-01-2023

## Keywords:

Chronic appendicitis

LAMN

## ABSTRACT

**Introduction:** The human appendix is a supposedly functionless organ, but can cause morbidity and mortality because it is likely to be infected. Acute Appendicitis being the most common surgical emergency. Appendectomy specimens from suspected acute appendicitis often appear macroscopically normal but histological analysis reveal a more sinister underlying pathology.

A three year study was performed to determine the incidence of various non-neoplastic and neoplastic lesions of appendix.

**Aim:** To study the histopathology of various lesions of appendix.

**Materials and Methods:** It is a retrospective study for a period of three years at Tertiary care hospital. The histopathological reports and clinical details were collected and slides were reviewed and evaluated. Special stains were used wherever required.

**Results:** The study included 1092 cases of lesions of appendix. The commonest lesion was chronic non-specific appendicitis (48.27%) followed by acute appendicitis with (47.80%). Other non neoplastic lesions found were fibrous obliteration of appendix (2.10%), chronic appendicitis with *Enterobius vermicularis* infestation (0.83), tuberculosis (0.18), xanthogranulomatous appendicitis (0.09%) and amoebic appendicitis (0.09%). Neoplastic lesions seen were low grade mucinous neoplasm (0.18) and serrated adenoma (0.09).

**Conclusion:** Chronic non-specific appendicitis is the commonest appendiceal lesion. The various lesions of appendix clinically present as acute or chronic appendicitis but histology reveals the true nature of the lesion and hence remains the gold standard method.

This is an Open Access (OA) journal, and articles are distributed under the terms of the [Creative Commons Attribution-NonCommercial-ShareAlike 4.0 License](https://creativecommons.org/licenses/by-nc-sa/4.0/), which allows others to remix, tweak, and build upon the work non-commercially, as long as appropriate credit is given and the new creations are licensed under the identical terms.

For reprints contact: [reprint@ipinnovative.com](mailto:reprint@ipinnovative.com)

## 1. Introduction

The appendix also known as true caecal apex, is named on account of its worm-like appearance. Evidence suggests that removal has no obvious ill effects.<sup>1</sup> Acute inflammation of vermiform appendix is the commonest cause of acute abdomen.<sup>2</sup> Importance of histopathological examination lies in unsuspected diagnosis that have a significant bearing on outcome and prognosis.<sup>3</sup> With this view in mind,

the study was carried out to assess the value of routine histopathological examination of all surgically resected appendices.

## 2. Materials and Methods

The present study was carried out at our institute, over a span of 3 years i.e. (1st July 2016 to 30th June 2019). All the specimens of appendix of patients irrespective of age and sex were included in present study. In each case, gross findings including external examination for presence

\* Corresponding author.

E-mail address: [samrinhanshagufta2@gmail.com](mailto:samrinhanshagufta2@gmail.com) (S. F. S. Khan).

of exudate, perforation, dilatation, obstruction was done. One transverse and one longitudinal section were given in each case. The cut section was observed for luminal patency, presence of mucus and worms. Both the transverse as well as longitudinal sections were submitted for histopathology. The formalin fixed, paraffin embedded tissue blocks were cut using rotatory microtome and sections were stained with hematoxylin and eosin. The stained sections were examined by light microscopy. The histopathological findings were correlated with the clinical parameters.

### 3. Results

In this study, 1092 cases were studied. Appendectomy specimens constituted approximately 13.43% of all specimens. Table 1 shows frequency distribution of lesions of appendix according to histopathology.

#### 3.1. Chronic non-specific appendicitis

Table 2 represents Age and sex distribution of cases of chronic appendicitis. Chronic non-specific appendicitis was most commonly seen in the age group of 11-30 years with female preponderance. Most of the patients presented with complaints of pain and tenderness in right iliac fossa and in few patients there was no tenderness.

On gross examination of 523 cases, 381 showed congestion (Figure 1 ) and 142 were unremarkable. On microscopic examination, appendix showed hyperplastic lymphoid follicles with prominent germinal centers in the submucosa (Figure 1b) The wall of appendix showed infiltration by lymphocytes & plasma cells (Figure 1c)

#### 3.2. Acute appendicitis

Table 3 shows Distribution of cases of acute appendicitis. Out of 522 cases of acute appendicitis, most commonly encountered cases were of acute appendicitis with or without periappendicitis (63.79%) followed by acute appendicitis with perforation peritonitis (35.44%). Table no. 4 shows age and sex distribution of cases of acute appendicitis with or without periappendicitis. Most of the cases of acute appendicitis with or without periappendicitis were seen in the age group of 21-30 years (39.63%) with slight male preponderance.

Acute appendicitis with perforation peritonitis (35.44%) was more common in the age group of 0-10 years and 71-80 years and was more frequent in males. The patients presented with complaints of fever, nausea, vomiting and right iliac fossa pain. On gross examination of 522 specimens most of the appendices were swollen and turgid. In 26 cases the external surfaces were covered with exudate and 62 showed sealed off perforation (Figure 2a) which were in the range 0.5-1.5cm and 1-2 cms away from the tip. On microscopic examination the mucosa showed ulceration and the wall of the appendix showed diffuse and

dense infiltration by polymorphs and mononuclear cells. In cases of acute appendicitis with perforation peritonitis microscopic examination revealed areas of myonecrosis along with above findings (Figure 2b).

#### 3.3. Other non-neoplastic lesions

##### 3.3.1. Fibrous obliteration of appendix

We encountered 23 cases (2.10%) of fibrous obliteration of appendix more commonly seen in the age group of 31-40 years and showed female preponderance. Grossly, all the 23 cases showed obliterated lumen. On microscopic examination, appendix showed obliteration of the lumen by fibrous tissue along hypertrophied nerve bundle.

##### 3.3.2. Chronic appendicitis with *Enterobius Vermicularis* infestation

Seven cases out of nine were clinically diagnosed as acute appendicitis. However histopathology showed chronic appendicitis with *Enterobius vermicularis* infestation. Out of all 9 cases, 6 appendices were congested on external examination and 3 were unremarkable. All had a patent lumen and none of them showed evidence of *E. vermicularis* grossly. On microscopy, in all cases the parasite was luminal (Fig. 3) and one of the case also showed eggs in the lumen. 8 cases out of 9 were associated with chronic appendicitis.

##### 3.3.3. Tuberculosis of appendix

Two cases (0.18%) were reported as Granulomatous appendicitis- Appendiceal tuberculosis. A 32-year female and a 46-year male clinically diagnosed as acute appendicitis, grossly showed dark brown appearance. Microscopically both the appendices showed granulomas composed of epithelioid cells, histiocytes, Langhan's type of giant cells and diffuse and dense infiltration by mononuclear cells with foci of caseous necrosis. (Figure 4 a & b). Ziehl Neelsen stain showed Acid Fast Bacilli.

##### 3.3.4. Xanthogranulomatous appendicitis

A single case (0.09%) was reported in a 52-year old female clinically diagnosed as acute appendicitis. Appendix measured 5cm in length. The tip showed dark brown mass measuring 3.5x1.5x1.5 cm which was firm in consistency. Microscopy showed appendicular wall with diffuse and dense infiltration by polymorphs and mononuclear cells with a predominance of foamy histiocytes. (Figure 5). The periappendiceal tissue showed extensive areas of fibrosis and foci of abscess formation.

##### 3.3.5. Amoebic appendicitis

We reported a single case (0.09%) of acute amoebic appendicitis in a 30-year-old female, who presented with abdominal pain, fever and chills. Blood investigations showed neutrophilic leukocytosis. Microscopy showed

extensive mucosal ulceration with luminal acute inflammatory exudate. The wall showed diffuse and dense infiltration by polymorphs, mononuclear cells with foci of myonecrosis and many trophozoite forms of *Entamoeba histolytica* in the exudate as well as throughout the wall. Some of the *Entamoeba histolytica* showed evidence of erythrophagocytosis. (Figure 6)

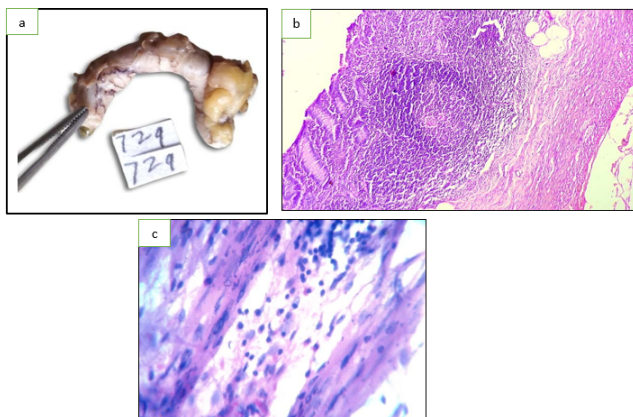
### 3.4. Neoplastic lesions

#### 3.4.1. Low grade mucinous neoplasm

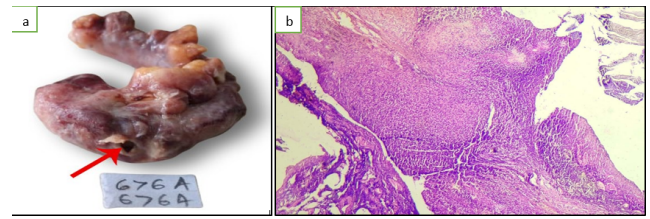
Two cases (0.18%) were reported as low grade mucinous neoplasm. A 69-year old male, clinically diagnosed as subacute appendicitis and the other a 77-year old male, clinically diagnosed as acute appendicitis. Grossly lumina of both the appendices were dilated and filled with mucin. (Figure 7a,b). On microscopic examination, the mucosa was lined by tall columnar epithelium with apical mucin and showed low grade dysplasia. The lamina propria showed pools of mucin which was seen dissecting the wall. (Figure 7c,d)

#### 3.4.2. Serrated adenoma

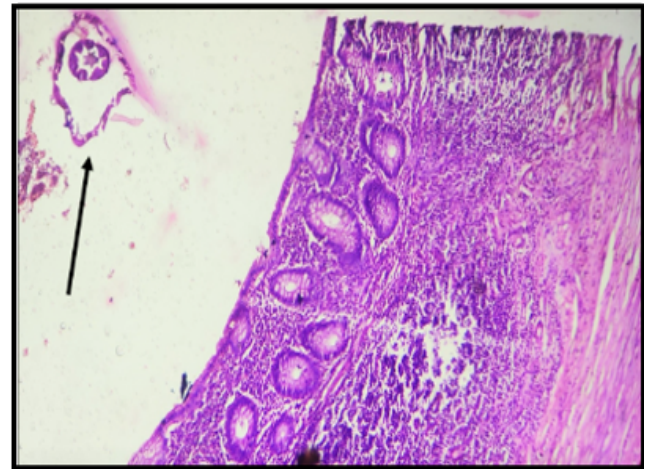
A single case (0.09%) of serrated adenoma in 46-year-old female who was clinically diagnosed as acute appendicitis was reported. Grossly the appendix was received in two pieces. Microscopic examination showed villous structures with irregularly branched crypts and dilatation at the base of crypts. There was no evidence of invasion and the muscularis mucosae were clearly intact. (Fig. 8a & 8b).



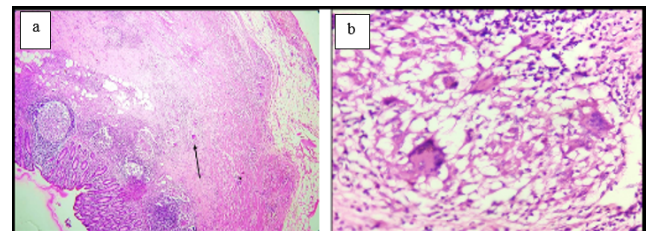
**Fig. 1:** **a:** Gross photograph of chronic appendicitis with congested serosal surface; **b:** Microphotograph of chronic appendicitis – showing focally denuded mucosa with submucosal hyperplastic lymphoid follicles (H & E, x10); **c:** High power view of chronic appendicitis-wall showing lymphoplasmacytic infiltrate (H & E, x40)



**Fig. 2:** **a:** Gross photograph of acute appendicitis with perforation peritonitis- appendix covered by exudate and showing perforation (arrow). (676/19); **b:** Microphotograph of acute appendicitis with perforation peritonitis- showing extensive mucosal ulceration and areas of myonecrosis. (H & E, x10)



**Fig. 3:** Microphotograph of chronic appendicitis with luminal *E. vermicularis* Infestation (arrow) (H & E, x10)



**Fig. 4:** **a:** Microphotograph of granulomatous inflammation suggestive of Tuberculosis showing multiple granulomas in the wall.(H&E, x 4) **b:** High power view of TB appendix-showing granulomas composed of epithelioid cells and Langhan's type of giant cells. (H & E, x40)

## 4. Discussion

### 4.1. Non-neoplastic lesions

The most common affliction was chronic non specific appendicitis (48.27%) followed by acute appendicitis (47.80%). Omotoso A J et al, 81 Kulkarni MP et al 69 reported frequency of chronic appendicitis as 48.0 % and 47.02% respectively, our study is comparable with these

**Table 1:** Frequency distribution of lesions of appendix according to histopathology

| S.No. | Histopathological Diagnosis                                   | No. of cases | Percentage    |
|-------|---|--------------|---------------|
|       | <b>Non-neoplastic lesions</b>                                 | <b>1089</b>  | <b>99.72%</b> |
| 1     | Chronic non-specific appendicitis                             | 527          | 48.27%        |
| 2     | Acute appendicitis  | 522          | 47.80%        |
| 3     | Fibrous obliteration of appendix                              | 23           | 2.10%         |
| 4     | Chronic appendicitis with Enterobius vermicularis infestation | 09           | 0.83%         |
| 5     | Tuberculosis  | 02           | 0.18%         |
| 6     | Xanthogranulomatous appendicitis                              | 01           | 0.09%         |
| 7     | Amoebic appendicitis  | 01           | 0.09%         |
| 8     | No specific lesion (NSL)                                      | 01           | 0.09%         |
| 9     | Autolysis   | 03           | 0.27%         |
|       | <b>Neoplastic lesions</b>                                     | <b>03</b>    | <b>0.27</b>   |
| 1     | Low grade mucinous neoplasm                                   | 02           | 0.18%         |
| 2     | Serrated adenoma  | 01           | 0.09%         |
|       | Total   | 1092         | 100           |

**Table 2:** Age and sex distribution of cases of chronic appendicitis

| Age   | Males | Females | Total | Percentage |
|-------|-------|---------|-------|------------|
| 0-10  | 6     | 10      | 16    | 3.05       |
| 11-20 | 56    | 81      | 137   | 26.19      |
| 21-30 | 86    | 124     | 210   | 40.16      |
| 31-40 | 46    | 46      | 92    | 17.59      |
| 41-50 | 20    | 18      | 38    | 7.27       |
| 51-60 | 09    | 10      | 19    | 3.64       |
| 61-70 | 01    | 06      | 07    | 1.34       |
| 71-80 | 01    | 03      | 04    | 0.76       |
| Total | 225   | 298     | 523   | 100        |

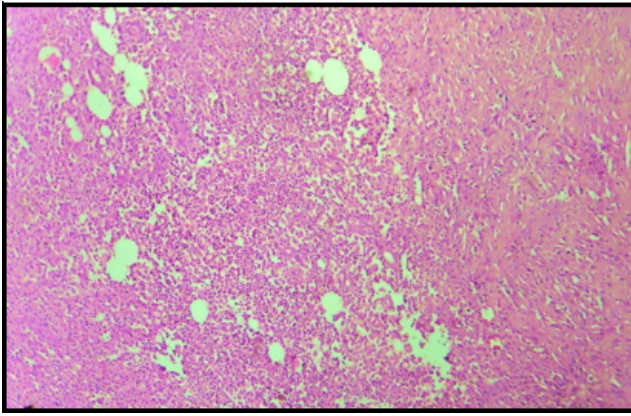
**Table 3:** Distribution of cases of acute appendicitis

| S.No. | Diagnosis   | No. of cases | Percentage for 522 cases | Percentage for 1092 cases |
|-------|---|--------------|--------------------------|---------------------------|
| 1     | Acute appendicitis with or without periappendicitis | 333          | 63.79                    | 30.50%                    |
| 2     | Acute appendicitis with perforation peritonitis     | 185          | 35.44                    | 16.94%                    |
| 3     | Acute gangrenous appendicitis                       | 04           | 0.77                     | 0.37                      |
|       | Total cases of acute appendicitis                   | 522          | 100                      |                           |
|       | Total cases studied                                 | 1092         |                          | 47.80%                    |

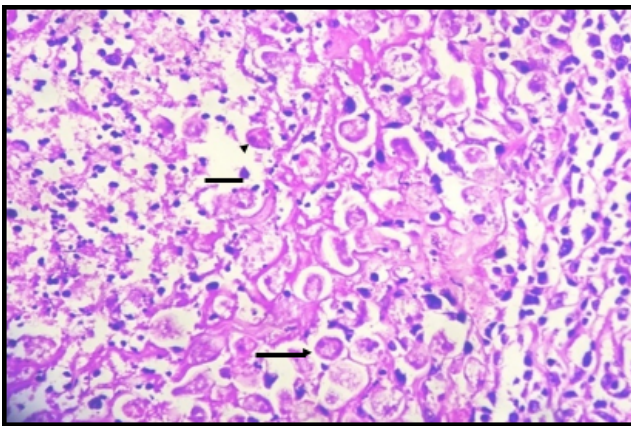
**Table 4:** Age and sex distribution of cases of acute appendicitis with or without periappendicitis

| Age   | Males | Females | Total | Percentage |
|-------|-------|---------|-------|------------|
| 0-10  | 08    | 5       | 13    | 3.90%      |
| 11-20 | 43    | 40      | 83    | 24.92%     |
| 21-30 | 74    | 58      | 132   | 39.63%     |
| 31-40 | 32    | 27      | 59    | 17.71%     |
| 41-50 | 21    | 4       | 25    | 7.50%      |
| 51-60 | 05    | 6       | 11    | 3.30%      |
| 61-70 | 02    | 4       | 6     | 1.80%      |
| 71-80 | 02    | 1       | 3     | 0.90%      |
| 81-90 | 0     | 1       | 1     | 0.30%      |
| Total | 187   | 146     | 333   | 100        |

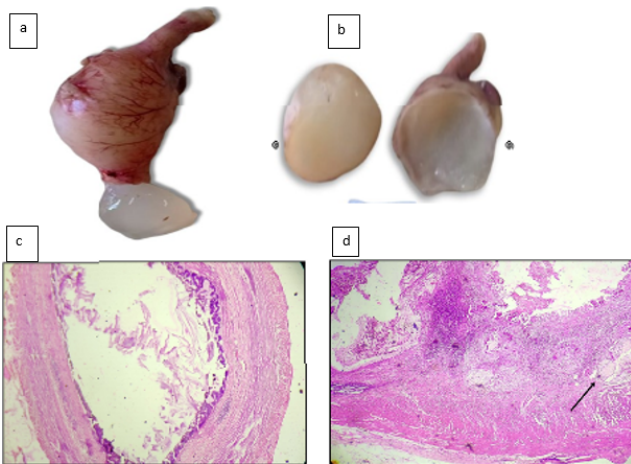




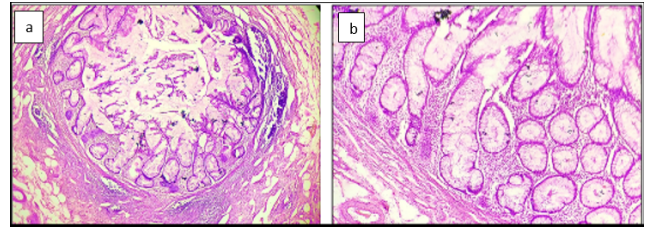
**Fig. 5:** Microphotograph of Xanthogranulomatous appendix-showing sheets of foamy histiocytes (H & E, x10)



**Fig. 6:** Microphotograph of amoebic appendicitis-showing *E.histolytica* with erythrophagocytosis. (Arrow) (H & E, x40).



**Fig. 7:** Gross photograph of low grade appendiceal mucinous neoplasm - Extremely distended appendix with mucin extruding out (a) & cut surface showing mucin (b). (c) Microphotograph of low power view-mucosa showing low grade dysplasia (H&E, x4) (d): Microphotograph showing pools of mucin dissecting the wall (arrow).



**Fig. 8:** a: Microphotograph of serrated adenoma-showing irregularly branched crypts and dilatation at the base of crypts, muscularis mucosa is intact. (H & E, x4); b: High power view of serrated adenoma-showing irregularly branched crypts and dilatation at the base of crypts. (H & E, x40)

studies. Criteria for diagnosis of chronic appendicitis were evidence of chronic inflammation with infiltration of the muscle coat & serosa by lymphocytes & plasma cells. Fibrosis, alone cannot be sufficient to make diagnosis of chronic appendicitis as the amount of fibrous tissue in the appendix normally increases with age, as the lymphoid tissue regresses.<sup>4</sup> Although not considered a surgical emergency, it is often a missed diagnosis with complications such as perforation or abscess formation. Computed tomography (CT) scan is considered to be the best test for diagnosis.<sup>5</sup>

Acute appendicitis with or without periappendicitis constituted second largest category in our study (30.50%), Makaju Ret al,<sup>6</sup> Mehmood N et al,<sup>7</sup> Nikumbh DB et al,<sup>8</sup> Patel M.M et al.<sup>9</sup> reported frequency of acute appendicitis as 34.75 %, 30.6 %, 38.2 % and 35.5 % respectively. Our study results are comparable with these studies. In our study, the perforation rate of 35.44% and is comparable to that reported by I Chamisa (34.0%).<sup>10</sup> However, several studies reported lower rates. Higher perforation rate in our study, may be due late visit in the hospital in most of the cases. We reported 4 cases of acute gangrenous appendicitis i.e. 0.37 % cases. The studies like Nikumbh DB et al,<sup>8</sup> Kulkarni MP et al,<sup>11</sup> and Elfaedy O et al.<sup>12</sup> reported the rates 0.4 %, 0.6%, and 0.6%. Our findings are comparable with these studies. However, Shrestha R et al<sup>9</sup> and Makaju R et al<sup>6</sup> reported it to be 18.7% and 16.99% respectively.

The obliterated appendix has been described under a plethora of terms such as Neurogenic appendicitis, Neuromatosis of the appendix, Neurogenic appendicopathy, Axial neuroma, and fibrous obliteration of appendix.<sup>13</sup> Appendiceal neuroma was described by P. Masson in an article published in American Journal of Pathology 2. In the article, he analyzed 1200 specimen of appendix that include normal and pathological specimens.<sup>14,15</sup> We reported 23 cases (2.10%) of fibrous obliteration of appendix and our findings are concordant with the results of studies like Yilmaz M et al<sup>16</sup> and Kulkarni MP et al.<sup>11</sup>

The pinworm *Enterobius vermicularis* is the most common parasite reported to be associated with appendicitis

estimated to affect up to 200 million people world wide.<sup>16</sup> The frequency of *E. vermicularis* infestation varies. It is higher in other studies. However, in our study it was 0.83 % and is comparable with the studies like Jones AE et al,<sup>3</sup> I Chamisa<sup>10</sup> and Emre A et al.<sup>17</sup> we reported 9 cases of *E. vermicularis* infestation, 7 were clinically diagnosed as acute appendicitis. *Enterobius vermicularis* is usually associated with eosinophilic infiltration and/or granuloma formation.<sup>17</sup> The presence of parasites in the appendix may cause appendiceal colic even without eliciting an acute inflammation. This colic due to a parasitic infestation is explained by the hypothesis of appendiceal lumen obstruction. The simple presence of *E. vermicularis* in the appendix usually produces symptoms which resemble acute appendicitis although the mechanism for this does not involve mucosal invasion by the parasite.<sup>18</sup>

We reported two cases (0.18%) of tuberculosis. Clinically one was diagnosed as acute appendicitis and other as perforation appendicitis. Various studies like AI- Fatah MA et al,<sup>19</sup> Nikumbh DB et al,<sup>8</sup> I Chamisa<sup>10</sup> and Makaju R et al.<sup>6</sup> quoted the frequency of 0.2%, 0.6% and 0.5%. Results of our studies are comparable with their findings.

Amoebic (*Entamoeba histolytica*) appendicitis is very rare, occurring in about 0.5% to 2% of acute appendicitis.<sup>20</sup> We reported a single case of acute amoebic appendicitis with a frequency of 0.09%. Other studies like I Chamisa<sup>10</sup> and Mandakini MP et al<sup>11</sup> reported frequency of 0.6% and 0.% respectively in their study.

Parasitic infestation by *Ascaris Lumbricoides*–associated appendicitis is likely a sequela of a high intestinal worm load, however, the presence of migrating *Ascaris* in the vermiform appendix can be seen as an incidental finding.

Xanthogranulomatous inflammation (XGI) is rare. The exact pathogenesis of XGI is not well known. It probably represents a chronic inflammatory process in which host and microorganism interact, that leads to tissue destruction and localized proliferation of macrophages containing large amounts of lipid, typically with bright yellow or golden yellow mass-like lesions associated with abscess cavities on macroscopic examination and characterized by presence of high number of foamy histiocytes admixed with lymphocytes and plasma cells and micro-abscesses. Differential diagnosis includes Malakoplakia containing foam cells.<sup>21</sup>

## 5. Neoplastic Lesions

In present study the frequency of neoplastic lesion was 0.27%. Mehmood N et al.<sup>7</sup> reported as 0.5%, Kulkarni MP et al.<sup>11</sup> as 0.6% and Nikumbh D.B. et al.<sup>8</sup> as 0.37 %. Our findings reported as are comparable with these studies.

Low-grade appendiceal mucinous neoplasm (LAMN) is a rare low grade malignancy accounting for 1% of gastrointestinal neoplasms found in less than 0.3%.

It is commonly an incidental finding during operative exploration and is often diagnosed late. LAMNs are associated with diverticula, herniations, dissections, and rupture. The most feared complication is seeding of mucin into the adjacent peritoneum, leading to pseudomyxoma peritonei associated with a high rate of mortality.<sup>22</sup> We reported 2 (0.18 %) cases of low grade mucinous neoplasm in span of 3 years. Al-Fatah MA et al<sup>19</sup> reported 3 cases in the study of 460 cases with frequency of 0.7%.

Serrated and villous adenomas of the appendix appear to be highly aggressive lesions more aggressive than similar colonic and rectum adenomas. More recently Carr et al postulated that the precursor lesion in tumours of the appendix is probably a villous or a serrated adenoma. An adenoma has crenated, sawtooth-like structural changes in the dysplastic epithelium covering the basal aspect of the crypts of Lieberkuhn, as a result of epithelial infolding. When serrated fronds are present in more than 50% of the dysplastic structures, the adenoma is classified a serrated adenoma. The remaining adenomatous tissue usually shows metaplastic or villous structures. Recently Bariol et al reported that the diagnosis of serrated adenoma of the colon and rectum should include lesions having serrated structures in > 20% of the dysplastic crypts.<sup>23</sup> Single case (0.09%) of serrated adenoma was reported in our study. However, Kulkarni M.P et al.<sup>11</sup> found one case (0.22%) of adenoma out of 436 cases. Ma K.W et al.<sup>24</sup> reported single case of tubular adenoma in 1492 cases. Yilmaz M et al.<sup>16</sup> also reported single case of adenomatous polyp out of 1621 cases. Our study findings are concordant with these studies.

## 6. Conclusion

It is not only interesting, but humiliating fact that such a small organ with no known useful function; can so frequently be a cause of nuisance, which if neglected and not treated promptly may even give rise to fatal complications. Although neoplastic lesions constitute a very small portion of appendiceal lesions, they clinically simulate acute appendicitis. Hence histopathological examination remains the gold standard method. It not only serves the purpose of confirmation of clinical diagnosis but also discloses unusual findings that may not have been suspected clinically nor evident on gross examination. This additional information helps in subsequent clinical management of patients such as anti-helminthic treatment and endoscopic gastro-enterology follow up.

## 7. Conflict of Interest

The authors declare that they have no conflict of interest.

## 8. Source of Funding

None.

## References

- Theobald D. The vestigiality of the human vermiform appendix: A modern reappraisal; 2007. Available from: <http://www.talkorigins.org/faqs/vestigial/appendix.html#:~:text=In%20evolutionary%20discussions%20the%20human,an%20ancestor%20than%20at%20present..>
- Connell PO. The vermiform appendix. In: Willams N, Bulstrode C, editors. Bailey and Love's Short Practice of Surgery. Hodder Arnold; 2008. p. 1204–8.
- Jones AE, Phillips AW, Jarvis JR, Sargen K. The Value of routine histopathological examination of appendectomy specimens. *BMC Surg.* 2007;7:17. doi:10.1186/1471-2482-7-17.
- Morsion BC. The appendix. In: Symmers WSC, editor. Systemic Pathology by Thirtyeight, Alimentary system. vol. 3. Churchill Livingstone; 1978. p. 1168–78.
- Kothadia JP, Katz S, Ginzburg L. Chronic appendicitis: uncommon cause of chronic abdominal pain. *Therap Adv Gastroenterol.* 2015;8(3):160–2.
- Makaju R, Mohammad A, Shakya A. Acute appendicitis: Analysis of 518 histopathologically diagnosed cases at the Kathmandu University Hospital. *Kathmandu Univ Med J (KUMJ).* 2010;8(30):227–30. doi:10.3126/kumj.v8i2.3564.
- Mehmood N, Mushtaq H, Alam S. Histopathological Analysis of Cases Presenting with Acute Appendicitis. *J Islamabad Med Dent Coll.* 2014;3(1):11–4.
- Nikumbh DB, Thakur RY, Singhavi S, Gondane S. Histopathological Analysis of unusual Findings in Appendectomy Specimens: A Retrospective Study and Literature Review. *Ann Pathol Lab Med.* 2016;3(3):224–9.
- Shrestha R, Ranabhat SR, Tiwari M. Histopathologic analysis of appendectomy specimens. *J Pathol Nepal.* 2012;2(3):215–9.
- Chamisa I. A clinicopathological review of 324 appendices removed for acute appendicitis in Durban, South Africa: a retrospective analysis. *Ann R Coll Surg Engl.* 2009;91(8):688–92. doi:10.1308/003588409X12486167521677.
- Kulkarni MP, Sulhyan KR, Barodawala SM. Histopathological study of lesions of appendix. *Int J Health Sci Res.* 2017;7(4):90–5.
- Elfaedy O, Benkhadoura M, Elshaikhy A, Elgazwi K. Impact of routine histopathological examination of appendectomy specimens on patient management: a study of 4012 appendectomy specimens. *Turk J Surg.* 2019;35(3):196–201.
- Olson BS, Holck S. Neurogenous hyperplasia leading to appendical obliteration: an immunohistochemical study of 237 cases. *Histopathology.* 1987;11(8):843–9. doi:10.1111/j.1365-2559.1987.tb01887.x.
- Hairon SM. A case of appendiceal neuroma (fibrous obliteration of appendix). *Br J Med Health Res.* 2016;16(3):54–8.
- Masson P. Carcinoids (argentaffin- cell tumors) and nerve hyperplasia of the appendicular mucosa. *Am J Pathol.* 1928;4(3):181–212.
- Yilmaz M, Akbulut S, Kutluturk K, Sahin N, Arabaci E, Ara C, et al. Unusual histopathological findings in appendectomy specimens from patients with suspected acute appendicitis. *World J Gastroenterol.* 2013;19(25):4015–22.
- Emre A, Akbulut S, Bozdag Z, Kanlioz M, Emre R, Sahin N, et al. Routine histopathologic examination of appendectomy specimens: retrospective analysis of 1255 patients. *Int Surg.* 2013;98(4):354–62. doi:10.9738/INTSURG-D-13-00098.1.
- Efraimidou E, Gatopoulou A, Stamos C, Lirantzopoulos N, Kouklakis G. Enterobius vermicularis infection of the appendix as a cause of acute appendicitis in a Greek adolescent: a case report. *Cases J.* 2008;1(1):376. doi:10.1186/1757-1626-1-376.
- Al-Fatah MA. Importance of histopathological evaluation of appendectomy specimens. *Al-Azhar Assiut Med J.* 2017;15(2):97–103.
- Hegazi MA, Patel TA. Acute amoebic appendicitis: case reports and review of parasitic appendicitis. *J Pediatric Infect Dis Soc.* 2013;2(1):80–2.
- Singh V, John KM, Malik A, Pareek T, Dutta V. Xanthogranulomatous appendicitis: Uncommon histological variant of a common entity. *Med J Armed Forces India.* 2015;71(1):19–21. doi:10.1016/j.mjafi.2012.11.003.
- Gonzalez HH, Herard K, Mijares MC. A rare case of low-grade appendiceal mucinous neoplasm: a case report. *Cureus.* 2019;11(1):e3980. doi:10.7759/cureus.3980.
- Rubio CA. Serrated adenomas of the appendix. *J Clin Pathol.* 2004;57(9):946–9.
- Ma KW, Chia NH, Yeung HW, Cheung MT. If not appendicitis, then what else it can be? A retrospective review of 1492 appendectomies. *Hong Kong Med J.* 2010;16(1):12–7.

## Author biography

**Yasmin Altaf Momin**, Associate Professor

**Alka Vikas Gosavi**, Professor

**Aasawari Arun Waje**, Specialist Medical

**Samrin Fatima Siraj Khan**, Junior Resident

**Cite this article:** Momin YA, Gosavi AV, Waje AA, Khan SFS. Histopathological study of lesions of appendix. *IP J Diagn Pathol Oncol* 2022;7(4):233-239.