

Content available at: <https://www.ipinnovative.com/open-access-journals>

IP Journal of Diagnostic Pathology and Oncology

Journal homepage: <https://www.jdpo.org/>

## Case Series

# Nevus lipomatosis cutaneous superficialis (NLCS) - A case series of four cases of this rare dermal anomaly in a tertiary care centre

Monica Puri<sup>1</sup>, Neelam Gupta<sup>1,\*</sup>

<sup>1</sup>Dept. of Pathology, M. M. Medical College and Hospital, Kumarhatti Solan, Himachal Pradesh, India



## ARTICLE INFO

### Article history:

Received 30-06-2022

Accepted 12-08-2022

Available online 22-09-2022

### Keywords:

Rare

Idiopathic

Benign

## ABSTRACT

Nevus lipomatosis cutaneous superficialis is a rare benign idiopathic dermal anomaly having a good prognosis after excision. Here we are reporting a case series of four cases of nevus lipomatosis cutaneous superficialis to raise recognition of this rare disease.

This is an Open Access (OA) journal, and articles are distributed under the terms of the [Creative Commons Attribution-NonCommercial-ShareAlike 4.0 License](https://creativecommons.org/licenses/by-nc-sa/4.0/), which allows others to remix, tweak, and build upon the work non-commercially, as long as appropriate credit is given and the new creations are licensed under the identical terms.

For reprints contact: [reprint@ipinnovative.com](mailto:reprint@ipinnovative.com)

## 1. Introduction

Nevus lipomatosis cutaneous superficialis (NLCS) is a rare benign idiopathic dermal anomaly and was first reported by Hoffmann and Zurhelle in 1921 as pedunculated lipofibroma.<sup>1</sup> Commonly they present at birth or within the first 3 decades of life but solitary form have a later onset in life. There is no hereditary predisposition or sex predilection of this disease.<sup>2</sup> Clinically it occurs in two forms namely 1) classical and 2) solitary. Classical form is most frequent form with common presentation over pelvic-girdle area and manifests as clusters of multiple, pedunculated, yellowish or skin-colored, soft, non - tender, cerebriform, papules or nodules which may coalesce to form large plaques.<sup>2,3</sup> The second form is the solitary form which is rare and normally presents as a solitary dome-shaped papule or nodule with no specific site distribution.<sup>4,5</sup> Histologically, it is characterized by ectopic mature adipocytes within the upper dermis with no connection to underlying subcutaneous fat.<sup>2,6</sup>

We report here 4 cases of NLCS to raise recognition of this rare disease.

\* Corresponding author.

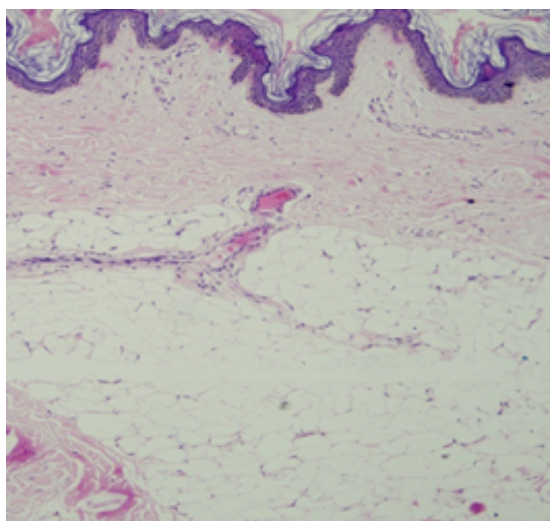
E-mail address: [neelamgupta353@gmail.com](mailto:neelamgupta353@gmail.com) (N. Gupta).

## 2. Case 1

A 41 year old male presented to surgery outpatient department with a single swelling at left arm and provisional diagnosis of sebaceous cyst was made. An excisional biopsy was done. Grossly two firm to hard tissue pieces largest measuring 2.2x1.6x0.6 cm were received in histopathology department. Microscopic examination shows keratinized stratified squamous epithelium revealing hyperkeratosis, acanthosis and occasional horn cysts. Papillary and mid dermis shows the presence of mature adipose tissue embedded in the collagen bundles. Reticular dermis was unremarkable. On account of above histopathological features the diagnosis of Nevus lipomatosis superficialis was given.

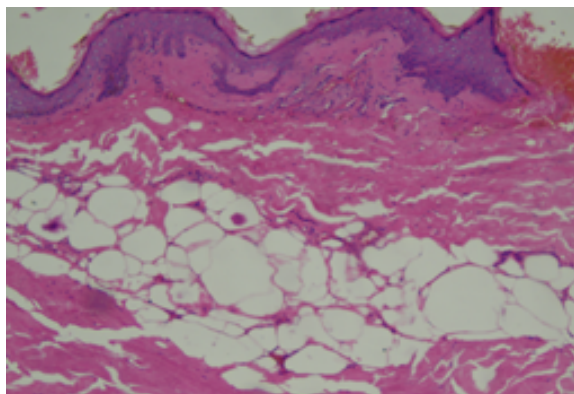
## 3. Case 2

A 50 years female presented to surgery outpatient department with a single swelling at right thigh and provisional diagnosis of lipoma was made. An excisional biopsy was done. Grossly a single skin covered globular mass with fatty tissue measuring 1.0x1.5x0.6 cm was received in histopathology department. On cut open yellowish white areas were seen. Microscopic examination



**Fig. 1:** H & E Stain, 40x, Keratinized stratified Squamous epithelium with papillary dermis showing mature adipose tissue.

shows a tumor lined by keratinized stratified squamous epithelium with basket weave appearance of stratum corneum, thinning of epidermis and loss of rete ridges. Papillary dermis shows moderate to marked lymphocytic infiltrate. Papillary dermis was replaced by mature adipose tissue. Hair follicles, eccrine ducts and glands, smooth muscles and collagen bundles also noticed within the dermis. In addition, focal areas show fat necrosis. On account of above histopathological features the diagnosis of Nevus lipomatosis superficialis was given.

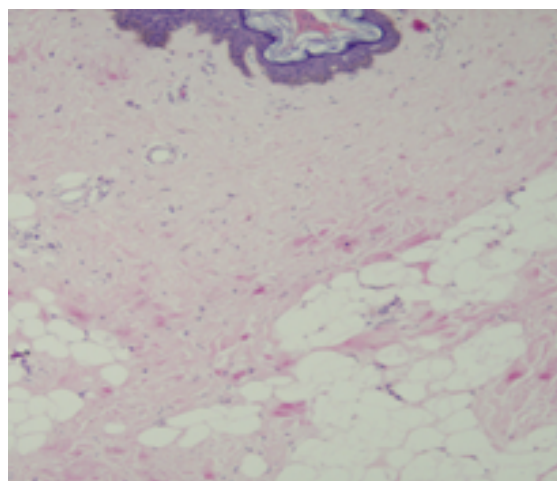


**Fig. 2:** H & E Stain, 40x, Keratinized stratified Squamous epithelium with papillary dermis showing mature adipose tissue.

#### 4. Case 3

A 29 years old girl presented to dermatology department with a soft pedunculated growth of size 3.0x1.0 cm at anterior surface of left thigh since 4 to 5 years. No family history of similar complaint was present. An excisional biopsy was done. Grossly a single skin covered firm

tissue piece measuring 2.0x1.6x0.6cm was received in histopathology department with differentials of skin tag, nevus lipomatosis and warts. Microscopic examination shows keratinized stratified squamous epithelium revealing basket weave appearance of stratum corneum, follicular plugging, mild acanthosis and increased melanin pigment in the basal layer. Throughout dermis shows lobules of mature adipocytes separated by collagen fibres. On account of above histopathological features the diagnosis of Nevus lipomatosis superficialis was given after exclusion of other differentials.



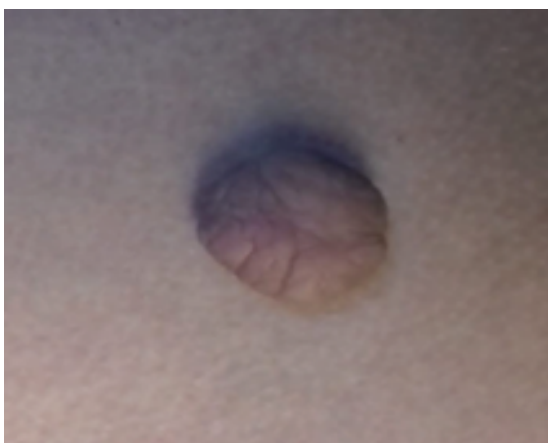**Fig. 3:** H & E Stain, 40x, Keratinized stratified Squamous epithelium with papillary dermis showing mature adipose tissue.

#### 5. Case 4

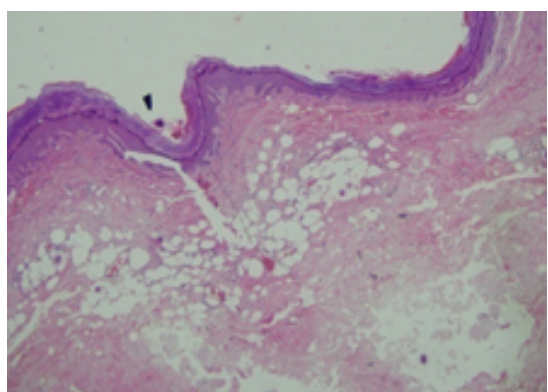
A 30 years female presented to surgery outpatient department with a single swelling with stalk over back and provisional diagnosis of papilloma was made. An excisional biopsy was done. Grossly a single skin covered globular multilobulated mass with fatty tissue measuring 1.8x1.5x0.8 cm was received in histopathology department. On cut open yellowish white areas were seen. Microscopic examination shows a polypoidal lesion covered by atrophic stratified squamous epithelium with basket weave appearance of stratum corneum, Papillary and reticular dermis shows variably sized lobules of mature adipose tissue. On account of above histopathological features the diagnosis of Nevus lipomatosis superficialis was given.

#### 6. Discussion

Nevus lipomatosus superficialis is an idiopathic benign cutaneous anomaly with a rare occurrence having two clinical forms namely 1) classical Hoffmann-Zurhelle form and 2) solitary form.<sup>1</sup> Triki et al (Tunisia, 2006) noticed an increased prevalence of the solitary form<sup>3</sup> which frequently develops as a single nodule after 20 years of age having



**Fig. 4:** Gross micrograph of nevus lipomatosus superficialis on the upper back



**Fig. 5:** H & E Stain, 40x, Keratinized stratified Squamous epithelium with papillary dermis showing mature adipose tissue.

no sites of predilection and has been demonstrated on the arms, face, nose, knees, calf, ears, clitoris, axillae and scalp.<sup>2,4–8</sup> The classical form/Hoffmann-Zurhelle form occurring at birth or first 3 decades of life<sup>2,7,9</sup> presents as unilateral clusters of multiple, soft, pedunculated-cerebriform, yellow/skin colored papular or nodular lesion which usually coalesce forming plaque. They are most commonly seen on the pelvic girdle area with a zonal pattern.<sup>2,3</sup>

All the patients in these case series of four cases typically had a solitary form with single nodular lesion on the left arm, right thigh and left thigh respectively. The differential diagnosis for this condition includes skin tag (papillomas), connective tissue nevus, plexiform neurofibroma, vascular malformation, nevus sebaceous and lipoblastomatosis.

All these 4 cases had a provisional diagnosis of sebaceous cyst, lipoma, skin tag/warts and papilloma respectively and final diagnosis of nevus lipomatosus

superficialis was made by histopathological examination which helped in distinguishing this condition from rest of the differentials.

## 7. Conclusion

As nevus lipomatosus superficialis is an idiopathic rare benign cutaneous condition requiring an expertise - first, to suspect this benign condition and secondly histopathological examination is must to reach a diagnosis. Excision is the ultimate cure for this condition with minimal chances of recurrence.

## 8. Conflict of Interest

The authors declare no relevant conflicts of interest.

## 9. Source of Funding

None.

## References

- Hoffman E, Zurhelle E. Uber einen Naevus lipomatodescutaneous superficialis der linken Gilutaaegend. *Arch Derm Syphilol*. 1921;130(1):327–33.
- Goucha S, Khaled A, Zéglou F, Rammeh S, Zermani R, Fazaa B. Nevus lipomatosus cutaneous superficialis: report of eight cases. *Dermatol Ther (Heidelb)*. 2011;1(2):25–30.
- Triki S, Mekni A, Haouet S, Mokni M, Kchir N, Dhahri ABO, et al. Nevus lipomatosus cutaneous superficialis: a clinico-pathological study of 13 cases. *Tunis Med*. 2006;84(12):800–2.
- Dotz W, Prioleau PG. Nevus lipomatosus cutaneous superficialis. *Arch Dermatol*. 1984;120(3):376–9.
- Jones EW, Marks R, Pongsehiron D. Naevus superficialis lipomatosus. A clinicopathological report of twenty cases. *Br J Dermatol*. 1975;93(2):121–33.
- Abel R, Dougherty JW. Naevus lipomatosus cutaneous superficialis (Hoffmann-Zurhelle). *Arch Dermatol*. 1962;85(4):524–6.
- Knuttel R, Silver EA. A cerebriform mass on the right buttock. *Dermatol Surg*. 2003;29(7):780–1.
- Ioannidou DJ, Stefanidou MP, Panayiotides JG, Tosca AD. Nevus lipomatosus cutaneous superficialis (Hoffmann-Zurhelle) with localized scleroderma like appearance. *Int J Dermatol*. 2001;40(1):54–7.
- Buch AC, Panicker NK, Karve PP. Solitary nevus lipomatosus cutaneous superficialis. *J Postgrad Med*. 2005;51(1):47–8.

## Author biography

**Monica Puri**, Senior Resident

**Neelam Gupta**, Professor and HOD

**Cite this article:** Puri M, Gupta N. Nevus lipomatosus cutaneous superficialis (NLCS) - A case series of four cases of this rare dermal anomaly in a tertiary care centre. *IP J Diagn Pathol Oncol* 2022;7(3):207-209.