

Content available at: <https://www.ipinnovative.com/open-access-journals>

IP Journal of Diagnostic Pathology and Oncology

Journal homepage: <https://www.jdpo.org/>

## Case Report

# Osteosarcoma with co-existent asymptomatic microfilaria-A rare cytological impression

Fauzia Talat Ekram<sup>1</sup>, Syeda Iqra Usman<sup>1</sup>, Fatma Lubna<sup>1</sup>, Kafil Akhtar<sup>1,\*</sup>

<sup>1</sup>Dept. of Pathology, Jawaharlal Nehru Medical College, AMU, Aligarh, Uttar Pradesh, India



### ARTICLE INFO

#### Article history:

Received 18-03-2022

Accepted 03-05-2022

Available online 19-05-2022

#### Keywords:

Cytology

Microfilaria

Osteosarcoma

Femur

### ABSTRACT

Filariasis is a major public health problem in developing countries, and the diagnosis is conventionally made by demonstrating microfilariae in the peripheral blood smear. However, microfilariae have been incidentally detected in fine needle aspirates of various lesions in clinically unsuspected cases of filariasis with absence of microfilariae in the peripheral blood. Microfilariae in cytological smears of malignant neoplasms is a chance finding. Cytology can be an effective tool for detection of asymptomatic filariasis and malignancy, thus helping in disease eradication and mortality. There are reports of coexistence of microfilaria with Ewing's sarcoma, squamous cell carcinoma of maxillary antrum and dentigerous cyst by different cytopathologists. Here we present a rare case of microfilariae in a cytological aspirate smear from left knee swelling with a malignant osteogenic tumor, osteosarcoma.

This is an Open Access (OA) journal, and articles are distributed under the terms of the [Creative Commons Attribution-NonCommercial-ShareAlike 4.0 License](https://creativecommons.org/licenses/by-nc-sa/4.0/), which allows others to remix, tweak, and build upon the work non-commercially, as long as appropriate credit is given and the new creations are licensed under the identical terms.

For reprints contact: [reprint@ipinnovative.com](mailto:reprint@ipinnovative.com)

## 1. Introduction

Filariasis is a major public health problem in India and microfilaria is sometimes seen during routine fine needle aspiration cytology (FNAC) smears, but it is very rare to find microfilaria coexistent with neoplastic lesions. It is rarely seen in association with malignant osteogenic tumor, osteosarcoma.<sup>1</sup>

Osteosarcoma is the most common type of malignant bone cancer, common in the metaphysis of proximal humerus, distal femur and proximal tibia.<sup>2</sup> The most common complaints are excruciating pain that may worsen at night and swelling. There is a history of fracture in a few cases. Treatment modality is surgery, chemotherapy, radiation therapy and cryosurgery.<sup>3</sup>

Lymphatic filariasis is endemic in the Indian states of Bihar, Jharkhand, West Bengal, Uttar Pradesh, Orissa, Kerala, Gujarat and South-East Asia.<sup>4</sup> It is caused by

*Wuchereria Bancrofti* which is transmitted by the bite of various mosquitoes as a vector. The most common presentation of the disease is asymptomatic, subclinical microfilaraemia, hydrocele, acute adeno-lymphangitis (ADL) and chronic lymphatic disease.<sup>5</sup>

Detection of microfilaria is infrequently reported during cytological evaluation of various lesions or body cavity fluids.<sup>6</sup> To find microfilariae in cytological smears of malignant bony neoplasms is a chance finding. Cytology can be an effective tool for detection of asymptomatic filariasis and help in disease eradication.<sup>4</sup> Here we present a rare case of microfilariae in a cytology aspirate smear from left knee swelling with a malignant osteogenic tumor, osteosarcoma.

## 2. Case Report

A 17 years old male, presented to the Orthopaedics outpatient department with complaints of mild pain in the left knee after playing football. The pain was progressive in nature, intermittent and worsened at night. It was

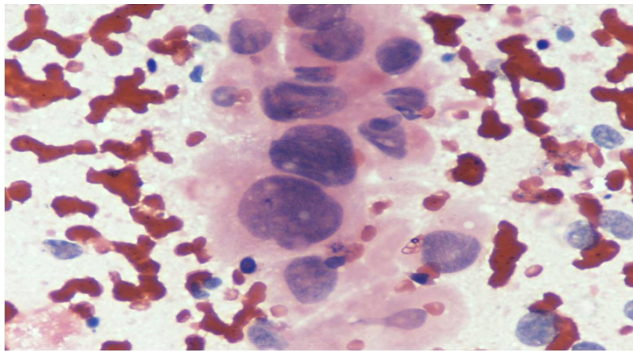
\* Corresponding author.

E-mail address: [drkafilakhtar@gmail.com](mailto:drkafilakhtar@gmail.com) (K. Akhtar).

accompanied by marked swelling and loss of considerable motion of the knee joint after a week.

On examination, the left knee was enlarged diffusely, firm and tender. No regional lymph nodes were palpable. Routine examination of chest, cardiovascular and abdomen was normal. Left knee radiograph showed an ill-defined osteolytic lesion in the metaphysis of femur, with focal osteoblastic and periosteal reaction with soft tissue extension. MRI of left thigh showed an intermediate intensity signal of ossified solid components on T1, with high signal intensity of soft tissue components on T2, suggestive of a malignant lesion.

Cytology smear from the knee mass showed cohesive clusters and singly scattered pleomorphic round to polygonal cells with abundant reddish granular cytoplasm and osteoid formation. The nuclei showed moderate to marked anisonucleosis, with coarse clumped chromatin and prominent nucleoli. Multinucleated giant cells were seen at places. (Figure 1).



**Fig. 1:** Cytology smear showed clusters and singly scattered tumor cells with moderate to marked nuclear enlargement, with coarse chromatin and prominent nucleoli and eosinophilic cytoplasm with osteoid formation. Haematoxylin and Eosin x 40X.

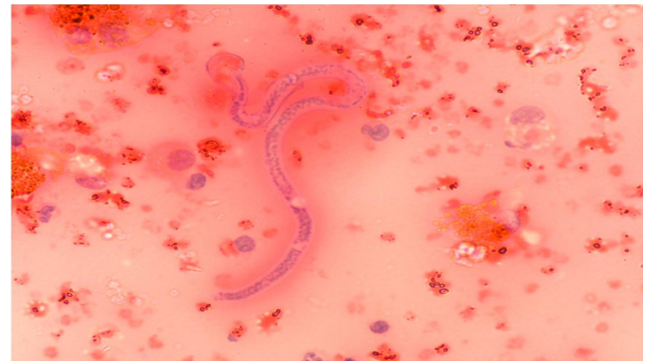Background smear showed multiple microfilarial parasites with sheath and somatic nuclei admixed with eosinophils, polymorphs and necrotic debris (Figure 2).

The patient was prescribed Diethylcarbamazine, 2mg per kg body weight thrice daily for 14 days.

Debridement of the bony mass was performed with involved soft tissues with bone grafting. Our patient is doing well after 6 months of follow up.

### 3. Discussion

Lymphatic filariasis is a public health problem and is considered eradicable or potentially eradicable disease by international task force for disease eradication.<sup>5</sup> Diagnosis in patients presenting with typical clinical presentation is often easy. But majority of the affected cases remain asymptomatic and continue to transmit the disease. Therefore, microfilariae even in asymptomatic cases can reach tissue spaces due to vascular or lymphatic obstruction,



**Fig. 2:** Smear shows multiple microfilarial parasites admixed with eosinophils, polymorphs and necrotic debris. Haematoxylin and Eosin x 40X.

leading to extravasations of larva.<sup>7</sup> Our patient presented with pain and swelling in the left knee, with no clinical symptoms related to the parasite, microfilaria. FNAC of the mass lesion led to the diagnosis of osteosarcoma with coexistent microfilaria.

*Wuchereria bancrofti*, *Brugia malayi*, and *Brugiati mori* are the causes of filarial infections, which are common in tropical and subtropical regions of the world. India is endemic for these parasitic infestations. These thread-like worms reside in the lymphatic channels or nodes, causing occlusion of the lymphatic channels resulting in lymphangiectasia.<sup>8</sup> *W. bancrofti* completes its life cycle in two hosts. Man is the definitive and mosquito is the intermediate host. A significant number of infected individuals remain asymptomatic throughout their lives.<sup>8</sup> Microfilariae have been reported at various sites like epididymis, breast, urine, thyroid, ovarian fluid, bone marrow and upper arm cystic swelling.<sup>9</sup>

Osteosarcoma is a primary malignant mesenchymal bone tumor where the malignant tumor cells directly form the osteoid or bone or both. Demonstration of osteoid directly formed by the malignant cells is essential for making the diagnosis of osteosarcoma.<sup>10</sup> It is the third most common cancer in adolescence, after lymphomas and brain tumors.<sup>10,11</sup>

Radiographs shows an ill-defined lesion in the metaphysis of bone, with osteoblastic and/or osteolytic areas with periosteal reaction.<sup>12</sup> Computed tomography (CT) scans are useful in defining cortical irregularities, fracture sites and mineralization. Magnetic resonance imaging (MRI) is warranted to evaluate the lesion's invasion into the soft tissue and neurovascular structures, level of bone marrow replacement, skip lesions and extension into the bordering joint.<sup>13</sup> Conventional treatment consists of a combination of neoadjuvant chemotherapy and wide surgical excision of the tumor.<sup>11</sup>

Coexistence of microfilaria with various neoplasms like hemangioma of liver, follicular neoplasms, Ewing's

sarcoma of bone, squamous cell carcinoma of maxillary antrum, anaplastic astrocytoma of thalamus, Non-Hodgkin's lymphoma, dentigerous cyst, carcinoma breast and cervical carcinoma has been reported by different cytopathologists.<sup>9,14</sup> Microfilaria circulate in the vasculature and lymphatic system and whenever the neoplastic lesion causes vasculature or lymphatic obstruction they appear in the tissue fluid or shed off into the surface material.<sup>8</sup> In malignancy increased blood vasculature also causes the increase deposition of microfilaria to these sites.<sup>8</sup> Ahluwalia et al have stated that larva may be present in the vasculature and aspiration may lead to the rupture of vessel and release of microfilaria into the aspirate from neoplasm.<sup>11</sup> Chayanika et al have reported six cases of microfilaria in body fluids cytology and FNAC smears in association with tubercular pleural effusion/lymphadenitis and Non Hodgkin's lymphoma.<sup>12</sup> Although the finding of microfilaria in cytological smears is considered incidental, the association of microfilaria with debilitating conditions like malignancy suggests that it is an opportunistic infection.<sup>15</sup>

#### 4. Conclusions

This case report highlights not only the rarity of association of osteosarcoma with coexisting microfilarial infestation but also emphasizes that co-morbidities usually remain unnoticed under the aura of major diagnosis as malignancy. Filariasis may be detected in clinically unsuspected cases, so a high index of suspicion should be kept in mind and careful screening is mandatory for the search of coexisting pathology. In asymptomatic cases patients may harbor infection and fine needle aspiration cytology can be an effective tool for detection, thus helping in disease eradication.

#### 5. Conflict of Interest

The authors declare that there are no conflicts of interest in this paper.

#### 6. Source of Funding

None.

#### References

1. Zhao X, Wu Q, Gong X, Liu J, Ma Y. Osteosarcoma: a review of current and future therapeutic approaches. *Bio Med Eng.* 2021;20:24. doi:10.1186/s12938-021-00860-0.
2. Sivaselvam S. Role of fine needle aspiration cytology in detection of microfilariae: report of 2 cases. *Acta Cytol.* 2007;51(5):803–6.

- doi:10.1159/000325846.
3. Misaghi A, Goldin A, Awad M, Kulidjian AA. Osteosarcoma: a comprehensive review. *SICOT J.* 2018;4:12. doi:10.1051/sicotj/2017028.
4. Sinha R, Sengupta S, Pal S, Adhikari A. Incidental diagnosis of filariasis in association with carcinoma of gall bladder: Report of a case evidenced on ultrasound-guided fine-needle aspiration cytology with review of the literature. *J Cytol.* 2014;31(3):174–5. doi:10.4103/0970-9371.145662.
5. Khare P, Kala P, Jha A, Chauhan N, Chand P. Incidental Diagnosis of Filariasis in Superficial Location by FNAC: A Retrospective Study of 10 Years. *J Clin Diagn Res.* 2014;8(12):5–8.
6. Phukan JP, Sinha A, Sengupta S, Bose K. Cytodiagnosis of filariasis from a swelling of arm. *Trop Parasitol.* 2012;2(1):77–9.
7. Pandey A, Masood S, Awasthi NP. Cystic microfilarial infestation of the liver: a rare presentation. *Int J Infect Dis.* 2015;31:15–7.
8. Tandon N, Bansal C, Sharma R, Irfan S. Role of fine needle aspiration cytology in diagnosing filarial arm cysts. *BMJ Case Rep.* 2013;p. bcr2013009677. doi:10.1136/bcr-2013-009677.
9. Kundu ZS. Classification, imaging, biopsy and staging of osteosarcoma. *Indian J Orthop.* 2014;48(3):238–45.
10. Betz M, Dumont CE, Fuchs B, Exner GU. Physcal distraction for joint preservation in malignant metaphyseal bone tumors in children. *Clin Orthop Relat Res.* 2012;470(6):1749–54. doi:10.1007/s11999-011-2224-0.
11. Ahluwalia C, Choudhury M, Bajaj P. Incidental detection of microfilariae in aspirates from Ewing's sarcoma of bone. *Diagn Cytopathol.* 2003;29(1):31–2.
12. Chayanika P, Sanjay K, Agarwal A, Khan L. Microfilaria in cytological smears at rare sites coexisting with unusual pathology: A series of seven cases. *Trop Parasitol.* 2012;2(1):61–63.
13. Sharma GM, Bhardwaj AR, Relwani NR, Dubey S. Lymphatic Filariasis Presenting as a Swelling over the Upper Arm: A Case Report. *Malays Orthop J.* 2018;12(1):63–8.
14. Rekhi B, Kane SV. Microfilariae coexisting with a follicular lesion in thyroid aspirate smears in an uncommon case of a retrosternal thyroid mass, clinically mimicking a malignancy. *Cyto J.* 2011;8:4. doi:10.4103/1742-6413.76732.
15. Vasantham V, Yadav SK, Sarin N, Singh S, Pruthi S. Incidental detection of microfilaria in cyst fluid of Mucinous cystadenocarcinoma of ovary: A rare case report. *Int J Surg Case Rep.* 2020;70:56–9. doi:10.1016/j.ijscr.2020.04.051.

#### Author biography

**Fauzia Talat Ekram**, Junior Resident

**Syeda Iqra Usman**, Junior Resident

**Fatma Lubna**, Junior Resident

**Kafil Akhtar**, Professor

**Cite this article:** Ekram FT, Usman SI, Lubna F, Akhtar K. Osteosarcoma with co-existent asymptomatic microfilaria-A rare cytological impression. *IP J Diagn Pathol Oncol* 2022;7(2):137-139.