

Content available at: <https://www.ipinnovative.com/open-access-journals>

IP Journal of Diagnostic Pathology and Oncology

Journal homepage: <https://www.jdpo.org/>

## Case Report

# Extradigital glomus tumour of the forearm- A rare site for an unusual tumour

Sneha Mahendran<sup>1</sup>, K Shanmugasamy<sup>1,\*</sup>, S Sowmya<sup>1</sup>

<sup>1</sup>Dept. of Pathology, Mahatma Gandhi Medical College & Research Institute, Sri Balaji Vidyapeeth, Pondicherry, India



### ARTICLE INFO

#### Article history:

Received 10-01-2022

Accepted 21-01-2022

Available online 28-02-2022

#### Keywords:

Extradigital

Glomus

Soft tissue

Tumour

Vascular

### ABSTRACT

Soft tissue tumors are known to occur by varied presentations with atypical features, especially with regard to vascular tumors. The glomus tumour is an unusual benign neoplasm arising from smooth muscles of the perivascular glomus bodies. While it is known to occur in the extremities, this tumour has a predilection for the sub-ungal region of fingers. Vascular tumors as such, especially glomus tumors presenting in extra digital sites are extremely rare. In literature only five cases are available on extra digital sites and few cases have been reported to involve the gastrointestinal tract, airways, shoulders, wrist, knees and elbows. This report discusses the clinical and histopathological features of an glomus tumour of the forearm with atypical presentation.

**Key Messages:** Glomus tumours should be considered as a differential in any nodule occurring in the extradigital locations. Extradigital tumours need not present as a painful purplish nodule and can be asymptomatic. Surgeons and pathologists have to be aware about the varied presentation of these tumours so that misdiagnosis can be avoided and patient can undergo quicker diagnosis and treatment.

This is an Open Access (OA) journal, and articles are distributed under the terms of the [Creative Commons Attribution-NonCommercial-ShareAlike 4.0 License](https://creativecommons.org/licenses/by-nc-sa/4.0/), which allows others to remix, tweak, and build upon the work non-commercially, as long as appropriate credit is given and the new creations are licensed under the identical terms.

For reprints contact: [reprint@ipinnovative.com](mailto:reprint@ipinnovative.com)

## 1. Introduction

Soft tissue tumors are known to occur by varied presentations with atypical features, especially with regard to vascular tumors.<sup>1</sup> The glomus tumour is an unusual benign neoplasm arising from smooth muscles of the perivascular glomus bodies. First reported by Masson in 1924, it has been said to represent hyperplastic growth of the glomus bodies.<sup>1</sup> They constitute approximately 5% of the soft tissue tumors occurring in the hand.<sup>2</sup> It is commonly seen in adults between 20-40 years of age and occurs equally in men and women.<sup>3</sup> Rarely are these tumors seen among the pediatric population.<sup>4</sup>

While it is known to occur in the extremities, this tumour has a predilection for the sub-ungal region of fingers.<sup>5</sup> Vascular tumors as such, especially glomus

tumors presenting in extra digital sites are extremely rare. In literature only five cases are available on extra digital and few cases have been reported to involve the gastrointestinal tract, airways, shoulders, wrist, knees and elbows.<sup>6-8</sup> Classic cases present with a single nodule, but the occurrence of multiple nodules is not unusual.<sup>9,10</sup> Malignant transformation in these tumors are rare.<sup>11</sup> Patients usually present with tender and painful nodules which are sensitive to cold and few cases can also be asymptomatic having many clinical differentials.<sup>12</sup>

Most tumors can be completely cured by excision. Recurrence rates are less and usually occur in cases where incomplete excision has been done.<sup>13</sup>

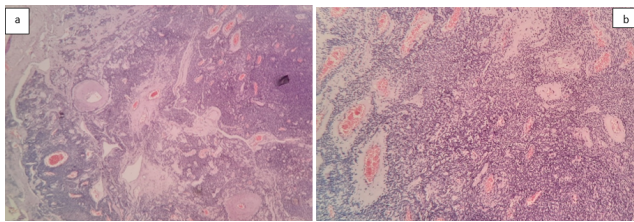
This report discusses the clinical and histopathological features an extra digital glomus tumour of the forearm with atypical presentation.

\* Corresponding author.

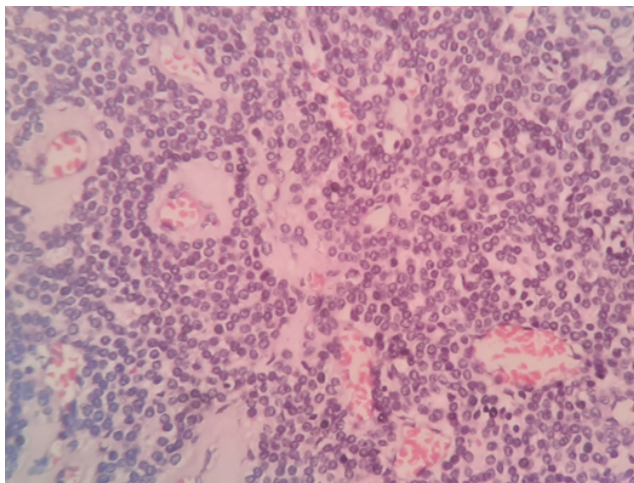
E-mail address: [snehamahendran@gmail.com](mailto:snehamahendran@gmail.com) (K. Shanmugasamy).

## 2. Case Report

The patient presented with a painless swelling in the forearm of short duration. The swelling was superficial and not pulsatile. No radiological investigations were done. Initially thought to be a sebaceous cyst, the swelling was excised and sent for histopathological examination. Post up period was uneventful and so far the patient has not reported any recurrence. The specimen was received in our lab in 10% neutral buffered formaldehyde. The lesion measured 1.5×1×0.5 cm, was skin attached and soft to firm in consistency. The specimen was completely embedded. Microscopic examination showed a well circumscribed tumour below the epidermis. The tumour cells were arranged in lobules interspersed with numerous thick and thin walled blood vessels (Figure 1a & b). Individual tumour cells had scanty eosinophilic cytoplasm, oval to round nucleus with evenly distributed chromatin (Figure 2). No mitotic activity was seen in the sections studied.



**Fig. 1: a & b:** Well circumscribed tumor with cells arranged in lobules, interspersed with numerous thick and thin walled blood vessels.



**Fig. 2:** Individual tumour cells with scanty eosinophilic cytoplasm, oval to round nuclei with even chromatin

## 3. Discussion

The neuromyoarterial glomus body is a physiological arteriovenous shunt that regulates temperature<sup>14</sup> and is

located in the reticular dermis. The structure known as Sucquet- Hoyer canal is the actual area of arteriovenous anastomosis and is lined by endothelial cells as well as muscle fibres lacking elastic lamina. Dispersed within the muscle are the glomus cells. The glomus tumour is an uncommon benign tumour arising from the glomus body or the Sucquet-Hoyer canal. There are similar terms for this tumour such as solid glomus tumour, glomangioma or a nonchromaffin paraganglioma.<sup>12</sup>

Grossly these tumours are pinkish to purple in color with sizes varying from 0.2 -2 cm. Microscopic examination shows three components, glomus cells, blood vessels and smooth muscles in varying proportions. Based on the predominant component, these tumours may be categorized into three variants, namely, the solid variant (scanty smooth muscle and vascular component), glomangioma (with increased blood vessels) and glomangiomyoma (increased smooth muscles and blood vessels). Out of this the solid variant is the most common.<sup>13</sup>

Masson was the first to elaborate on this lesion in the year 1924.<sup>5</sup> A meta-analysis showed varied sites for the occurrence of the tumour including the thigh (n=11), arm (n=9), abdomen (n=7), wrist and hand (n=7), calf and ankle (n=7), foot (n=4), buttock (n=3), lung (n=2), stomach (n=1) and the L3 vertebra (n=1). It was also noted that the frequency of the extradigital tumours were common among men than women.<sup>15</sup> Sub ungual tumours were found to be painful due to abundant nerve supply, a feature that was not commonly seen in extradigital tumours.<sup>14</sup> Notable cases of glomus tumours of the forearm reported in literature so far were mostly deep or intravascular.<sup>16-18</sup> In 1991 Beham et al., reported the first known case of an intravascular glomus tumour in the forearm of a 40 year old man.<sup>19</sup> Le et al., reported a glomus tumour arising from the softtissue in the forearm of a 23 year old female which was confirmed by biopsy in the year 1995.<sup>17</sup>

Extradigital lesions don't have the typical clinical picture at the time of presentation and are difficult to diagnosis as encountered in our case.<sup>20</sup> This usually leads to a delay or incorrect diagnosis. According to a retrospective study spanning across 20 years, it was found that only 9% of tumours were correctly diagnosed on initial examination. They were commonly misdiagnosed as haemangiomas, neurofibromas or neuromas.<sup>21</sup>

## 4. Conclusion

To conclude, glomus tumours should be considered as a differential in any nodule occurring in the extradigital locations. Extradigital tumours need not present as a painful purplish nodule and can be asymptomatic. Surgeons and pathologists have to be aware about the varied presentation of these tumours so that misdiagnosis can be avoided and patient can undergo quicker diagnosis and treatment.

## 5. Conflict of Interest

The authors declare that there is no conflict of interest.

## 6. Source of Funding

None.

## References

1. Proietti A, Ali G, Quilici F, Bertoglio P, Mussi A, Fontanini G, et al. Glomus tumor of the shoulder: a case report and review of the literature. *Oncology Letters*. 2013;6(4):1021–4.
2. Akgün RC, Güler UÖ, Onay U. A glomus tumor anterior to the patellar tendon: a case report. *Acta Orthop Traumatol Turc*. 2010;44(3):250–3. doi:10.3944/AOTT.2010.2174.
3. Tsuneyoshi M, Enjoji M. Glomus tumor. A clinicopathologic and electron microscopic study. *Cancer*. 1982;50(8):1601–7. doi:10.1002/1097-0142(19821015)50:8<1601::aid-cnrcr2820500823>3.0.co;2-5.
4. Magliulo G, Cristofari P, Terranova G. Glomus tumor in pediatric age. *Int J Pediatr Otorhinolaryngol*. 1996;38(1):77–80. doi:10.1016/s0165-5876(96)01394-8.
5. Beksaç K, Dogan L, Bozdoğan N, Dilek G, Akgul GG, Ozaslan C, et al. Extradigital glomus tumor of thigh. *Case Rep Surg*. 2015;p. 1–3. doi:10.1155/2015/638283.
6. Chen KB, Chen L. Glomus tumor in the stomach: a case report and review of the literature. *Oncol Lett*. 2014;7(6):1790–2.
7. Aslam N, Qazi ZU, Ahmad AH, Khan RU. Malignant glomus tumour of larynx: first case report and literature review. *J Laryngology Otol*. 2012;126(7):743–6. doi:10.1017/S0022215112000631.
8. Chun JS, Hong R, Kim JA. Extradigital glomus tumor: a case report. *Mol Clin Oncol*. 2013;2(2):237–9. doi:10.3892/mco.2013.219.
9. Moor EV, Goldberg I, Westreich M. Multiple glomus Tumor: a case Reports and review of the literature. *Ann Plast Surg*. 1999;43(4):436–8.
10. Chiang ER, Chen TH. Multiple glomus tumors in gastrocnemius muscle: a case report. *Arch Orthop Trauma Surg*. 2008;128(1):29–31. doi:10.1007/s00402-007-0377-9.
11. Kayal JD, Hampton RW, Sheehan DJ, Washington CV. Malignant glomus tumor: a case report and review of the literature. *Dermatol Surg*. 2001;27(9):837–40.
12. Goldblum J, Weiss S, Folpe AL. Enzinger and Weiss's Soft Tissue Tumors; 2019.
13. Gombos Z, Zhang PJ. Glomus tumor. *Arch Pathol Lab Med*. 2008;132(9):1448–52.
14. Goldblum JR, Lamps LW, Mckenney JK, Myers JL. Rosai and Ackerman's Surgical Pathology. 11th Edn. Elsevier Health Sciences; 2017.
15. Folpe AL, Fanburg-Smith JC, Miettinen M, Weiss SW. Atypical and malignant glomus tumors: analysis of 52 cases, with a proposal for the reclassification of glomus tumors. *Am J Surg Pathol*. 2001;25(1):1–2.
16. Googe PB, Griffin WC. Intravenous glomus tumor of the forearm. *J Cutaneous Pathol*. 1993;20(4):359–63.
17. Bellec YL, Yelles F, Kapandji T, and OSH. Glomus tumor of forearm: A case report. *Chirurgie de la Main*. 2005;24(2):99–102.
18. Kogure H, Shirakura K, Arisawa N, Aramaki T, Shimegi A. 3 deep-seated glomus tumors in the lower arm. *Acta Orthop Scand*. 1996;67(2):194–9. doi:10.3109/17453679608994672.
19. Beham A, Fletcher CD. Intravascular glomus tumour: a previously undescribed phenomenon. *Virchows Archiv A*. 1991;418:175–7.
20. Lee DW, Yang JH, Chang S, Won CH, Lee MW, Choi JH, et al. Clinical and pathological characteristics of extradigital and digital glomus tumours: a retrospective comparative study. *J Eur Acad Dermatol Venereology*. 2011;25(12):1392–7.
21. Schiefer TK, Parker WL, Anakwenze OA, Amadio PC, Inwards CY, Spinner RJ, et al. Extradigital glomus tumors: a 20-year experience. *Mayo Clin Proc*. 2006;81(10):1337–44.

## Author biography

**Sneha Mahendran**, Post Graduate (Tutor)

**K Shanmugasamy**, Professor

**S Sowmya**, Professor and HOD

**Cite this article:** Mahendran S, Shanmugasamy K, Sowmya S. Extradigital glomus tumour of the forearm- A rare site for an unusual tumour. *IP J Diagn Pathol Oncol* 2022;7(1):48-50.