



## Case Report

# Ectopic tubal pregnancy with partial mole: A rare entity with review of literature

Rajat Gupta<sup>1</sup>, Neelam Gupta<sup>1,\*</sup>, Rashi Garg<sup>1</sup>, Monica Puri<sup>1</sup>

<sup>1</sup>Dept. of Pathology, Maharishi Markandeshwar Medical College & Hospital, Solan, Himachal Pradesh, India



### ARTICLE INFO

#### Article history:

Received 07-08-2020

Accepted 13-08-2020

Available online 03-09-2020

#### Keywords:

Ectopic pregnancies

### ABSTRACT

Gestational trophoblastic disorders in ectopic pregnancy is a rare disorder. Only a handful of cases are reported in literature. Cases of molar pregnancy are usually indistinguishable from tubal non molar gestation and thus underdiagnose on clinical and radiological examination. Meticulous histopathological examination in the all cases of ectopic pregnancy is required for diagnosis and proper management.

© 2020 Published by Innovative Publication. This is an open access article under the CC BY-NC license (<https://creativecommons.org/licenses/by-nc/4.0/>)

## 1. Introduction

Fallopian tubes are the most common site of ectopic pregnancy (98% cases).<sup>1</sup> Gestational trophoblastic disease (GTD) in fallopian tube is a rare phenomenon; 0.76% cases of GTD occur in fallopian tube.<sup>2</sup> Tubal molar pregnancy was first reported in 1871 by Otto. Incidence of ectopic pregnancies is 1 in 1000 pregnancy and molar pregnancy is 1 in 1000 pregnancies. Estimated incidence of molar pregnancy in fallopian tube is about 1.5 per 1,000,000 pregnancies.<sup>3</sup>

## 2. Case History

A 30 years old, third gravida was presented to gynecology OPD with chief complaint of chest pain radiating to right shoulder associated with lower abdominal pain which was radiating to back, one day after suction and evacuation done for bleeding per vaginum. She had amenorrhea for 2 months and was tested positive for pregnancy by urine pregnancy kit.

At the time of admission to our center her pulse rate was 118/minute, respiratory rate was 20/minute. Her blood pressure was 98/60 mm of mercury with oxygen saturation of 98%. Clinical examination revealed marked pallor with

distention of abdomen associated with tenderness and guarding. Per-vaginal examination showed clots in vagina with fullness in right fornix and cervical motion tenderness.

Ultrasound examination of abdomen revealed hemoperitoneum with right tubal ruptured ectopic pregnancy.

Emergency laparotomy was performed. Intraoperative, hemoperitoneum associated with right tubal ruptured ectopic pregnancy was found. Salpingectomy was performed and sent for histopathological examination.

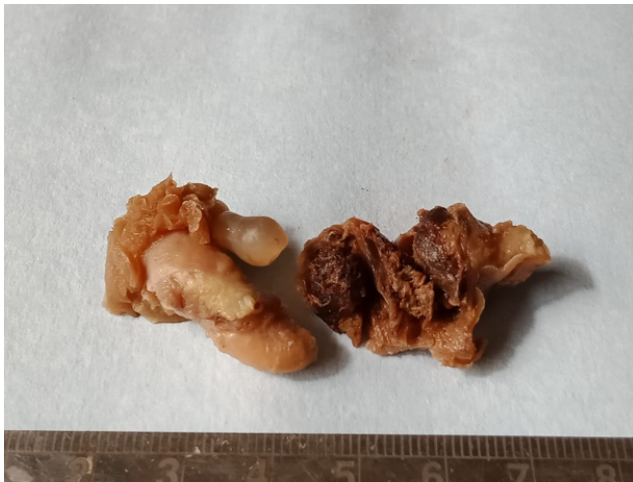Gross examination of specimen showed 4x3.5x1.7 cm brown black colour mass with fallopian tube. Microscopic examination showed irregular shape enlarged villi with scalloped borders with hydropic change admixed with few small fibrotic villi. Few hydropic villi also showed cistern formation. There was mild circumferential trophoblastic proliferation. Diagnosis of partial mole in ectopic pregnancy was rendered.

## 3. Discussion

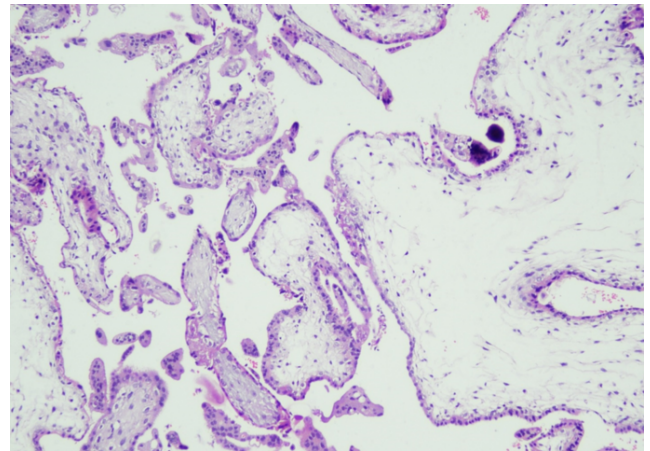
Partial mole in tubal ectopic pregnancy in our case was diagnosed by histopathological examination of excised mass. On the basis of clinical information, radiological examination and intraoperative findings diagnosis of ectopic pregnancy was made while there was no suspicion of molar pregnancy in this case. Because of low incidence of such

\* Corresponding author.

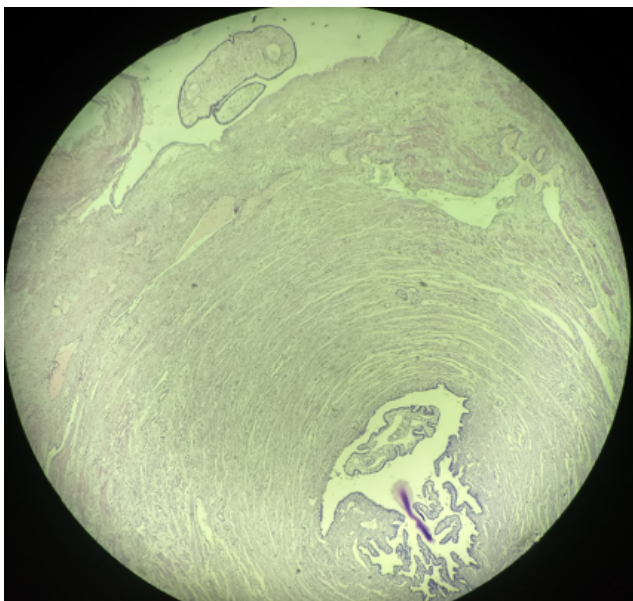
E-mail address: [neelamgupta353@gmail.com](mailto:neelamgupta353@gmail.com) (N. Gupta).



**Fig. 1:** On gross examination of specimen a brown black colour mass was found with in the ruptured fallopian tube.



**Fig. 3:** Irregular shape enlarged villi with scalloped borders, mild trophoblastic proliferation admixed with few small fibrotic villi. (H&E 40x)



**Fig. 2:** Fallopian tube with chorionic villi. (H&E 10x)

cases, it is generally not considered in differential diagnosis.

Hydatidiform moles are characterized by hydropic degeneration of placental villi associated with circumferential proliferation of trophoblast and are arise due to fertilization of abnormal ovum. In complete mole genome is entirely of paternal origin and is due to fertilization of empty ovum by haploid sperm followed by duplication of chromosome or by fertilization by diploid sperm. Partial mole is a pathological process due to fertilization of an ovum by two sperms resulting in paternal to maternal chromosome ratio of 2:1. Clinically tubal molar pregnancy are usually indistinguishable from tubal ectopic pregnancy. Beta HCG levels are also not

useful in differentiating between tubal molar pregnancy and tubal ectopic pregnancy. All surgically managed ectopic pregnancy cases must be submitted for histopathological examination.<sup>4</sup>

Microscopically complete moles are characterized by hydropic change in all villi associated with cistern formation, stromal karyorrhexis, vacuolization of syncytiotrophoblast and cytotrophoblastic proliferation. There is no intraluminal nucleated fetal RBCs. In contrast, partial mole is characterized by focal syncytiotrophoblastic hyperplasia with vacuolization, hydropic change affecting few villi with occasional cistern formation and presence of intra luminal nucleated fetal RBCs. On histopathology early placentation and hydropic abortion closely resemble molar pregnancy. However Hydropic abortion cases do not show circumferential trophoblastic proliferation. In difficult cases DNA flow cytometry for ploidy examination and P57<sup>KIP2</sup> immunocytochemical marker are useful.<sup>4,5</sup> The risk of persistent trophoblastic disease in tubal molar pregnancy is equivalent to that in uterine molar pregnancy, 0.5% in partial mole and 15% in complete mole.<sup>4</sup>

With regard to other trophoblastic disorders, the prognosis of tubal choriocarcinoma is better than uterine choriocarcinoma.<sup>4</sup> Cases of tubal choriocarcinoma with metastasis also respond well to treatment and achieve sustained remission.<sup>2</sup> In literature a case of pulmonary metastasis from tubal molar pregnancy has also been mentioned. Patient had coexisting intrauterine pregnancy and was successfully treated with Actinomycin D.<sup>6</sup>

One case of epithelioid trophoblastic tumour (ETT) of fallopian tube has also been described in literature in which patient presented with high beta HCG levels without amenorrhea. Microscopic examination of tumour showed fairly circumscribed mass with tumour cell were present in sheets and island. Within the island necrosis with deposition

of dense eosinophilic debris was present. Tumour cells were polyhedral in shape with abundant cytoplasm, giving epithelioid appearance but no well differentiated epithelial structure was identified. Frequent mitosis figures were present. Tumour cells were positive for CK7, hPL, PLAP and CD117. Differential diagnosis of epithelioid trophoblastic tumour include other gestational trophoblastic tumours, epithelioid leiomyosarcoma and poorly differentiated carcinoma. In contrast to placental site nodule EET has malignant look on microscopic examination. Exaggerated placental site reaction and placental trophoblastic tumours (PSTT) have infiltrative growth pattern and implantation type intermediate trophoblastic differentiation. PSTT are diffusely positive for hPL, Mel-CAM and focally positive for PLAP in contrast to ETT, which are diffusely positive for PLAP and focally positive for hPL.<sup>7</sup>

Extrauterine lesions of intermediate trophoblast (ELIT) are the rare lesions. Baergen et al described seven cases of ELIT, four cases of placental site nodule (three tubal and one paratubal) and three cases of PSTT (one at each site – fallopian tube, paratubal and ovary). Patients presented with infertility or abnormal uterine bleeding. Lesions ranged from 0.6 to 4 cm, dark brown to pale yellow and hemorrhagic in gross appearance. Microscopic examination of placental site nodules showed well circumscribed nodules with central hyalinization. Cell within nodule had well defined borders with abundant eosinophilic to basophilic cytoplasm and often had vacuolated or degenerated appearance. No mitotic activity was present. PSTT showed cords and sheets of infiltrating intermediate trophoblastic cells having irregular and hyperchromatic nuclei. Binucleated cells and in one case multinucleated cells were noted. Areas of hemorrhage and necrosis along with infiltration into vessel walls with deposition of fibrinoid material was present. Intermediate trophoblast cells are positive for hPL, Mel-CAM and inhibin. These markers are useful in differentiating these tumours from monophasic choriocarcinoma, metastatic carcinomas, sarcomas and mesotheliomas.<sup>8</sup>

#### 4. Conclusion

Though rare, extrauterine trophoblastic disorders including molar pregnancy can occur at any site of ectopic pregnancy. High level of suspicion is required to diagnose

such cases. Clinically patient usually present as ectopic pregnancy or sometimes with only high beta HCG levels. Hence all the cases of ectopic pregnancy which are managed by surgical intervention should be subject to histopathological examination as histopathology is gold standard for diagnosis.

#### 5. Source of Funding

None.

#### Conflict of Interest

None.

#### References

1. Shaw JLV, Dey SK, Critchley HOD, Horne AW. Current knowledge of the aetiology of human tubal ectopic pregnancy. *Hum Reprod Update*. 2010;16(4):432–44.
2. Muto MG, Lage JM, Berkowitz RS, Goldstein DP, Bernstein MR. Gestational trophoblastic disease of the fallopian tube. *J Rep Med*. 1991;36(1):57.
3. Allen L, Dawson C, Nascu P, Rouse T. A Molar Pregnancy within the Fallopian Tube. *Case Rep Obstet Gynecol*. 2016;2016:1–3.
4. Ghazi GF, Donovan PO. Partial mole in ectopic pregnancy. *Gynecol Surg*. 2006;3(2):141–3.
5. Burton JL, Lidbury EA, Gillespie AM, Tidy JA, Smith O, Lawry J, et al. Over-diagnosis of hydatidiform mole in early tubal ectopic pregnancy. *Histopathol*. 2001;38(5):409–17.
6. Govender NS, Goldstein DP. Metastatic tubal mole and coexisting intrauterine pregnancy. *Obstet Gynecol*;49(1):67–9.
7. Parker A, Lee V, Dalrymple C, Valmadre S, Russell P. Epithelioid trophoblastic tumour: report of a case in the fallopian tube. *Pathology*. 2003;35(2):136–40.
8. Baergen RN, Rutgers J, Young RH. Extrauterine Lesions of Intermediate Trophoblast. *Int J Gynecol Pathol*. 2003;22(4):362–7.

#### Author biography

**Rajat Gupta** Post Graduate Student

**Neelam Gupta** Professor and Head

**Rashi Garg** Associate Professor

**Monica Puri** Post Graduate Student

**Cite this article:** Gupta R, Gupta N, Garg R, Puri M. Ectopic tubal pregnancy with partial mole: A rare entity with review of literature. *IP J Diagn Pathol Oncol* 2020;5(3):344-346.