



Original Research Article

Clinicopathologic spectrum of adult nephrectomy specimens – A two year study

Lithu Lal^{1,*}, Thoppil Reba Philipose²¹Dept. of Pathology, Sun Medical And Research Centre, Thrissur, Kerala, India²Dept. of Pathology, A.J Institute of Medical Sciences, Mangalore, Karnataka, India

ARTICLE INFO

Article history:

Received 14-02-2020

Accepted 27-07-2020

Available online 03-09-2020

Keywords:

Nephrectomy
neoplastic
nonneoplastic
Renal

ABSTRACT

Introduction : Nephrectomy is indicated in patients with a wide range of conditions such as irreversibly damaged kidney resulting from symptomatic chronic infections, obstruction, calculi, severe traumatic injury, treatment of renovascular hypertension from non correctable renal artery disease or renal cell carcinoma.

Aim and Objectives: To review the clinicopathological spectrum of renal lesions in total or partial nephrectomy specimens in a tertiary care hospital in Mangalore and to study the non neoplastic renal parenchyma in tumor nephrectomy specimens.

Materials and Methods: The present study was done on 52 nephrectomy specimens received at the Department of Pathology, A.J Institute of Medical Sciences & Research Centre, Mangalore during a period of 2 years (May 2014 - May 2016).

Results: A total of 52 cases over a period of 2 years were studied out of which 35(67.3%) were neoplastic. 34/35 were malignant out of which, 29 were Clear cell Renal Cell Carcinoma (RCC) followed by 2 cases of papillary RCC, 2 cases of sarcomatoid RCC and 1 case of chromophobe RCC. A single case of angiomyolipoma were found. The most common finding in nonneoplastic renal parenchyma immediately adjacent to the tumor was chronic pyelonephritis 57.1% and one case showed caseating tuberculous nephritis. Out of 17 non-neoplastic conditions, 52.9% were hydronephrosis in association with chronic pyelonephritis. Two cases each of adult polycystic kidney disease and caseating tuberculous pyelonephritis were found.

Conclusion: Malignant renal tumors are the major indication for nephrectomy and adequate examination of the adjacent non-neoplastic renal parenchyma is an important tool in recognising patients at risk for early patient care. A detailed histological study of benign nephrectomies could be a clinical predictor for further clinical course, as well as a management strategy for slowing down the progression or decline of renal function.

© 2020 Published by Innovative Publication. This is an open access article under the CC BY-NC license (<https://creativecommons.org/licenses/by-nc/4.0/>)

1. Introduction

Kidney can be involved in various pathological processes, some of which may require its surgical removal.¹The most common lesions encountered in kidney today are certain inflammatory and neoplastic lesions. Renal diseases are responsible for a great deal of morbidity, rather than mortality. Nephrectomy brings in relief to patients from various chronic and life threatening diseases. Renal

cell carcinoma accounts for approximately 2 percent of adult malignancies and 80-85 percent of malignant kidney tumors.¹ The pathologic evaluation of tumor nephrectomy specimens focuses on the diagnosis, grading and staging of the neoplasm. The presence of non neoplastic diseases in these specimens may have significant implications for patient outcomes.² The present study was undertaken to become familiar with the morphological features and to explore , elucidate and document the kidney lesions at nephrectomy.

* Corresponding author.

E-mail address: lithuz@gmail.com (L. Lal).

2. Materials and Methods

The present study was done on 52 nephrectomy specimens received at the Department of Pathology, A.J Institute of Medical Sciences and Research Centre, Mangalore during a period of 2 years (May 2014 - May 2016). Patient particulars were recorded in detail on proformas, which included age, sex, and clinical findings; investigations such as CT scan, USG, and other relevant investigations were also noted. Nephrectomy specimens were examined in detail grossly and a minimum of 3 sections were taken from the tumors including adjacent kidney each of 3 – 5 mm thickness, pelvis, uninvolved kidney, renal artery, renal vein, ureter (cut end) and lymphnodes. After routine paraffin processing, serial sections of 4-micron thickness were cut and routinely stained with haematoxylin and eosin stain. Special stains were used as and when required. Immunohistochemistry was used only in case to differentiate between sarcomatoid RCC and sarcoma of kidney.

3. Results

A total of 52 cases over a period of 2 years were studied out of which 35(67.3%) were neoplastic and remaining 17(32.7%) cases were non-neoplastic. In the present study Renal cell carcinoma was the commonest imaging diagnosis examined in 34(65.4%) patients followed by 5(9.6%) chronic pyelonephritis. Radical nephrectomies accounted for 96.15% of all nephrectomies followed by partial nephrectomy which accounted for 3.84% of total 52 cases.

Neoplastic lesions: Out of 35 cases of neoplastic lesions, Clear cell RCC were predominantly seen in 29/35 cases (82.9%), 2 (5.7%) cases of Papillary RCC and 1 case of chromophobe and angiomyolipoma each (Figure 1). 2 cases of Clear cell RCC with sarcomatoid features and in one of the case rhabdoid features were also noted.

The highest percentage of patients belonged to the age group of 51-60 years for neoplastic lesions with a male:female ratio of 1.11:1 and the most common clinical presentation was flank pain. 1 case each of Papillary RCC were found in the 3rd decade and 6th decade. There was male predominance in the study 25(71.4%) cases. Papillary RCC was seen in both gender equally. All the cases were concordant with the radiological diagnosis.

Grossly, the size of the tumor ranged from 0-4 cm with a predilection towards the left (20/35 cases) and to the upper pole (14/35 cases). Both cases of papillary RCC was found in the mid cortex. 19/31 cases of clear cell carcinoma showed well circumscribed borders with variegated appearance and both cases of Papillary carcinoma had variegated appearance and capsular breach. While Chromophobe RCC was tan brown in color with solid areas.

Most of the cases demonstrated a predominant compact alveolar architecture (44.11%). Two cases of clear cell

RCC underwent sarcomatoid differentiation (Figure 2 a,b), defined as areas of spindle cell proliferations that had the histologic appearance of a sarcoma and one of them even showed 25% area with rhabdoid features.

The majority (55.2%) of renal cell carcinomas were of Furhman nuclear grade II nuclear features. One of the clear cell RCC with sarcomatoid features showed a higher grade of grade IV. Among the 2 patients with papillary variant, Fuhrman grade II and III was seen.

The tumor staging were not assessed in 2 partial nephrectomy specimens. 10 cases had stage pT1a (34.5%) at presentation, followed by pT3a 6 (20.7%) and one case of pT4 was seen involving the ipsilateral adrenal gland in clear cell RCC. In papillary variant both the tumors were in pT3 stage. There was no lymph node metastasis in any of the cases of RCC. Tumor was seen to infiltrate the capsule and the perinephric fat in 10(28.6) cases and 2 (5.7%) cases showed tumor spread beyond the Gerota's fascia. Both the cases of papillary RCC showed tumor infiltrating the capsule. Necrosis was seen in 7(20%) cases and mostly present in stage pT3.

A single case of angiomyolipoma in a 53 year old female presented with pain abdomen. Grossly the kidney measured 16x12x3cms with multiple grey yellow nodules with circumscribed borders with haemorrhagic areas and capsular breach. Microscopically showed a classic triphasic pattern predominantly of mature adipose tissue admixed with fascicles of smooth muscle and thick walled blood vessels.

The most common finding in non-neoplastic renal parenchyma immediately adjacent to the tumor were chronic pyelonephritis 20 (57.1%) cases. One case showed caseating tuberculous nephritis with confluent caseating epitheloid granulomas.

Non-neoplastic lesions: Out of 17 non-neoplastic lesions, 9(52.9%) cases were chronic pyelonephritis in association with hydronephrosis. 2 (11.8%) cases each of adult polycystic kidney disease and caseating tuberculous pyelonephritis were found (Figure 3). The peak age incidence ranged between 31-40 years (35.3%) cases with male preponderance (64.7%) cases.

Loin pain was the leading presenting feature of non-neoplastic lesions 13(76.5%). And 13 cases was associated with hypertension. Although non-neoplastic lesions were common in the left kidney 11 (64.7%) cases, hydronephrosis with chronic pyelonephritis had a predilection towards the right kidney 5 (55.6%) cases. Both the cases of caseating tuberculous pyelonephritis was found to be in the left kidney. All of the non-neoplastic lesions were concordant with the radiological diagnosis except for 1 case of tuberculosis which was misdiagnosed as hydronephrosis with ureteric calculus. Majority showed enlarged kidney with multiple cysts, thinned out cortex and dilated pelvicalyceal system 8 (47%) cases. There were 2

cases of tuberculous pyelonephritis that showed contracted and shrunken kidney with yellow caseous and necrosed areas.

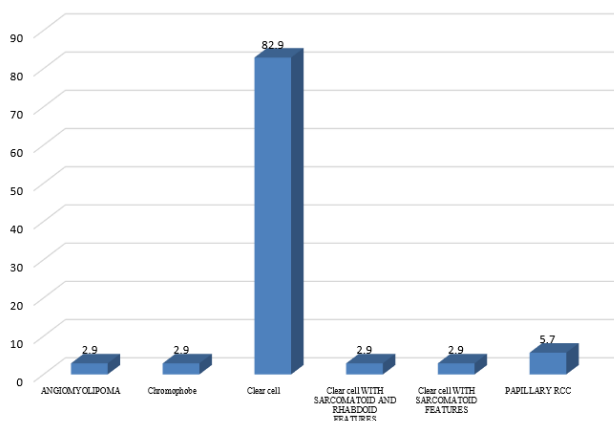


Fig. 1: Frequency of neoplastic lesions of the kidney.

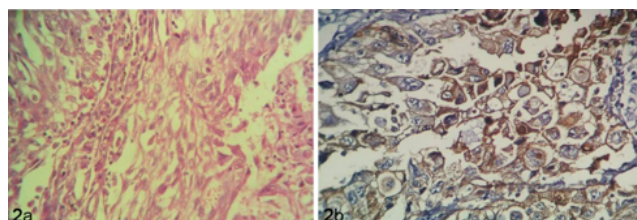


Fig. 2: **a:** Photomicrograph of Clear cell RCC with sarcomatoid differentiation.(H&E x 400), **2b:** Photomicrograph showing CD10 positivity in Clear cell RCC with sarcomatoid differentiation.(H&E x400)

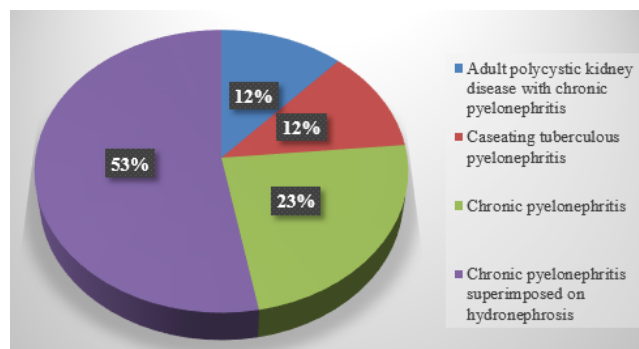


Fig. 3: Frequency of non-neoplastic lesions of the kidney.

4. Discussion

4.1. Indications for nephrectomy

The socioeconomic condition and availability of health care facility is the main factor behind the geographic variation

Table 1: Comparative analysis of neoplastic lesions with other studies.

Studies	Neoplastic lesions
Rafique et al(2007)	23%
Malik et al(1997)	23.5%
Datta et al(2012)	40.9%
Amin et al(2015)	45.7%
Present study	67.3%

Table 2: Comparative analysis of prevalence of chronic pyelonephritis with other studies.

	Chronic pyelonephritis
Malik et al(1997)	55.3%
Rafique et al(2007)	20%
Amin et al(2015)	44.3%
Salma et al(2016)	34%
Present study	25%

regarding the indications for nephrectomy. In our institution, neoplastic lesions of the kidney is the more frequent cause for nephrectomy with a similar predominance observed in other studies. Philips et al in a series of 121 cases has reported, 52 (75.3%) cases of laparoscopic nephrectomy done for malignant and 69 (24.7%) cases for benign causes which was invariance with our study.³

4.2. Neoplastic lesions

Comparative analysis of neoplastic lesions with other studies have been depicted in Table 1. In the present study neoplastic lesions constituted 35 cases (67.3%) of the total 52 nephrectomy cases studied. Among the 35 cases, 34(65.4%) were malignant and only one was benign which was concordant with the study by Latif et al.⁴

4.2.1. Renal cell carcinoma

Incidence: RCC histologic subtype is the first parameter taken into account for pathologic evaluation. In the present study , 29(82.9%) of renal cell carcinoma were of the clear cell type followed by 2 [5.7%] cases of papillary RCC, 1 case of chromophobe RCC and 2 cases of sarcomatoid RCC. This was also similar to the observation made by Patard et al, Rafique et al and Popat et al.⁵⁻⁷ The incidence of renal cell carcinoma increases with advancing age⁸ and thus majority of the patients in the present study were between 51-60 years of age. However studies from WHO reveals that the incidence is two or three times more common in men than in women, in both high risk and low and high risk countries⁸ which was similar to the our study.

Clinical symptoms presented by the patients and associated medical diseases: In the present series, patients presented predominantly with flank pain (45.7%) followed by hematuria (22.9%). These observations were comparable to studies conducted by Popat et al, Malik et al and

Bashir et al.^{7,9,10} Twenty five to thirty percent of renal tumors were found on incidental radiological studies. RCC may remain occult for most of its course. Thus the diagnosis is frequently not made until the disease is either locally advanced and unresectable or metastatic.¹¹ There is increasing incidence of incidentally detected RCC seen in the western world. As a result the masses tend to be much smaller and more localised in the West.⁸ Among the 35 patients diagnosed as neoplastic lesions, 20 had hypertension and the remaining 15 had both hypertension and diabetes mellitus similar to the study done by Henriksen et al.²

Laterality and tumor site: Majority of the cases involved left kidney 20 (57.1%) similar to the observation made by Badmus et al, Bashir et al, Latif et al and Kumar et al.^{4,10,12,13} In the present study upper pole was involved in 14 cases (40%), 12 cases (34.3%) involved lower pole and 9 cases (25.7%) involved the mid cortex similar to the observations made by Popat et al, Aiman et al, Bashir et al and Kumar et al.^{7,10,13,14}

Tumor size: Tumor size predominantly ranged from 0-4 cm in the present series which was invariance with the study conducted by Srivastava et al.¹⁵ However, there is a steady decrease in tumor size at presentation in the west (Kane et al).¹⁶ This is due to greater number of incidental tumors detected on abdominal imaging. Data from National Cancer Database showed size of stage I tumor decreased from a mean of 4.1cm in 1993 to mean of 3.6 cm in 2003.¹⁶ A study by Zhang et al demonstrated that there is a significant correlation between tumor size and tumor grade with stage. Larger tumors were prone to have higher grade and stage and the probability of being clear cell carcinoma grew higher as the tumor size increased.¹⁷

Architectural pattern and cell type in RCC: The most common microscopic pattern observed in the present study was alveolar (51.7 %) followed by solid pattern (48.3%) which was concordant with the study by Amin et al.¹⁸ In the present series the predominant cell type was clear cell type involving 16(55.2%) cases which was also observed in a study by Aiman et al.¹ A study by Warrick et al¹⁹; showed that type 2 tumors of Papillary RCC were commonly high stage (pT3 and pT4) than type 1 tumors which was similar to our study which showed a higher stage of pT3. Sarcomatoid variant is a rare presentation, substantiated in various studies by Mohsin et al, Narang et al and Popat et al.^{7,20,21} Sarcomatoid dedifferentiation that is thought to represent the high-grade end of all subtypes, were noted in two cases in the present study. It occurs in 5% of clear cell RCC cases and implies a poor outcome, associated with reduced response to immunotherapy treatments.^{8,19}

Nuclear grading: The tumor grading of clear-cell carcinoma is a well documented and well recognized independent prognostic tool.¹⁹ The present study revealed that maximum number of renal cell carcinomas i.e. 55.2%

presented with Furrman Grade II nuclear features which was also similar to the studies done by Zhang et al, Bashir et al, Stinga et al and Latif et al.^{4,10,17,19} In a report, five year survival rate based upon tumor grade were 89%, 65% and 46% for tumors with grade I, II and III to IV respectively Tsui et al.¹¹ In the present study papillary tumors were with grade III and grade II and its statistical significance was difficult to assess owing to few number of patients in this group.

Tumor staging: The evaluation of pT distribution showed most cases in pT1 stage in the present study with a similar distribution pattern in clear cell carcinoma group and papillary variant revealed predominance of pT3 tumors. Currently, the most extensively used prognostic tool for RCC is the Tumor, Nodes and Metastasis (TNM) staging system, and a number of studies have shown the system to be accurate in reflecting RCC prognosis.¹⁹ The present study showed 3 cases with renal vein/ venal caval invasion in which one of the case was seen in Papillary RCC. A study by Abel et al have found that extent of vena caval invasion was an important prognostic factor and that majority of patients with positive vascular wall margins have increased recurrence rate.²² In the study by Hashmi et al 10% cases showed renal vein involvement. They concluded that microscopic invasion is dependent and macroscopic invasion is an independent prognostic factor. When both factors are found together, disease outcome is worse.¹¹ In the study by Hank et al, patients with adrenal gland involvement have significantly worse survival than those with peri-renal fat involvement. Direct ipsilateral adrenal gland involvement in RCC was rare, found only in 2.5% of radical nephrectomy specimen²³, similar to our study which showed 3.4% (1/34) adrenal involvement and to the study done by Hashmi et al.¹¹ Hence, adrenal gland involvement is a rare event which carries worse prognosis.¹¹

Tumor infiltration into the capsule and perirenal fat: Capsular invasion has been evaluated as a prognostic indicator in localized RCC. In a study conducted in China by Hyuk-Jin et al²⁴, observed rate of capsular invasion was 35.5% equivalent to that reported by Hashmi et al.¹¹ In the present study the rate of capsular invasion was 28.6%. A study by Hashmi et al also demonstrated association between capsular involvement and higher tumor grade and also increased tumor size. A recent study by Minervini et al, tumor invasion on the perirenal fat tissue side was a significant predictor of tumor recurrence in patients who undergo tumor enucleation whereas capsular penetration on the parenchymal side does not predict risk of recurrence.¹¹

Tumor necrosis: Coagulative tumor necrosis was initially recognized as a predictor of aggressive RCC behavior in the 1970s.²⁵ One third of investigated tumors 7 (20%) cases showed the presence of necrosis in the present study which was seen in a case of Papillary RCC and the rest were found in clear cell tumors with stage

pT3 and nuclear grade II and III similar to the study by Sengupta et al (30%) and Lam et al (54%). Several studies from the Mayo Clinic have demonstrated the importance of histologic tumor necrosis as an independent predictor of survival in patients with clear cell RCC.²⁶

4.2.2. Angiomyolipoma

Angiomyolipoma (AML) is the most common benign mesenchymal neoplasm in kidney accounts for approximately 1% of all surgically removed renal tumors.²⁷ In the present study, one case of classic triphasic type of angiomyolipoma was encountered which was concordant with the studies by Popat et al, Latif et al and Amin et al.^{4,7,18}

4.2.3. Adjacent renal parenchyma in tumor nephrectomy specimens

Heightened awareness of the importance of host related renal diseases prompted the College of American Pathologists to include in the 2009 “Protocol for the examination of specimens from patients with Invasive Carcinoma of tubular origin”, descriptors of findings in the nonneoplastic cortex. Therefore a section removed further most from the tumor, influence the medical, nononcologic, management of patients and reduce the burden of chronic kidney disease and end stage renal disease in renal cancer patients.²⁸ The most common finding in the present study in non-neoplastic renal parenchyma immediately adjacent to the tumor was chronic pyelonephritis 20 (57.1%) cases similar to the study by Amin et al and Usha et al.¹⁸ The association of renal tuberculosis and renal cancer is exceptional; less than fifty cases have been reported in the literature.²⁹ The present study observed a double incidental discovery of a tumor of the kidney and renal tuberculosis. While the incidental discovery of renal cell carcinoma in a tuberculous kidney is a classical finding, the discovery of tuberculous lesions after nephrectomy for cancer is exceptional.³⁰ There is a high frequency of this association of kidney cancer in tuberculous patients in the Mediterranean including Spain. The age of onset of this association is between 50 and 70 years with a male predominance and could be related to reactivation of latent tuberculosis secondary to local immunosuppression induced by the tumor.²⁹ In the present study the adjacent non-neoplastic renal parenchyma were normal in 12 cases (35.2%) similar to Bijol et al³¹ and Henriksen et al.² An absence of pathologic findings in non-neoplastic renal parenchyma occurred significantly more often in Papillary RCC in the study by Bijol et al³¹ and was similar to our study.

In the present study 15 patients with diabetes who did not show diabetic glomerulosclerosis in adjacent renal parenchyma were noted, similar to the observation made by Bijol et al,³¹ proving the well known observation in the

literature that only a subset of diabetic patients develops diffuse diabetic glomerulosclerosis.

4.3. Non neoplastic lesions

Radical nephrectomies for benign conditions were performed in our institution for extensive parenchymal damage by non-neoplastic disease and for advanced disease causing irreversible loss of renal function (usually defined as a contribution to global renal function of less than 10% or a glomerular filtration rate of less than 10mL/min).³²

Incidence of non-neoplastic lesions: In the present study 17 non-neoplastic lesions were encountered and hydronephrosis with chronic pyelonephritis was the commonest indication for nephrectomy accounting for 52.9% cases of non-neoplastic category similar to a study by Narang et al, Popat et al, Malik et al and Ghalayeni et al.^{7,9,21,33}

Age and gender incidence: In the present series the age ranged between 31-40 years which showed 6/17 (35.3%) cases and was concordant with the study by Ghalayini et al.³³ Male preponderance was observed 11/17 cases similar to a study by Sujatha et al.³² Hydronephrosis were seen with female:male ratio of 1:1.25. But the published data gives female preponderance with a female to male ratio of 2:1.³⁴

Clinical presentation: The most common symptoms observed in present study were flank pain (76.5%), hematuria (11.8%) and mass abdomen (5.9%) and similar observations were made by Divyashree et al, Zaki et al and Aiman et al who reported loin pain as the most common clinical feature.^{1,35,36}

Radiological diagnosis: All of the non-neoplastic lesions were concordant with the radiological diagnosis except for 1 case of tuberculosis which was reported on USG/CT as hydronephrosis with ureteric calculus in the present study. Many causes for urinary obstruction are known, the commonest being renal calculi.⁶ In the present study obstructive chronic pyelonephritis showed 2 cases with renal calculi diagnosed on radiology. The reason for this could be that most cases of renal calculi are being treated conservatively and hence nephrectomy is not required in most cases.

Laterality: Majority of patients presented with a unilateral disease with predilection towards the left kidney 11 (64.7%) cases with a similar observation made by Amin et al and Sujatha et al.^{18,32} In the present study, hydronephrosis was seen mostly in the left kidney which was at variance with published data which documented hydronephrosis commonly in right side.³⁴

4.3.1. Chronic pyelonephritis

Comparative analysis of prevalence of chronic pyelonephritis with other studies are shown in Table II. Non obstructive pyelonephritis is said to be less common than obstructive pyelonephritis. In a necropsy study by

Farmer et al¹⁸ the incidence of non obstructive chronic pyelonephritis was found to be only 0.23% which was at variance to the present study with showed 23.52% cases. The gross and microscopic findings of the present study were similar to the description available in the literature.^{14,37,38}

4.3.2. Hydronephrosis

Majority of the cases comprised of hydronephrosis with associated chronic pyelonephritis 52.9% of the non-neoplastic lesions. In a study by Sujatha et al, hydronephrosis was seen in 77/192 nephrectomy cases and the commonest cause was pelvi-ureteric junction obstruction.³²

4.3.3. Adult polycystic kidney disease

The present study had 2/52 cases of Adult polycystic kidney similar to a study by Divyashree et al.²⁰ A study by Zaki et al,³⁶ showed 24/189 cases which was in variance with the present study.

4.3.4. Tuberculosis

In present study there were only two cases of tuberculosis both in men between the age group of 41-70 years with a predilection towards the left kidney. Simon et al reported a male preponderance of renal tuberculosis with the highest incidence between the ages of 20 and 50 years.³⁸ Male preponderance is reported in genitourinary tuberculosis in ratio of 2:1.¹⁶

5. Conclusion

The spectrum of adult renal tumors in the present study were consistent with that of previously reported literature. Tumor size were significantly small with low grade and stage pT1 which reflects the effective measures that were taken to diagnose the disease early. The extent of tumor necrosis correlated with higher T classification and should be reported in clinical assessment as a independent predictor for survival.

Although accurate pathologic evaluation of renal neoplasms remain essential, adequate examination of non-neoplastic renal parenchyma is an important tool in recognising patients at risk for progressive renal disease after nephrectomy and important implications for early patient care.

A detailed histological study of benign nephrectomies could be a clinical predictor for further clinical course, as well as a management strategy for slowing down the progression or decline of renal function.

6. Source of Funding

None.

7. Conflict of Interest

None.

References

1. Yasir M, Aiman A, Singh K. Histopathological spectrum of lesions in nephrectomy specimens: A five-year experience in a tertiary care hospital. *J Scientific Soc.* 2013;40(3):148.
2. Henriksen KJ, Meehan SM, Chang A. Non-neoplastic Renal Diseases are Often Unrecognized in Adult Tumor Nephrectomy Specimens. *Am J Surg Pathol.* 2007;31:1703–8.
3. Phillips J, Catto JW, Lavin V, Doyle D, Smith DJ, Hastie KJ, et al. The laparoscopic nephrectomy learning curve: a single centre's development of a de novo practice. *Postgraduate Med J.* 2005;81:599–603.
4. Latif F, Mubarak M, Kazi JI. Histopathological characteristics of adult renal tumours: a preliminary report. *JPMA-J Pak Med Assoc.* 2011;61(3):224.
5. Patard JJ, Leray E, Rioux-Leclercq N, Cindolo L, Ficarra V, Zisman A, et al. Prognostic Value of Histologic Subtypes in Renal Cell Carcinoma: A Multicenter Experience. *J Clin Oncol.* 2005;23(12):2763–71.
6. Rafique M. Nephrectomy: indications, complications and mortality in 154 consecutive patients. *JPMA.* 2007;.
7. Popat VC, Kumar MP, Udani D, Mundra MP, Vora DN, Porecha MM, et al. A study on culprit factors ultimately demanding nephrectomy. *Internet J Urol.* 2010;7.
8. Eble JN, Sauter G, Epstein JI, Sesterhenn IA. World Health Organisation Classification of Tumors. Pathology and Genetics of Tumors of the Urinary System and Male Genital Organs. Lyon: IARC Press; 2004. p. 12–43.
9. Fadil MAE, Memon SR, Ibrahim AL, Gizawi A, Ghali A, M A. Nephrectomy in adults: Asir Hospital experience. *Saudi J Kidney Dis Transplant.* 1997;8(4):423.
10. Bashir N, Bashir Y, Shah P, Bhat N, Salim O, Samoon N, et al. Histopathological study of renal tumors in resected nephrectomy specimens-An experience from tertiary care centre. *Nat J Med Res.* 2015;5(1):25–9.
11. Hashmi AA, Ali R, Hussain ZF, Faridi N. Clinicopathologic Patterns of Adult Renal Tumors in Pakistan. *Asian Pacific J Cancer Prevent.* 2014;15:2303–7.
12. Badmus TA, Salako AA, Sanusi AA, Arogundade FA, Oseni GO, Yusuf BM. Adult nephrectomy: our experience at Ile-Ife. *Niger J Clin Pract.* 2008;11:121–6.
13. Kumar M, Yelkar U, Patil BRG, Karigoudar MH. Pankaj Pande and Patil SB.; Spectrum of Histopathological lesions in Nephrectomy specimens-A two year study in a tertiary care hospital. *Int J Res Pharm Biomed Sci.* 2012;3(4):1787–90.
14. Alpers CET. The Kidney . In: Abbas KA, Kumar V, Fausto N, editors. Robbins and Cotran Pathologic Basis of Disease. Philadelphia: WB Saunders Co; 2010. p. 905–70.
15. Srivastava A, Mandhani A, Kapoor R, Jain M, Dubey D, Raghavendra M, et al. Prognostic factors in patients with renal cell carcinoma: Is TNM (1997) staging relevant in Indian subpopulation?. *Indian J Cancer.* 2004;41:99.
16. Kane CJ, Mallin K, Ritchey J, Cooperberg MR, Carroll PR. Renal cell cancer stage migration. *Cancer.* 2008;113:78–83.
17. Zhang C, Li X, Hao H, Yu W, He Z, Zhou L. The correlation between size of renal cell carcinoma and its histopathological characteristics: a single center study of 1867 renal cell carcinoma cases. *BJU Int.* 2012;110(11b):481–5.
18. Amin AN, Pai P, Upadhyaya K. A Histopathological spectrum of nephrectomy specimens in a tertiary hospital in southern India. *Int J Biol Med Res.* 2015;6(3):5173–8.
19. Stîngă AC, Stîngă AS, Simionescu C, Mărgăritescu C, Cruce M. Histopathological study of renal cell carcinoma. *Curr Health Sci J.* 2009;35(1):52–7.

20. Mohsin R, Hashmi A, Sultan G, Shehzad A, Mubarak M, Ghazanfar N, et al. Renal tumors in young adults: a single-center experience from a developing country. *Urol J*. 2012;9(1):373.
21. Narang V, Garg B, Walia A, Sood N, Malhotra V. Histomorphological Spectrum of Nephrectomy Specimens- A Tertiary Care Centre Experience. *National J Lab Med*. 2016;5(2):51–4.
22. Abel EJ, Carrasco A, Karam J, Tamboli P, Delacroix S, Vaporeciyan AA, et al. Positive vascular wall margins have minimal impact on cancer outcomes in patients with non-metastatic renal cell carcinoma (RCC) with tumour thrombus. *BJU Int*. 2014;114(5):667–73.
23. Han KR, Bui MH, Pantuck AJ, Freitas DG, Leibovich BC, Dorey FJ, et al. TNM T3a Renal Cell Carcinoma: Adrenal Gland Involvement is Not the Same as Renal Fat Invasion. *J Urol*. 2003;169:899–904.
24. Cho HJ, Kim SJ, Ha US, Hong SH, Kim JC, Choi YJ. Prognostic value of capsular invasion for localized clear-cell renal cell carcinoma. *Eur urol*. 2009;56(6):1006–12.
25. Sengupta S, Lohse CM, Leibovich BC, Frank I, Thompson RH, Webster WS, et al. Histologic coagulative tumor necrosis as a prognostic indicator of renal cell carcinoma aggressiveness. *Cancer*. 2005;104(3):511–20.
26. Lam JS, Shvarts O, Said JW, Pantuck AJ, Seligson DB, Aldridge ME, et al. Clinicopathologic and molecular correlations of necrosis in the primary tumor of patients with renal cell carcinoma. *Cancer*. 2005;103(12):2517–25.
27. Mukhopadhyay SG, Mukherjee K, Manna K, A. Renal Tumours in Adults with Correlation between Fuhrman Grading and Proliferative Marker. *Iranian J Pathol*. 2015;10(4):281–9.
28. Bonsib SM, Pei Y. The Non-neoplastic Kidney in Tumor Nephrectomy Specimens. *Adv Anatomic Pathol*. 2010;17(4):235–50.
29. Adil N. Renal Adenocarcinoma On Tuberculosis Nephritis. *Webmed Central Urol*. 2012;3(6):3515.
30. Saadi A, Ayed H, Bouzouita A, Kerkeni W, Cherif M, Slama RMB, et al. Discovery of Renal Tuberculosis in a Partial Nephrectomy Specimen Done for Renal Tumor. *Urol Case Rep*. 2015;3(3):68–9.
31. Bijol V, Mendez GP, Hurwitz S, Rennke HG, Nosé V. Evaluation of the Nonneoplastic Pathology in Tumor Nephrectomy Specimens. *Am J Surg Pathol*. 2006;30:575–84.
32. Sujatha S, Kowsalya R, Mythri KM. Benign Nephrectomies and its Variables along with Vascular Changes in the Renal Artery: A Study from Tertiary Care Centre from South India. *J Nephrol Urol Res*. 2014;2(1):14–8.
33. Ghalayini IF. Pathological Spectrum of Nephrectomies in a General Hospital. *Asian J Surg*. 2002;25(2):163–9.
34. Russell RCG, Williams NS, Williams NS. Bailey and Love's short practice of surgery. London: Arnold: Illustrated; 2000. p. 1348.
35. Divyashree BN, Venkatesh K, Madhusudhan HR, Raju BKH. Pathological spectrum of Non-Neoplastic Diseases in the Nephrectomy Specimens. *J Evid Based Med Healthcare*. 2014;1(15):1909–20.
36. Zaki MR, Ghazanfar A, Asif K. Nephrectomy for non-traumatic benign renal diseases: Its indications and outcomes in a developing country. *Pain*. 2012;147:77.
37. Fogo AB, Cohen AH, Jennette JC, Bruijn JA, Colvin RB. Fundamentals of renal pathology. New York: Springer; 2006. p. 377–88.
38. Rosai J, Order N. Urinary tract In: Ackerman's Surgical Pathology ;. p. 1237–42.

Author biography

Lithu Lal Consultant Pathologist

Cite this article: Lal L, Philipose TR. **Clinicopathologic spectrum of adult nephrectomy specimens – A two year study.** *IP J Diagn Pathol Oncol* 2020;5(3):306-312.