



## Case Report

# Tuberculosis of the appendix with coexistent carcinoma- A rare case report

Kafil Akhtar<sup>1,\*</sup>, Sumbul Warsi<sup>1</sup>, Mohd Talha<sup>1</sup>, Saquib Alam<sup>1</sup>

<sup>1</sup>Dept. of Pathology, Jawaharlal Nehru Medical College, AMU, Aligarh, Uttar Pradesh, India



### ARTICLE INFO

#### Article history:

Received 20-04-2020

Accepted 16-05-2020

Available online 04-06-2020

#### Keywords:

Appendix

Adenocarcinoma

Histopathology

Tuberculosis.

### ABSTRACT

An association between chronic granulomatous infection, like tuberculosis and cancer exists, but few studies elucidate the possible mechanism of development. Break in the mucosal barriers with bacterial infection and impaired cell mediated immunity are known to be associated with cancer. Gastrointestinal tuberculosis is common in the ileocecal region, but isolated appendiceal tuberculosis is rare. Cancers of the appendix are rare and most of them are found accidentally on surgical appendectomy specimens performed for appendicitis. The common appendiceal tumors are carcinoid, adenoma and lymphoma. Adenocarcinoma of the appendix accounts for only 0.08% of all cancers. It usually presents as appendicitis with evident lump or abscess. We present a case of a 42-year-old lady, who presented with symptoms of vague abdominal pain with low grade fever for 4 months and was diagnosed as appendiceal tuberculosis with coexistent mucinous adenocarcinoma of the appendix. Appendectomy with right hemicolectomy was performed followed by adjuvant chemo-irradiation. She is doing well after 6 months of follow up period.

© 2020 Published by Innovative Publication. This is an open access article under the CC BY-NC license (<https://creativecommons.org/licenses/by-nc/4.0/>)

## 1. Introduction

Cancers of the appendix with coexistent tuberculosis is rare and most of them are found accidentally on surgical appendectomy specimens performed for appendicitis.<sup>1</sup> Both tuberculosis and malignancy are a global health problem and a cause of sufferings worldwide.<sup>2</sup> The possible mechanism for the development of malignancy could be the break in the mucosal barriers with bacterial infection and the impaired cell mediated immunity.<sup>3</sup>

Gastrointestinal tuberculosis most commonly involves the ileocecal region and tuberculosis of the appendix is rare.<sup>3</sup> The common appendiceal tumors are carcinoid, adenoma and lymphoma.<sup>2</sup> Adenocarcinoma of the appendix accounts for only 0.08% of all appendiceal malignancies.<sup>2</sup> It usually presents as appendicitis with evident lump or abscess.<sup>4</sup> The symptoms of weight loss, constipation, occult blood in stool and radiologic image of an appendicular and extensive ileocecal mass may be seen both in tuberculosis

and cancer.<sup>5,6</sup> An endoscopic biopsy of the mass lesion is important to rule out a coexisting carcinoma.<sup>6</sup>

## 2. Case Summary

A 42-year-old lady presented to the surgery clinics with complaints of pain in the right iliac fossa with lump and fever for 4 months. There was no associated history of nausea, vomiting and altered bowel habits. On local examination, an ill defined firm swelling was felt over the right iliac fossa. No other lump or abnormality was detected.

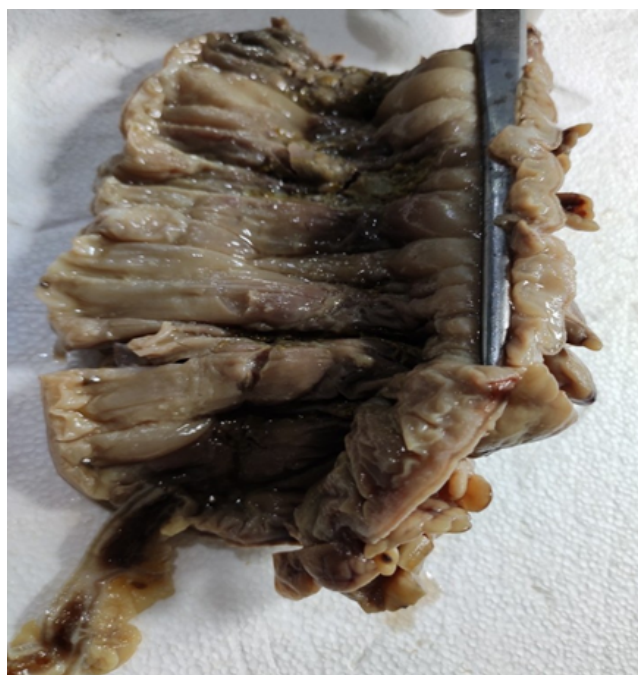
Routine hematological investigations showed an increased total leucocyte count of 45,700/cumm with neutrophilia with raised ESR of 120 mm in first hour. USG abdomen revealed an ill-defined mass involving the appendix, extending to the ileo-caecal junction. Contrast enhanced computed tomography (CECT) of abdomen and pelvis showed a heterogenous mass lesion in the appendix with irregular thickened colo-caecal epithelial wall. Serum CEA levels were normal. A provisional clinical diagnosis of appendicitis with a colonic malignancy was given. On

\* Corresponding author.

E-mail address: [drkafilakhtar@gmail.com](mailto:drkafilakhtar@gmail.com) (K. Akhtar).

exploratory laparotomy, as the appendix was enlarged and inflamed with diffuse irregular thickening of the wall of the caecum and ascending colon, appendisectomy with right hemicolectomy was performed.

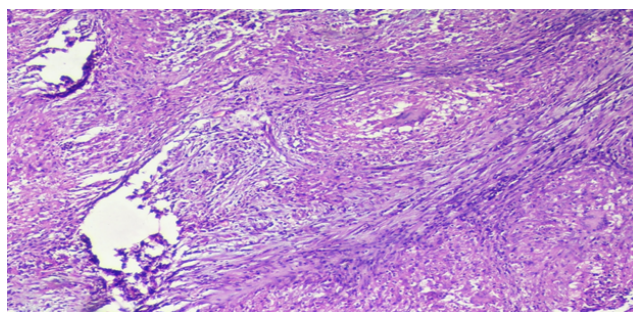
Grossly the appendix showed a  $4 \times 3 \times 2.5$  cm firm, grey-yellow solid growth at the tip with involvement of the adjacent caecum and ascending colon (Figure 1). Microscopic examination of the excised mass showed well-formed epithelioid granulomas comprising of epithelioid cells, langhan's giant cells, lymphocytes and plasma cell with foci of caseous necrosis (Figure 2) admixed with areas of atypical glands with intracytoplasmic mucin, with marked cytologic atypia and necrosis (Figure 3). A diagnosis of tuberculosis with low-grade mucinous adenocarcinoma was given. All the sampled lymph nodes were negative for metastasis. The patient was administered adjuvant 6 cycles of 5-fluorouracil based chemotherapy. Currently, she is doing well, after 6 months of follow up period with no evidence of residual disease.



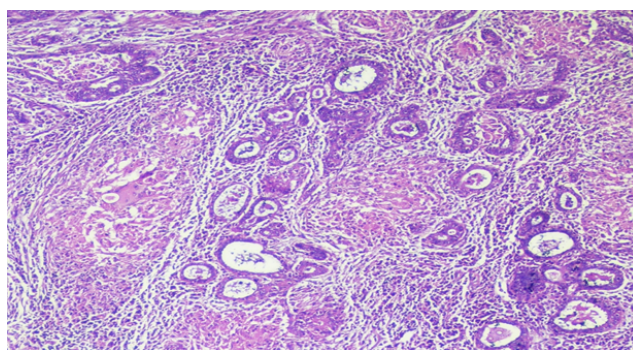
**Fig. 1:** Grossly the appendix was enlarged with a  $4 \times 3 \times 2.5$  cm firm, grey-yellow solid growth at the tip with diffusely thickened adjacent caecum and ascending colon.

### 3. Discussion

The possible etiopathogenesis of coexistent carcinoma and tuberculosis may be the development of cancer with a previous history of chronic granulomatous infection and immunosuppression caused by cancer leading to increased tubercular susceptibility.<sup>5</sup> Studies have reported that T-cell immunosuppression is associated with mycobacterial



**Fig. 2:** Microscopic examination showed well-formed epithelioid granulomas comprising of epithelioid cells, langhan's giant cells, lymphocytes and plasma cell with foci of caseous necrosis and a single disrupted atypical gland. Hematoxylin and Eosin x10X.



**Fig. 3:** Tissue section showed areas of atypical glands with intracytoplasmic mucin, with marked cytologic atypia and necrosis. Hematoxylin and Eosin x10X.

infections and may predispose to leukemias, lymphomas and carcinomas and visa versa.<sup>5,6</sup>

Tanaka et al have reviewed 27 cases of coexistent tuberculosis and colon cancer, with a likely hypothesis that carcinoma predisposes to tubercular infection.<sup>5</sup> Jain et al have postulated that tubercular ulcer may be a risk factor of carcinoma, due to chronic inflammatory process and subsequent regeneration.<sup>6</sup> The toxic metabolites produced by the bacteria mixed with sterols in the bile play a role in the causation of colorectal carcinoma.<sup>4</sup> Also decreased natural killer (NK) cell activity, with increased chromosomal aberrations have been reported in coexistent carcinoma and tuberculosis.<sup>5,6</sup>

Carcinoma of the appendix is an incidental finding and accounts for less than 1.0% cases.<sup>1</sup> Carcinoids, adenocarcinomas, cystadenomas and lymphomas comprise the few appendiceal tumors.<sup>3,7</sup> Adenocarcinoma is the most common histological type and presents clinically as acute appendicitis.<sup>7</sup> Ileocaecum is the most common site for gastrointestinal tuberculosis.<sup>8</sup> Chronic tubercular infection of the appendix is very rare and coexistent carcinoma is even rarer.

Clinical features of anorexia, weight loss, constipation, occult blood in stool and an extensive ileocaecal and ascending colonic mass may be seen in both tuberculosis and carcinoma.<sup>5,6</sup> So a careful endoscopic biopsy of the colonic lesion is essential to rule out a coexisting carcinoma.<sup>9</sup> A barium enema of such lesions may be predictive of overt malignancy of colon with an unduly long tailing segment, particularly in the proximal colon.

The treatment of appendiceal lesions is still debatable. Simple appendectomy is curable in appendiceal mucocele, and cystadenomas.<sup>10</sup> In a suspected case of malignancy of the caecum or the appendix, right hemicolectomy is the procedure of choice.<sup>10,11</sup> Appendisectomy with right hemicolectomy was performed in our case, as the appendix was enlarged and inflamed with diffuse irregular thickening of the wall of the caecum and ascending colon. Many oncologists recommend adjuvant 5-FU-based chemotherapy in patients with node-positive intestinal type adenocarcinoma.<sup>11</sup> The benefit of systemic chemotherapy for advanced disease is unknown and mucinous appendiceal adenocarcinomas are reported to be chemotherapy resistant.<sup>11</sup>

#### 4. Conclusions

The clinicians need to be aware of the protean manifestations of tuberculosis and carcinoma of the appendix and maintain a high index of suspicion in any appendicular lumpy lesion. Further research is required to determine, if a tuberculous infection may facilitate carcinogenesis and visa-versa.

#### 5. Source of Funding

None.

#### 6. Conflict of Interest

None.

#### References

1. Patel RR, Nandu VV. Primary Appendicular Malignancy Presenting as Abdominal Wall Abscess with Secondary Tuberculosis Infection: an Interesting Case Report. *Indian J Surg Oncol.* 2018;9(4):613–7.
2. Cheng MP, Chakra CNA, Yansouni CP, Cnossen S, Shrier I, Menzies D, et al. Risk of Active Tuberculosis in Patients with Cancer: A Systematic Review and Meta-Analysis. *Clin Infect Dis.* 2016;64(5):635–44.
3. Falagas ME, Kouranos VD, Athanassa Z, Kopterides P. Tuberculosis and malignancy. *QJM.* 2010;103(7):461–87.
4. Mccusker ME, Coté TR, Clegg LX, Sobin LH. Primary malignant neoplasms of the appendix: a population-based study from the surveillance, epidemiology and end-results program. *Cancer.* 1973;94(12):3307–12.
5. Tanaka K, Kondo S, Hattori F, Yamashita Y, Matsuda M, Itoh K, et al. A case of colonic carcinoma associated with intestinal tuberculosis, and an analysis of 26 cases reported in Japan. *Gan No Rinsho.* 2007;33(9):1117–23.
6. Jain BK, Chandra SS, Narasimhan R, Ananthakrishnan N, Mehta RB. Coexisting tuberculosis and carcinoma of the colon. *Aus NZ J Surg.* 2011;61(11):828–31.
7. Okita A, Kubo Y, Tanada M, Kurita A, Takashima S. Unusual abscesses associated with colon cancer: report of three cases. *Acta Med Okayama.* 2007;61(2):107–13.
8. Poon RT, Chu KW. Inflammatory caecal masses in patients presenting with appendicitis. *World J Surg.* 2012;23(7):713–6.
9. Pickhardt PJ, Levy AD, Rohmann CA, Kende AI. Primary neoplasms of the appendix: radiologic spectrum of disease with pathologic correlation. *Radiographics.* 2013;23(3):645–62.
10. Cirocco WC. Right hemicolectomy remains the treatment of choice for adenocarcinoma of the appendix. *Gastrointest Endosc.* 2010;61(6):791–4.
11. Pahlavan PS, Kanthan R. Goblet cell carcinoid of the appendix. *World J Surg Oncol.* 2015;3:36–41.

#### Author biography

**Kafil Akhtar** Professor

**Sumbul Warsi** Resident

**Mohd Talha** Resident

**Saqib Alam** Resident

**Cite this article:** Akhtar K, Warsi S, Talha M, Alam S. **Tuberculosis of the appendix with coexistent carcinoma- A rare case report.** *IP J Diagn Pathol Oncol* 2020;5(2):223-225.