



Original Research Article

Diagnostic role of FNAC in head and neck lesions: A prospective study

Nazia Sheikh¹, Sumatul Khurshid^{1,*}, Altaf Malik², Rahil Muzzafar³¹Dept. of Pathology, Government Medical College, Doda, Jammu and Kashmir, India²Dept. of Surgery, Government Medical College Doda, Jammu and Kashmir, India³Dept. of ENT, Government Medical College Doda, Jammu and Kashmir, India

ARTICLE INFO

Article history:

Received 19-01-2020

Accepted 01-02-2020

Available online 29-02-2020

Keywords:

Head and neck lesions

Cytopathology

Diagnosis

Nonneoplastic

Neoplastic

ABSTRACT

Introduction: FNAC is simple, rapid, inexpensive, minimallyinvasive technique and with the absence of complications done on OPD basis to diagnose different types of swellings located in the head and neck. Head and neck swellings commonly originate from cervical lymph node, thyroid glands, salivary glands, subcutaneous/cutaneous swellings and soft tissues.

Aims and Objectives: To study the role of FNAC in the diagnosis of non-neoplastic and neoplastic lesions of head and neck in all age groups in Chenab valley.

Materials and Methods: This prospective study was done over a period of 9months from May 2019-January 2020 in GMC Doda. It was a hospital based study. In this study 116 cases of FNAC Lesions of various age groups were studied by pathologist for cytology and accordingly diagnosis were made.

Results: The Present study was carried out on 116 patients presenting with head and neck swellings over a period of 9 months from May 2019 to January 2020. Out of all cases Cutaneous/Subcutaneous swellings constituted maximum number of cases I;e 46 cases (39.65%); all were of benign nature followed by lymphnode lesions I;e 41 cases (35.344%) followed by thyroid lesions I;e 23 cases (19.82%) followed by salivary gland lesions I;e 6 cases (5.17%)

Conclusion: To conclude; FNAC is considered to be the most reliable technique in the early diagnosis of various Head and Neck lesions so that proper intervention could be taken at earliest possible time in early stages and should be considered as first line investigation in the evaluation of lesions in head and neck region.

© 2020 Published by Innovative Publication. This is an open access article under the CC BY-NC-ND license (<https://creativecommons.org/licenses/by/4.0/>)

1. Introduction

Fine needle aspiration cytology (FNAC) is a simple, rapid and economical method to sample superficial swellings found in the head and neck region.¹ The technique is performed in the OPD and is non – invasive procedure. The main goal of FNA is to determine the presence or absence of neoplasm, assure the clinical benign impression of the mass, and if malignant, to determine the type of malignancy.² Although FNAC has been proven effective in diagnosis of solid masses of head and neck, It can be both diagnostic and therapeutic in cystic swellings.³ Its usefulness in diagnosis

of cystic masses in these sites is much less certain.⁴

It is helpful for the diagnosis of salivary gland tumours where it can differentiate between a malignant and a benign tumour with over 90% accuracy.⁵

FNAC is particularly helpful in the work-up of cervical masses and nodules because biopsy of cervical swelling should be avoided unless all other diagnostic modalities have failed to establish a diagnosis.⁶ FNAC does not give the same architectural detail as histology but it can provide cells from the entire lesion as many passes through the lesion can be made while aspirating.⁷ FNA has a high diagnostic accuracy, but problems may arise, primarily affecting sensitivity of technique, especially if the aspirated mass is cystic.⁸

* Corresponding author.

E-mail address: sumatmalik@gmail.com (S. Khurshid).

Head and neck lesions comprise of developmental, inflammatory and neoplastic conditions. Commonly seen swellings are thyroglossal cysts, dermoid cysts, lymphangioma, haemangioma, lymphadenitis, sialadenitis, lipomas and neoplastic pathologies.⁹ FNAC has an accuracy rate exceeding 92%.¹⁰ FNAC plays an important role in the diagnosis of metastatic disease; it not only confirms the diagnosis but also helps to determine the nature of primary tumor.¹¹ Tuberculous lymphadenitis being common in head and neck area can be diagnosed with a sensitivity ranging from 70 to 90%.¹² Salivary gland FNAC has gained wide spread acceptance with reported sensitivity and specificity for diagnosing neoplasm almost more than 90%.¹³ Moreover, FNAC has also been reported to be most accurate at diagnosing epithelial cysts¹⁴

2. Aims and Objective

1. To diagnose head and neck lesions/swellings by FNAC technique.
2. To differentiate Benign and malignant lesions in order to scrutinize the treatment strategies .

3. Materials and Methods

This Prospective observational study was conducted in the Department of Pathology in GMC Doda.

3.1. Study period

This study was done over a period of 9 months from May 2019-January 2020.

3.2. Study population

This study included total of 116 cases of Head and Neck lesions.

3.3. Inclusion criteria

1. All Patients coming to the department with Head and neck swellings irrespective of age and sex were included in the study.
2. All kinds of Diagnosis i.e Infective, Inflammatory, Non – neoplastic and neoplastic were included in the study

3.4. Exclusion criteria

Lesions other than Head and Neck were excluded from the study.

The Present study was carried out on 116 patients presenting with head and neck swellings over a period of 9 months . The relevant clinical details, history regarding the swelling, local examination of the swelling were taken. Special investigations like Ultrasound, were done where required particularly for the thyroid and Salivary gland

lesions in order to determine the origin and nature of lesion in the form of diffuse, Hyperechoic / Isoechoic /Hypoechoic solid lesions, BIRADS /TIRADS in case of thyroid lesions . FNAC was performed by the Pathologist in the department. Aspiration was carried out using 20ml disposable disposable syringe with 20 -25 gauze needle attached to Franzen's aspiration handle or with the needle only . Smears were air dried and fixed in acetone free methyl alcohol, stained with the help of MGG(May - Grunwald Giemsa) stain, Romanowsky group of stains, slides were mounted with DPX mountant. One or two wet smears were fixed in 95% ethyl alcohol and stained with Papanicolaou (PAP) wherever required for the assessment of nuclear morphology particularly in case of thyroid lesions. Special stains like ZiehlNeelson (ZN) stain were used wherever required. Findings of FNAC were recorded and patients were advised non-operative treatment and follow up or biopsy and surgical intervention depending upon the pathology. The cytomorphological features of various diseases were studied. Few cases diagnosed on FNAC were correlated with histopathology.

4. Results

The Present study was carried out on 116 patients presenting with head and neck swellings over a period of 9 months from May 2019 to January 2020. Out of all cases maximum number of cases were found in the age group of 31-40 years i.e 25 cases followed by 11-20 years i.e 22 cases. (Table 1) Males constituted 54 cases and females constituted 62 cases with male to female ratio of 0.87:1 (Table 2) Among thyroid lesions categorized by " THE BE THESDA SYSTEM FOR REPORTING THYROID CYTOLOGY"(TBSRTC 2016):1 case was found to be non- diagnostic/unsatisfactory(TBSRTC CAT-I),14 cases were diagnosed as benign with 9 cases as colloid nodules, 5 cases as Hashimottos thyroiditis (TBSRTC CAT-II) (Figure 1), 3 cases as Atypia of undetermined significance(AUS)(TBSRTC CAT-III), 1 case as Follicular neoplasm (TBSRTC CAT IV) (Figure 2), 1 case as Suspicious of papillary thyroid carcinoma(TBSRTC CAT V), 1 case as Papillary carcinoma thyroid (TBSRTC CAT VI)(Figure 3), 1 case as Anaplastic thyroid carcinoma(TBSRTC CAT VI) .(Table 3) and 1 case as thyroglossal cyst.

Among the total 41 lymphnode lesions of head and neck:23 cases were diagnosed as Non – specific reactive lymphadenitis (Figure 4), 13 cases as Chronic granulomatous lymphadenitis (Figure 5), 2 as Acute suppurative lymphadenitis, 2 cases as NHL/SLL and 1 case as Metastatic deposits of PD SCC (Figure 6).

Among the total 6 cases of salivary gland lesions :1 case was diagnosed as Benign salivary gland cyst,1 as acute infective sialadenitis, 1 as Chronic infective Sialadenitis, 2 cases as Pleomorphic adenoma (Figure 7) and 1 case as

Mucoepidermoid carcinoma (Figure 8).

Among the total 46 cases of Subcutaneous/cutaneous lesions of head and neck: 18 cases were diagnosed as non-neoplastic and 28 cases were diagnosed as Neoplastic. Among 18 non-neoplastic cases; 9 cases were diagnosed as abscess and 9 cases were diagnosed as Epidermal Inclusion cysts (EIC). Among 28 cases diagnosed as Neoplastic, all cases were found to be benign in nature of which 19 cases were Lipomas, 3 as benign vascular lesions, 3 as benign adnexal lesions, 2 as Benign fibrous histiocytomas (BFH), 1 as benign spindle cell lesion and 1 case as benign lymphoepithelial lesion. No malignant case was diagnosed.

Table 1: Age wise distribution of cases (n=116)

Age in years	Number of cases	Percentage
0-10	16	13.7%
11-20	22	18.96%
21-30	21	18.10%
31-40	25	21.55%
41-50	20	17.24%
51-60	9	7.75%
>60	3	2.58%
Total	116	100%

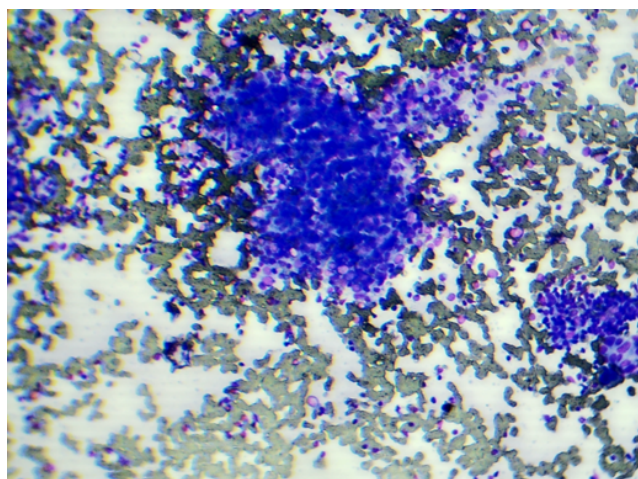


Fig. 1: Photomicrograph showing thyroid follicles encroached by lymphoid cells against a colloid free bloody background (Hashimoto's thyroiditis).

5. Discussion

The Present study was carried out on 116 patients presenting with head and neck swellings over a period of 9 months from May 2019 to January 2020. Out of all cases maximum number of cases were found in the age group of 31-40 years i.e. 25 cases followed by 11-20 years i.e. 22 cases. This shows that head and neck swellings are seen mostly in the age group of 31-40 years followed by 11-20 years. Among gender distribution maximum number of cases were

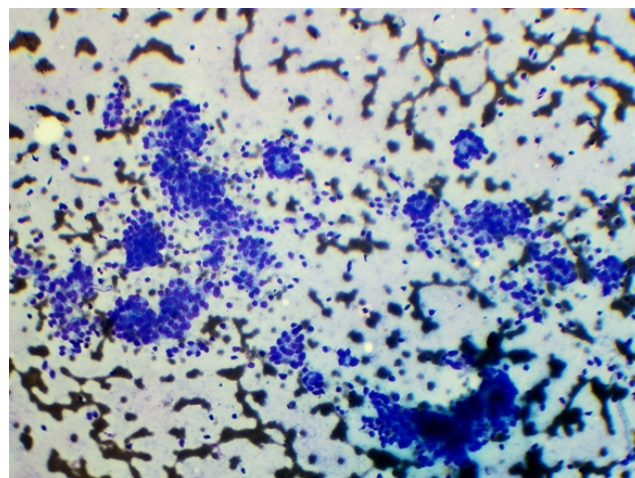


Fig. 2: Photomicrograph showing follicular cells forming micro follicles against a colloid free bloody background (Follicular Neoplasm).

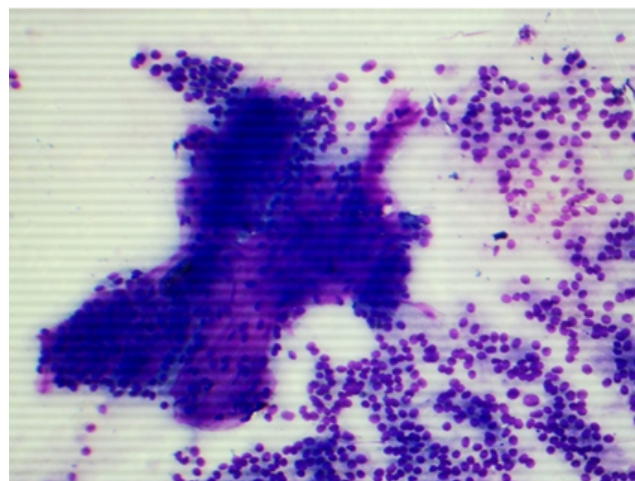


Fig. 3: Photomicrograph showing Tumour cells arranged in papillae with blunt edges with fibrovascular cores and dispersed individually showing overcrowding, nuclear grooves and at places Intranuclear cytoplasmic inclusions (INCIS) against a background of blood mixed thick chewing gum like colloid seen in other parts of the smear (Papillary thyroid carcinoma).

females. Female gender was a slightly more affected in current study and was in concordance with the study done by Dr. Nazia Tabassum et al.¹⁵ Among thyroid lesions Maximum cases were diagnosed as benign (TBSRTC CAT-II) in the form of colloid nodules and Hashimoto's thyroiditis. This could be due to Iodine deficiency in this region or due to Autoimmune etiology in Hashimoto's cases. This shows that Neoplasm are less likely seen in this region.

Among lymph node lesions, maximum were diagnosed as Non-specific reactive lymphadenitis that too in childhood age group followed by Chronic granulomatous lymphadenitis in young population. This study is in concordance with

Table 2: Gender wise distribution of cases(n=116)

Males	Percentage	Females	Percentage	Total	Percentage
54	46.55%	62	53.44%	116	100%

Table 3: FNAC diagnosis of thyroid lesions(n=23)/TBSRTC category

Tbsrtc category	Examples	Number of cases		
TBSRTC CAT-I	Non Diagnostic /Unsatisfactory	1		
TBSRTC CAT- II	Benign	14	Colloid nodules	9 cases
			Hashimottos thyroiditis	5 cases
TBSRTC CAT -III	Atypia of undetermined significance (aus)	3		
TBSRTC CAT-IV	Follicular neoplasm /suspicious for follicular neoplasm/hurthle cell neoplasm	1		
TBSRTC CAT -V	Suspicious for papillary neoplasm	1		
TBSRTC CAT VI	Papillary carcinomathyroid	1		
	Anaplastic carcinoma thyroid	1		
OTHERS	Thyroglossal cyst	1		

Table 4: FNAC diagnosis of lymphnode lesions of head and neck(n=41)

Diagnosis	Non –specific reactive lymphadenitis	Chronic granulomatous lymphadenitis	Acute suppurative lymphadenitis	Nhl/sll	Metastatic deposits of pd scc
Number of Cases	23	13	2	2	1

Table 5: FNAC diagnosis of salivary gland lesions(n=6)

Diagnosis	Number of cases
Benign salivary gland cyst	1
Acute infective sialadenitis	1
Chronic infective sialadenitis	1
Pleomorphic adenoma	2
Mucoepidermoid carcinoma	1

Table 6: FNAC diagnosis of subcutaneous /cutaneous lesions of head and neck region(n=46)

Non-neoplastic Inflammatory (n=9)	Non-specific (n=9)	Neoplastic Benign (n=28)		Malignant
		Lipoma	19	
		Vascular lesions	3	
ABSCESS	Epidermal Inclusion Cysts(EIC)	Adnexal lesions	3	NIL
		BFH	2	
		Spindle cell lesion	1	
		Benign lymphoepitheliallesion	1	

the study done by Dr. NaziaTabassum et al.¹⁵ Among the total 6 cases of salivary gland lesions :1case was diagnosed as Benign salivary gland cyst,1 as acute infective sialadenitis, 1 as Chronic infective Sialadenitis, 2 cases as Pleomorphic adenoma and 1 case as Mucoepidermoid carcinoma. From our study this could not be interpreted as which type of diagnosis is more common because this study was done over short period of time and need further studies

to be done in more number of patients.

Among the total 46 cases of Subcutaneous/cutaneous lesions of head and neck: 18 cases were diagnosed as non-neoplastic and 28 cases were diagnosed as Neoplastic. Among 18 non-neoplastic cases; 9 cases were diagnosed as abscess and 9 cases were diagnosed as Epidermal Inclusion cysts (EIC).Among 28 cases of Subcutaneous /Cutaneous diagnosed as Neoplastic, all cases were found

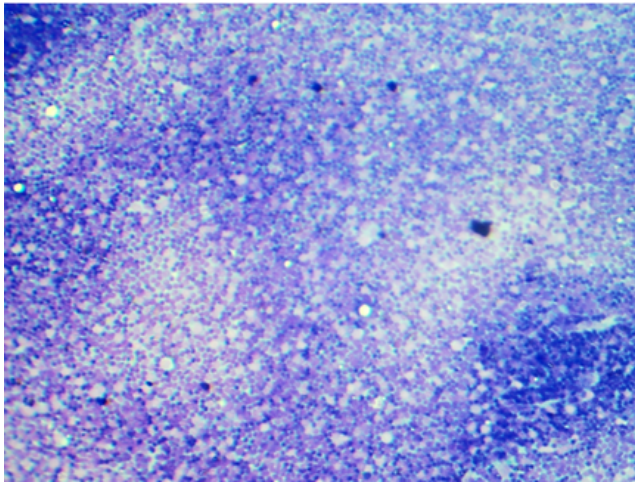


Fig. 4: Photomicrograph showing polymorphic population of lymphoid cells with tingible body macrophages. (Reactive Node)

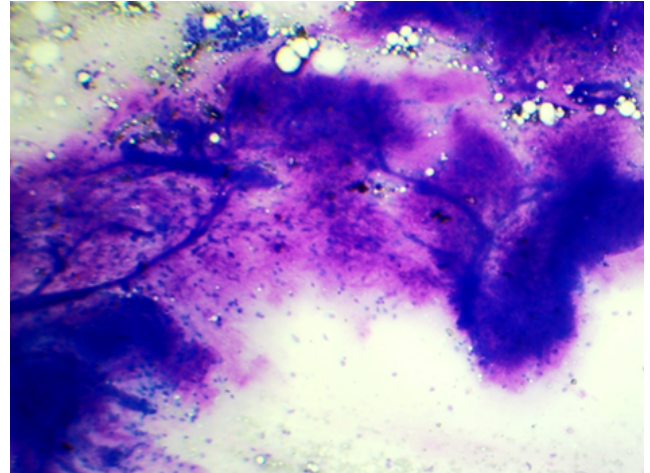


Fig. 7: Photomicrograph from salivary gland lesion shows chondromyxoid material with epithelial and myoepithelial cells (Pleomorphic adenoma) (MGG STAIN)

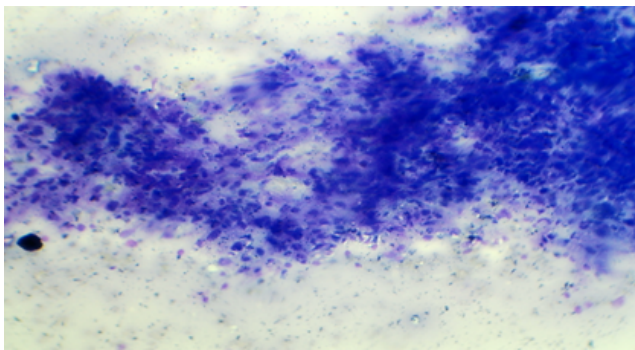


Fig. 5: Photomicrograph showing epithelioid cells interspersed with lymphoid cells forming large granuloma in lymph node (Tuberculosis)

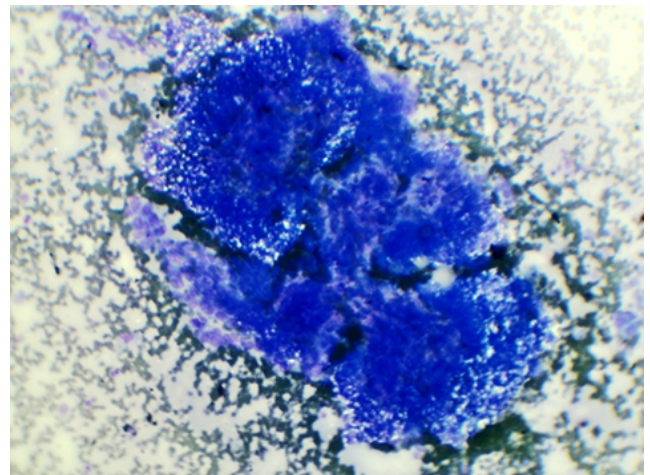


Fig. 8: Photomicrograph showing three populations of cells: i.e. intermediate cells, mucous secreting cells and few squamous cells in Mucoepidermoid carcinoma salivary gland.

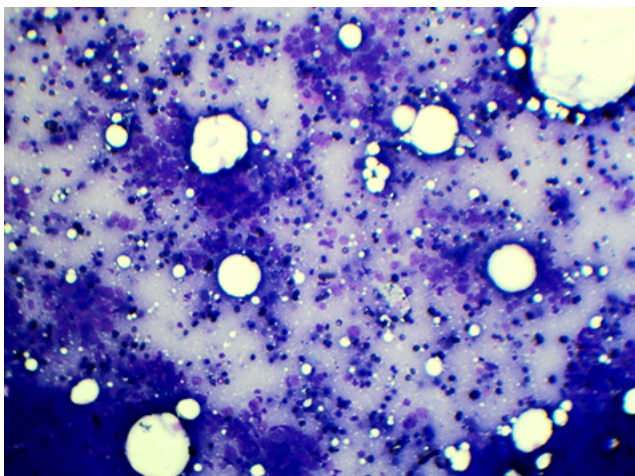


Fig. 6: Photomicrograph showing tumour cells arranged in clusters and dispersed individually having high N/C ratio. (Mets PD SCC to lymph node)

to be benign in nature of which 19 cases were Lipomas, 3 as benign vascular lesions, 3 as benign adnexal lesions, 2 as Benign fibrous histiocytomas (BFH), 1 as benign spindle cell lesion and 1 cases as benign lymphoepithelial lesion. NO malignant cases was diagnosed. This shows that subcutaneous /cutaneous swellings of Head and Neck region are almost benign in this study.

6. Conclusion

To conclude; FNAC is considered to be the most reliable technique in the early diagnosis of various Head and Neck lesions so that proper intervention could be taken at earliest possible time in early stages and should be considered as first line investigation in the evaluation of lesions in head

and neck region. It has a high degree of diagnostic yield and sensitivity to diagnose lymphnode lesions thereby obviating the need for open biopsy, thyroid lesions, salivary gland swellings and benign tumours or cystic lesions in head and neck area to plan the surgery without considering further invasive bio psy procedures preoperatively.

7. Source of funding

None.

8. Conflict of interest

None.

References

- Orell RS. Manual and Atlas of FNAC ; 1995, .
- Firat P, Ersoz C, Uguz A, Önder S. Cystic lesions of the head and neck: cytohistological correlation in 63 cases. *Cytopathol.* 2007;0(0):070123011315003-??? doi:10.1111/j.1365-2303.2006.00400.x.
- Afridi S, Malik K, Wahed I. Role of fine needle aspiration biopsy and cytology in breast lumps. *J Coll Physicians Surg Pak.* 1995;5:75–77.
- Sheahan P, O’Leary G, Lee G, Fitzgibbon J. Cystic Cervical Metastases: Incidence and Diagnosis using Fine Needle Aspiration Biopsy. *Otolaryngol–Head Neck Surg.* 2002;127(4):294–298. doi:10.1067/mhn.2002.128600.
- Burnand KG, Young AE, Lucas J, Rrolands BJ, Scholefield J. The new Aird’s companion in surgical studies. China: Elsevier ; 2005, .
- Layfield LJ. Fine-needle aspiration of the head and neck. *Pathol - Phila.* 1996;4:409–438.
- Kirk RM, Ribbans WJ. Clinical Surgery in General. Edinburgh: Elsevier ; 2004, .
- Moatamed NA, Naini BV, Fathizadeh P, Estrella J, Apple SK. A correlation study of diagnostic fine-needle aspiration with histologic diagnosis in cystic neck lesions. *Diagnostic Cytopathol.* 2009;37(10):720–726. doi:10.1002/dc.21088.
- Mcguirt WF. Differential diagnosis of neck masses. In: Cummings CW, Flint PW, Harkar LA, editors. Cummings Otolaryngology Head and Neck Surgery. vol. 3 ; 2005, .
- Stell, Maran. Assessment. In: Watkinson JC, Gaze MN, Wilson JA, editors. Head and Neck Surgery. Butterworth Heinemann ; 2000, .
- Bhagwan NI, Kane SV, Chinoy RF. Cytological evaluation of the enlarged neck node: FNAC utility in metastatic neck diseases ; 2011, . Available from: <http://www.ispub.com/ostia/index.php?xmlFilePath=journals/ijpa/vol6n2/neck.xml>.accessed24th.
- Johnson JT, Zimmer L. Fine needle aspiration of neck masses (18th Dec. 2006) ”eMedicine ; 2006, . Available from: <http://www.emedicine.com/ent/topic561.htm>.accessedon24th.
- Karne FJ, Faquin FC, Gland S. Salivary Gland. In: Cibas ES, Ducatman SB, editors. Cytology (eds): Diagnostic Principles and clinical Correlates. Saunder ; 2003, .
- Peters BR, Schnadig VJ, Quinn FB, Hokanson JA, Zaharopoulos P, et al. Interobserver Variability in the Interpretation of Fine-Needle Aspiration Biopsy of Head and Neck Masses. *Arch Otolaryngol - Head and Neck Surg.* 1989;115(12):1438–1442. doi:10.1001/archotol.1989.01860360040014.
- Tabassum N, Malik A, Khurshidul S. Cytopathology of lymphadenopathy in patients of Chenab valley. *JMSCR.* 2020;08(01):538–544.

Author biography

Nazia Sheikh Senior Resident

Sumatul Khurshid Assistant Professor

Altaf Malik Assistant Professor

Rahil Muzzafar Assistant Professor

Cite this article: Sheikh N, Khurshid S, Malik A, Muzzafar R. Diagnostic role of FNAC in head and neck lesions: A prospective study. *IP J Diagn Pathol Oncol* 2020;5(1):93-98.