



Original Research Article

Tuberculosis is still the leading cause of cervical lymphadenopathy-results of a fnac analysis in a tertiary care hospital

Praba V¹, Sharmila G^{2,*}¹Coimbatore Medical College, Coimbatore, Tamil Nadu, India²Dept. of Pathology, Government IRT Perundurai Medical College, Perundurai, Erode, Tamil Nadu, India

ARTICLE INFO

Article history:

Received 10-02-2020

Accepted 11-02-2020

Available online 29-02-2020

Keywords:

Cytology - FNAC - neck lymphadenopathy - tuberculosis - malignant neoplasms

ABSTRACT

Context: Cervical lymphadenopathy is a common clinical presentation. Enlarged cervical lymphnodes could be due to variety of causes ranging from simple infectious process to malignant neoplastic conditions. Enlarged salivary glands, thyromegaly are also mimickers for enlarged cervical lymphnodes, hence posing diagnostic challenges clinically. In those cases, FNAC can be used as first line diagnostic test.

Aims and Objective: Purpose of this study is to utilize the usefulness of FNAC in diagnosis of both pediatric and adult cervical lymphadenopathy and to determine the spectrum of disease distribution among various age group patients in a tertiary care hospital.

Materials and Methods: This is a retrospective study carried out at IRT Perundurai medical college for a period of two years from January 2018 to December 2019. 318 patients with enlarged neck nodes more than 6-week duration were registered and aspirated. Aspirated material was used for cytology analysis using Haematoxylin and eosin staining, MGG staining. Special stains such as modified ziehlneelson staining for AFB was also done. Data were statistically analyzed.

Results: Out of 318 cases of FNAC performed in patients with enlarged cervical nodes, 268 cases were found to be adults, the most frequent cause in adults was found to be tuberculous lymphadenitis followed by metastatic carcinomatous deposit and third most common cause was reactive lymphoid hyperplasia, whereas in pediatric patients the most common cause was found to be reactive lymphoid hyperplasia.

Conclusion: In our study was conducted in a tertiary care hospital, the most common cause of cervical lymphadenopathy in adults was found to be tuberculous lymphadenitis followed by metastatic carcinomatous deposit whereas in case of pediatric cases the most common cause of cervical lymphadenopathy is reactive lymphoid hyperplasia closely followed by tuberculous lymphadenitis. As per WHO – Sustainable development goals-to end TB epidemic in 2030-this study alarms the increasing burden on health sector in fighting against mycobacterium. FNAC is particularly efficacious in our country where mycobacterial infection is endemic. Hence early intervention is mandatory.

© 2020 Published by Innovative Publication. This is an open access article under the CC BY-NC-ND license (<https://creativecommons.org/licenses/by/4.0/>)

1. Introduction

Cervical lymphadenopathy is a common clinical presentation. Enlarged cervical lymphnodes could be due to variety of causes ranging from simple infectious process to malignant neoplastic conditions. Enlarged salivary glands, thyromegaly are also mimickers for enlarged cervical lymphnodes, hence posing diagnostic challenges

clinically.¹⁻³ In those cases, FNAC can be used as first line diagnostic test in adults lymphnodes ranging in size from 2cm onwards (significant lymphadenopathy) persistent or progressively enlarging are of immediate clinical concern especially when associated with other clinical symptoms such as fever, chronic cough, weight loss, anorexia etc.

FNAC of lymphnode has high sensitivity and specificity in distinction between benign and malignant lesions. Advantages of lymphnode aspirate is of low cost, rapid

* Corresponding author.

E-mail address: resumekarthick@gmail.com (Sharmila G).

turnaround time, could be done as outpatient procedure itself, less morbidity and easily provides cells for other special studies and molecular diagnostic tests.^{4,5}Care in preparation of smear is necessary because lymphocytes are fragile and easily crushed if too much pressure is applied.^{6,7}FNAC is accepted as a minimally invasive method for evaluating lymphadenopathy. It has added advantage of preserving lymphnode architecture when excision biopsy is needed.^{8–10}

2. Aims and Objective

Purpose of this study is to utilize the usefulness of FNAC in diagnosis of both pediatric and adult cervical lymphadenopathy and to determine the spectrum of disease distribution among various age group patients in a tertiary care hospital.

3. Materials and Methods

This is a retrospective study carried out at IRT Perundurai medical college, pathology department for a period of two years from January 2018 to December 2019. 318 patients with enlarged significant neck lymphnodes of more than 6-week duration were registered with clinical history and aspirated.^{10–12}FNAC was carried down by cytopathologist with 10ml syringe and 23 gauge needle, both isopropyl alcohol fixed and air dried are made for each case. Aspirated material was used for cytology analysis using Haematoxylin and eosin staining, MGG staining. Special stains such as modified ziehlneelson staining for AFB was also done. All slides are carefully screened with primary attention to overall low power pattern. All those slides with hypocellularity were excluded.^{13–15}Datas were statistically analyzed.

4. Results

Table 1: Age Distribution of Cases

S. No	Age wise category	Number of Patients
1	< 15 years	50
2	16 – 30	114
3	31 – 45	58
4	46 – 60	44
5	>60 years	52

Out of 318 cases aspirated, 50(15.7%) cases belongs to pediatric age group (<15yrs) and 268(84.3%) cases belongs to adult age group

Out of total 318 cases, 102(32%) cases were diagnosed as caseating granulomatous lymphadenitis, 78(24.5%) cases diagnosed as granulomatous lymphadenitis without necrosis, 52(16.3%) cases as metastatic carcinomatous deposit where squamous cell carcinomatous deposit is the leading cause, 72(22.6%) as reactive lymphoid hyperplasia,

Table 2: Spectrum of disease distribution

S. No	Diagnosis distribution	Number of Patients
1	Caseating Granulomatous Lymphadenitis	102
2	Granulomatous Lymphadenitis Without Necrosis	78
3	Reactive Lymphoid Hyperplasia	72
4	Metastatic Carcinomatous Deposit	52
5	Lymphoma	4
6	Non-Specific Lymphadenitis	10

4(1.25%) cases as lymphoproliferative disorder, 10(3.14%) cases as nonspecific lymphadenitis. In cases with granulomatous lymphadenitis without necrosis diagnosis of tuberculosis was established by AFB positivity. 38(48.7%) out of 78 patients does not show AFB positivity, diagnosis in these cases was based on rapid response to empirical ATT started after FNAC report along with clinical correlation such as imaging studies, positive clinical history and positive mantoux test.

Table 3: Sex wise disease distribution

Male patients	Female patients
130	188

In our study, 130(40.88%) cases are found to be male patients and 188(59.12%) female patients. Out of the male patients 30 cases (23.07%) and 116(61.7%) cases of female patients were diagnosed as tuberculous lymphadenitis

Table 4: Male patients analysis

Tuberculosis Lymphadenitis	Reactive Hyperplasia
30	100

Table 5: Female patients analysis

Tuberculosis Lymphadenitis	Reactive Hyperplasia
116	72

Table 6: Adult patients analysis

Tuberculosis Lymphadenitis	166
Reactive Lymphoid Hyperplasia	36
Metastatic Carcinomatous Deposit	52
Others	14

Table 7: Pediatric patients analysis

Tuberculosis Lymphadenitis	14
Reactive Lymphoid Hyperplasia	36

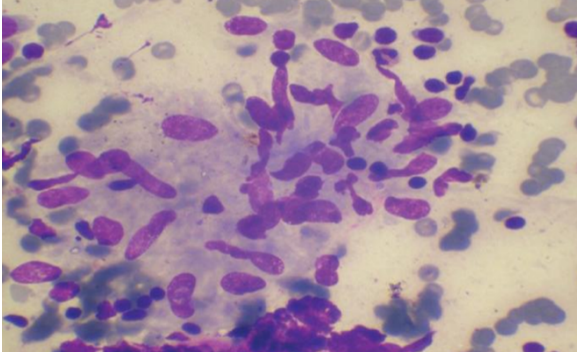


Fig. 1: Granulomatous Lymphadenitis, MGG Stain, 40X (High Power)

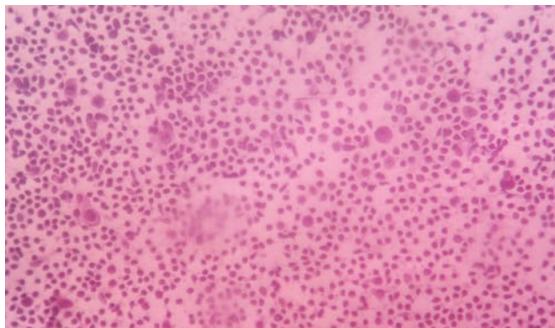


Fig. 2: Reactive Lymphadenitis, H&E Stain, 40X (High Power)

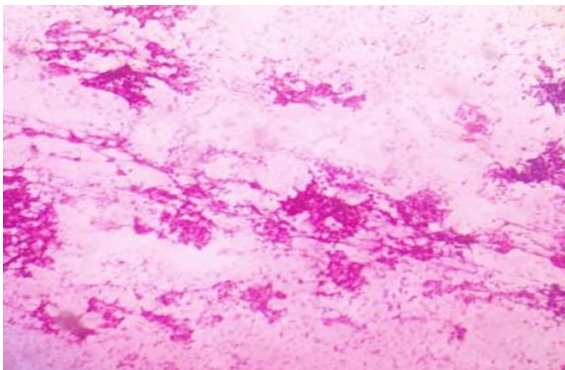


Fig. 3: Metastatic carcinomatous deposit in Lymphnode, H&E Stain, 10X (Low Power)

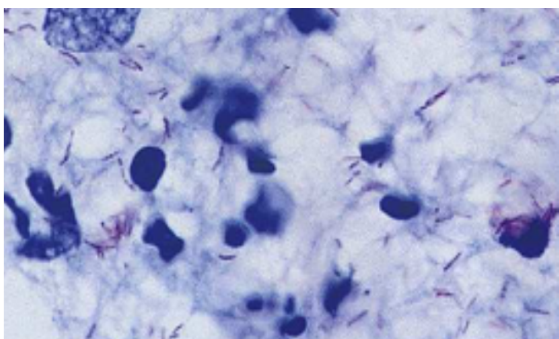


Fig. 4: Smear showing AFB Positivity, 40X (High Power)

5. Discussion

Out of 318 cases of FNAC performed in patients with enlarged cervical nodes, 50 (15.7%) cases belong to pediatric age group (<15 yrs) and 268 (84.3%) cases belong to adult age group. The youngest patient involved in our study is one year four months old and most elderly patient in our study is 83 years old.^{16–18}

Out of total 318 cases, 102 (32%) cases were diagnosed as caseating granulomatous lymphadenitis, 78 (24.5%) cases diagnosed as granulomatous lymphadenitis without necrosis, 52 (16.3%) cases as metastatic carcinomatous deposit where squamous cell carcinomatous deposit is the leading cause, 72 (22.6%) as reactive lymphoid hyperplasia, 4 (1.25%) cases as lymphoproliferative disorder, 10 (3.14%) cases as nonspecific lymphadenitis. Majority of our studied cases were found to be tuberculous lymphadenitis, which correlates well with study conducted by Shahid et al. 2010 which shows 69% incidence of tuberculous lymphadenitis.^{19–21}

Gupta et al., 2003 in their study shows 59% as granulomatous lymphadenitis. Much higher incidence must be attributed to two factors such as 1. this study was carried out in a tertiary care referral hospital 2. Our institute is attached to Perundurai TB sanatorium, one of the largest regional referral centers for defaulters relapse and multidrug resistant cases.

In our study, 130 (40.88%) cases are found to be male patients and 188 (59.12%) female patients. Out of the male patients 30 cases (23.07%) and 116 (61.7%) cases of female patients were diagnosed as tuberculous lymphadenitis. This correlates well with study done by Saira et al., 2011 which shows tuberculous lymphadenitis were more common in female patients (75%) as compared to male patients (25%).

The most frequent cause in adults was found to be tuberculous lymphadenitis (166 cases) followed by metastatic carcinomatous deposits (52 cases), whereas in pediatric patients the most common cause was found to be reactive lymphoid hyperplasia (36 cases) followed by tuberculous lymphadenitis (14 cases). Agarwal et al., 2010 in their study showed reactive lymphoid hyperplasia (70.9%) as predominant cause of pediatric lymphadenopathy.^{22,23}

In our study incidence of malignant lymphoma is 1.25%. Ahamed et al., also reported 4.5% cases as malignant lymphoma in their study. They consider the lower incidence of lymphoma is due to the fact that their study included mainly children.

Tuberculosis is a serious chronic pulmonary and systemic disease caused most often by M-Tuberculosis. Enlarged cervical lymph nodes is one of the most common extrapulmonary manifestation in tuberculosis. Every year millions of new cases are reported worldwide and India ranks first in the incidence of new cases in tuberculosis. In 2018, an estimated 10 million people fell ill with TB

worldwide, India has the highest burden with estimated incidence of 2.2 million cases. Ending TB epidemic by 2030 is among the health target. Hence early diagnosis and prompt treatment is essential for control of mortality rate among tuberculosis patients, thus FNAC seems to have central role in both screening, evaluation and follow-up of patients with enlarged cervical lymphnodes. Hafez NH et al concluded the same in their study.

6. Conclusion

In our study was conducted in a tertiary care hospital, the most common cause of cervical lymphadenopathy in adults was found to be tuberculous lymphadenitis followed by reactive lymphoid hyperplasia whereas in case of pediatric cases the most common cause of cervical lymphadenopathy is reactive lymphoid hyperplasia closely followed by tuberculous lymphadenitis. As per WHO –Sustainable development goals-to end TB epidemic in 2030-this study alarms the increasing burden on health sector in fighting against mycobacterium. FNAC is particularly efficacious in our country where mycobacterial infection is endemic, thereby reducing the time for other surgical procedures and delay in starting treatment. Hence early intervention is mandatory.

7. Source of funding

None.

8. Conflict of interest

None.

References

- Hirachand S, Lakhey M, Akhter J, Thapa B. Evaluation of fine needle aspiration cytology of lymph nodes in Kathmandu Medical College, Teaching hospital. *Kathmandu Univ Med J.* 2009;7(26):139–142.
- Keith VE, Harsharan SK, Jerald GZ. Fine needle aspiration biopsy of lymph nodes in the modern era: reactive lymphadenopathies. *Pathol Case Rev.* 2007;12(1):27–35.
- Das DK. Value and limitation of fine-needle aspiration cytology in diagnosis and classification of lymphomas: a review. *Diagn Cytopathol.* 1999;21:240–249.
- Haque MA, Talukder SI. Evaluation of fine needle aspiration cytology of lymph node in Mymensingh. *Mymensingh Med J.* 2003;12(1):33–35.
- Raghuveer CV, Leekha IL, Pai MR, Adhikari P. Fine needle aspiration cytology versus fine needle sampling without aspiration. A prospective study of 200 cases. *Indian J Med Sci.* 2002;56:431–439.
- Shakya G, Malla S, Shakya KN, Shrestha R. A study of fine needle aspiration cytology of cervical lymph nodes. *J Nepal Health Res Counc.* 2009;7(14):1–5.
- Jeffers MD, Milton J, Herriot R, McKean M. Fine needle aspiration cytology in the investigation on non-Hodgkin's lymphoma. *J Clin Pathol.* 1998;51(3):189–196. doi:10.1136/jcp.51.3.189.
- Saluja JG, Ajnyka MS. Comparative study of fine needle aspiration cytology, histology, and bacteriology of enlarged lymph node. *Bombay Hosp J.* 2000;42(2):1–7.
- Rakhshan M, Rakhshan A. The diagnostic accuracy of fine needle aspiration cytology in Neck lymphoid masses. *Iranian J Pathol.* 2009;4(4):147–150.
- Steel BL, Schwartz MR, Ibrahim R. Fine needle aspiration biopsy in the diagnosis of lymphadenopathy in 1,103 patients. *Acta Cytol.* 1995;39:76–81.
- Egea AS, Gronzalez M, Cohen JM. Usefulness of light microscopy in lymph node fine needle aspiration biopsy. *Acta Cytol.* 2002;46:368–369.
- Alwan NA, Hashimi AS, Salman MM, Attar EA. Fine needle aspiration cyto versus histopatho in diagnosing lymph node lesions. *East Mediterr Health J.* 1996;2(2):320–325.
- Khajuria R, Goswami KC, Singh K, Dudev VK. Pattern of lymphadenopathy on fine needle aspiration cytology in Jammu. *JK Sci.* 2006;8(3):145–149.
- Agarwal D, Bansal P, Ram. Evaluation of etiology of lymphadenopathy in different age groups using fine needle aspiration cytology; a retrospective study. *Int J Pathol.* 2010;10(2).
- Ahmed T, Naeem M, Ahmad S, Samad A, Nasir A. Fine needle aspiration cytology and neck swellings in the surgical outpatient. *J Ayub Med Coll.* 2008;p. 30–32.
- Cheng ATL, Dorman B. Fine needle aspiration cytology: the Auckland experience. *ANZ J Surg.* 1992;62(5):368–372. doi:10.1111/j.1445-2197.1992.tb07205.x.
- Fine needle aspiration cytology of head and neck masses. *Acta Cytol.* 47:387–192.
- Gupta RK, Naran S, Lallu S, Fauck R. The diagnostic value of fine needle aspiration cytology (FNAC) in the assessment of palpable supraclavicular lymph nodes: a study of 218 cases. *Cytopathology.* 2003;14(4):201–207. doi:10.1046/j.1365-2303.2003.00057.x.
- Kamal F, Niazi S, Nag AH, Jaradi MA, Naveed IA. Fine needle aspiration cytology (FNAC): an experience at King Edward Medical College, Lahore. *Pak J Pathol.* 1996;7:33–36.
- Lawrence C, Imad AH, Shara NMNM. Study of fine needle aspiration of head and neck masses. *Acta Cytol.* 2003;47:387–392.
- Russel RCG, William NS, Bulstrode CJK. Fine needle aspiration biopsy of head and neck lesions. *J Oral Maxillofac Surg.* 1991;49:262–267.
- Shahid F, Mirzat, Mustafa S, Sabahat S, Sharafat S. An experiential status of fine needle aspiration cytology of head and neck lesions in a tertiary care scenario. *J Basic Appl Sci.* 2010;6:159–162.
- Fernandes H, Souza CRS, Thejwasni BN. The role of fine needle aspiration cytology in palpable head and neck masses. *J Clin Diag Res.* 2009;3:1719–1725.

Author biography

Praba V Associate Professor

Sharmila G Assistant Professor

Cite this article: Praba V , Sharmila G . Tuberculosis is still the leading cause of cervical lymphadenopathy-results of a fnac analysis in a tertiary care hospital. *IP J Diagn Pathol Oncol* 2020;5(1):79-82.