



Original Research Article

Mucin histochemical profile in a variety of human colonic non-neoplastic and neoplastic lesions

Magdi Mansour Salih¹, Amal Abd El hafez^{2,*}, Basem Hassan El- Esawy^{2,3}

¹Dept. of Histopathology and Cytology, Faculty of Medical Laboratory Sciences, University of Khartoum, Khartoum, Sudan

²Dept. of Pathology, Faculty of Medicine, Mansoura University, Mansoura, Egypt

³Dept. of Medical Laboratories, College of Applied Medical Sciences, Taif University, Taif, Saudi Arabia

ARTICLE INFO

Article history:

Received 31-05-2019

Accepted 05-06-2019

Available online 20-9-2019

Keywords:

Adenocarcinoma

Acidic mucin

Colon

Histochemistry

Neutral mucin.

ABSTRACT

Introduction: Mucin deregulation occurs in gastrointestinal lesions progressing to cancer. Evidences advocate utility of mucin profile to predict malignant transformation in preneoplastic colonic lesions, however data are controversial.

Objectives: This clinicopathological descriptive study identifies the histochemical profiles of acidic and neutral mucins in human colonic tissues including inflammatory, non-neoplastic and neoplastic lesions. Mucin alteration in different histological grades of adenocarcinoma is also evaluated.

Materials and Methods: After collection of relevant data, tissue samples from a cohort of 88 patients recruited from King Abdul Aziz Specialized Hospital, Taif, Saudi Arabia were examined. Dual Alcian Blue (AB; pH 2.5)/ Diastase (D) Periodic Acid Schiff (PAS) technique was used to differentiate acidic and neutral mucins respectively. Statistical analysis including descriptive statistics, Pearson's chi-square test and linear regression was performed using SPSS.

Results: Acidic and neutral mucins were positive in 67.1 and 46.6% of lesions, respectively. All ulcerative colitis tissues were positive for acidic mucin and 75% for neutral mucin. All non-neoplastic polyps were positive for both mucins. Adenomatous polyps demonstrated reduced mucin but more neutral (59.3%) than acidic one (44.4%). About 86% of adenocarcinomas revealed acidic mucin and 22.2% showed neutral mucin with trends for acidic mucin to decrease with grade and for neutral mucin to increase with grade.

Conclusion: Altered both acidic and neutral mucin profiles occur in colonic lesions of different pathologies. As colonic adenocarcinoma progresses from grade 1 to grade 3, acid mucin declines with a corresponding increase in neutral mucin. Mucin profile may be of value in evaluating the preneoplastic colorectal lesions.

© 2019 Published by Innovative Publication.

1. Introduction

Epithelia are protected from the external environment by a mucus barrier composed largely of high-molecular-weight glycoproteins; the mucins. Mucins exhibit either secreted or transmembrane loci at the epithelial lining of the gastrointestinal and respiratory tracts and the duct linings in the pancreas, kidney, liver and mammary gland. Secreted mucins act as a physical barrier; however transmembrane mucins provide this physical barrier with ectodomains made up of O-glycosylated tandem repeats.^{1,2} For colonic

epithelium, mucus forms an adherent gelatinous sheet that protects the cells from injurious luminal contents including proteases, bile, ingested toxins and a substantial number of commensal bacteria.¹⁻³ The colon is now known to harbor a two-layered mucin system.² Through histochemical techniques, colonic mucins are categorized as highly glycosylated neutral mucins and less glycosylated acidic mucins which are, consecutively, subdivided into sialomucins and sulfomucins.^{4,5} Normal colonic tissue mucins are predominately acidic with scanty neutral mucin,⁶ and both can be sharply differentiated using Alcian blue (AB) and Periodic acid Schiff (PAS) special stains.^{7,8}

* Corresponding author.

E-mail address: amalabelhafez@gmail.com (A. Abd El hafez).

Deregulation of mucin has been reported in a variety of gastrointestinal tract lesions progressing to cancer.⁹ Carcinomas of esophagus, gastro-esophageal junction, breast, prostate, lung and pancreas commonly overexpress transmembrane mucins to exploit their role in promoting growth and survival.^{1,10} In this respect, altered mucin profile has been linked to changes in cell polarity and cell-stromal interaction.¹¹

Recent evidences advocate the utility of mucin expression to predict malignant transformation of preneoplastic colonic lesions.¹² However, only a few studies have examined the mucin profile in the premalignant lesions of the colon, such as adenomas and dysplasia in ulcerative colitis (UC) and the mucin profile in colorectal cancer (CRC) as well.¹³ Moreover, the data yield from these studies has been contradictory.^{8,14} In the Middle East,¹³ specifically in Kingdom of Saudi Arabia (KSA), the mucin expression profile of CRC is not well-known. To the best of our knowledge, there has been only one report that studied the impact of mucin production on the prognosis of patients with CRC.¹⁵

Therefore, this study is conducted with the aim of identifying the histochemical profiles of acidic and neutral mucins in a series of human colonic tissue samples including inflammatory lesions, non-neoplastic polyps, adenomatous polyps and adenocarcinomas. We also investigated mucin changes in relation to different grades of colonic adenocarcinoma.

2. Materials and Methods

This clinicopathological descriptive cohort study included 88 patients recruited retrospectively from King Abdul Aziz Specialized Hospital in Taif city, KSA during the period between December 2017 and February 2018. Patients' clinicopathological data, archived microscopic slides and tissue paraffin blocks were obtained from Pathology Department at the same hospital. Staining and study procedures were conducted at the Clinical Laboratory Sciences Department at College of Applied Medical Science, Taif city, KSA.

2.1. Inclusion and exclusion criteria

This study included biopsies from patients diagnosed with a variety of colonic and appendiceal lesions including inflammatory lesions (follicular appendicitis, suppurative appendicitis and ulcerative colitis); colonic non-neoplastic and adenomatous polyps and colonic adenocarcinomas. Patients who underwent endoscopic colonic biopsy, polypectomy, appendectomy or colectomy during the study period were enrolled in the study provided that their clinicopathological data and archival material required for histopathological examination were available for further study. Exclusion criteria were cases who received

preoperative chemotherapy or radiotherapy, incomplete records and unavailability of histopathological slides or paraffin tissue blocks.

2.2. Data collection

Relevant data were collected from patients' medical records at King Abdul Aziz Specialized Hospital in Taif city, KSA. Demographic and clinicopathological information including patient's age, gender, clinical presentation, endoscopic or surgical procedures, pathology reports including macroscopic features and histopathological diagnosis were gathered and tabulated. Subsequently, formalin fixed, paraffin embedded (FFPE) tissue blocks and hematoxylin and eosin (H&E) stained microscopic slides for 88 patients previously diagnosed with suppurative appendicitis; follicular appendicitis; ulcerative colitis; colonic non-neoplastic polyps; adenomatous polyps and colonic adenocarcinomas were retrieved from archival material of Pathology Department at King Abdul Aziz Specialized Hospital during the period from December 2017 to February 2018.

2.3. Histochemical staining

Tissue sections cut at 3 to 4 μm were prepared from each FFPE tissue block. The sections has been deparaffinized and rehydrated in a graded series of alcohol then submitted for dual staining with Alcian Blue (AB) at pH 2.5 and Diastase (D) pretreated Periodic Acid Schiff (PAS) to demonstrate acidic and neutral mucins, respectively. The AB; 2.5/DPAS technique was implemented using the standard protocols.^{7,14} Histologically adjacent normal tissue from the margins of the tumors served as a control tissue.

2.4. Slide examination and evaluation of staining

The routinely prepared H&E-stained slides obtained from archival material were reviewed and re-evaluated by two pathologists to confirm the diagnosis of each. Colorectal adenocarcinomas were classified as grade 1, grade 2 and grade 3 using the WHO criteria. Slides stained with AB; 2.5/DPAS were independently assessed by two pathologists. The nature of mucin was analyzed by evaluating 5 randomly selected fields at 100x magnification. The neutral mucins stained magenta, while the acidic mucins stained blue.

2.5. Data analysis

After coding and tabulation of the collected data, statistical analysis was performed using Statistical Package for the Social Sciences (SPSS) program version 18.0. Descriptive statistics were done and data were expressed as numbers and percentages. Pearson's chi-squared test (χ^2) was used to assess the difference between groups. Linear regression

analysis at 95% confidence interval was performed to find out the trend of acidic and neutral mucins in relation to the histological grades of colonic adenocarcinomas. A p value of 0.05 or less was considered as statistically significant.

2.6. Ethical considerations

Conduction of this study was retrospect and has not influenced any biopsy or operative decision. The study was conducted upon approval of the local ethical committee at College of Applied Medical Science, Taif city, KSA. After being oriented about the study purpose, informed consents were obtained from the patients or their relatives to access their data and use their archived microscopic slides and tissue specimens. All procedures were followed in accordance with the current revision of Helsinki Declaration.

3. Results

As detailed in (Table 1), the study included 88 patients ranging in age from 5 to 100 years. Most patients (29.5%) were included in the age group from 41 to 60 years. About 61% of patients were males and the remainder was females. The histopathological diagnoses of the study cases comprised: acute suppurative and follicular appendicitis (11.4% and 8% respectively); ulcerative colitis (4.5%); non-neoplastic and adenomatous polyps of the colon (4.5% and 30.7% respectively) and colonic adenocarcinomas (40.9%). Tissue samples were obtained by a variety of procedures including appendectomy; endoscopic biopsy; polypectomy and colectomy. There was a significant statistical difference when either age groups or tissue sampling procedures were compared to the histopathological diagnosis (p values of 0.002 and ≤ 0.0001 respectively).

The histochemical profile of acidic and neutral mucins for the 88 studied appendiceal and colonic lesions is demonstrated in table 2, based on the histopathological diagnosis (Figure 1). Acidic mucin was positive in 67.1% of lesions, while neutral mucin positivity was demonstrated in 46.6% of examined tissues. Appendiceal lesions revealed a positivity of 57.1% for both acidic and neutral mucins in follicular appendicitis and a slightly higher neutral mucin (60%) in appendixes with suppurative pathology. For ulcerative colitis, all cases demonstrated acidic mucin and 3 out of 4 cases revealed positivity for neutral mucin. All non-neoplastic polyps were positive for both acidic and neutral mucins. Overall, adenomatous polyps demonstrated reduced mucin content but neutral mucin was more frequently positive (59.3% of cases) than acidic mucin (44.4% of cases). On the contrary, adenocarcinomas (Figure 2) were overall predominately positive for acidic mucin (86.1%) and less frequently positive for neutral mucin (22.2%).

When acidic and neutral mucin profiles were compared to different histological grades of colonic adenocarcinoma (Table 3), almost 94.7 % of grade 1 adenocarcinomas demonstrated positive staining for acidic mucin with a trend of the staining frequency to decrease in progression from grade 1 to grade 3 (71.4%) (Figure 3 ; left panel). Conversely, neutral mucins were demonstrated in a distinctly lower number of grade 1 adenocarcinomas (10.5%), with a trend of the staining frequency to increase up to 42.8% in grade 3 adenocarcinomas (Figure 3; right panel). Yet, linear regression analysis at 95% confidence interval revealed insignificant p values for both acidic and neutral mucins despite that the data are fitted to the regression line (R square values of 0.9777 and 0.9859 respectively).

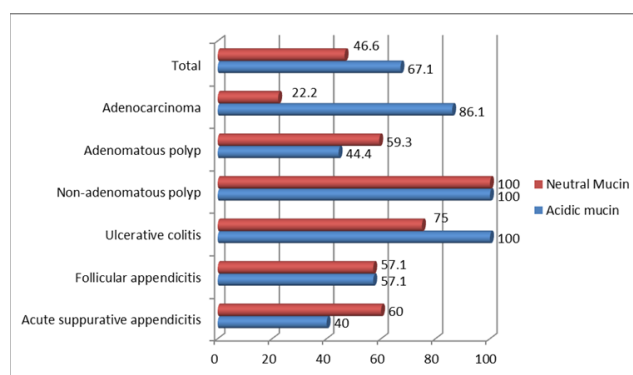


Fig. 1: Distribution of acidic and neutral mucins according to the histopathological diagnosis of colonic and appendiceal lesions

4. Discussion

Colorectal cancer (CRC) is the third most common cancer worldwide among both males and females. It constitutes 6.1% of the overall cancer incidences and 9.2% of mortalities.¹⁶ In Saudi Arabia, CRC accounts for 11.9% of diagnosed cancers being the second commonly occurring cancer among Saudi populations with the main burden on older population (median age of 60 years for males and 56 years for females).^{2,17,18}

The traditionally known colonic precancerous pathological lesions include dysplastic ulcerative colitis, aberrant crypt foci (ACF) and colonic adenomas including the serrated ones.^{12,19,20} Lately, the concept that hyperplastic polyps and mixed polyps are entirely innocuous lesions has been reverted.⁹ Moreover, mucin-depleted foci (MDF) have been recognized to serve as preneoplastic lesions of CRC that can be used as a biomarker in colon carcinogenesis.^{20,21} Hence, recent evidences advocate the utility of mucin expression to predict malignant transformation of colonic preneoplastic lesions.¹² Based on this assumption, the current study was designated to assess acidic and neutral mucin profiles in a variety of human colonic non-neoplastic and neoplastic lesions including those of the appendix

Table 1: The clinicopathological characteristics of the 88 cases included in the study

Variable	Histopathological Diagnosis						Total	* P value
	Acute suppurative appendicitis	Follicular appendicitis	Ulcerative colitis	Non-neoplastic polyp	Adenomatous polyp	Adenocarcinoma		
Age								
≤20 y	4(40%)	5(71.4%)	0(0%)	1(25%)	0(0%)	0(0%)	10(11.4%)	0.002
21-40y	5(50%)	1(14.3%)	1(25%)	1(25%)	3(11.1%)	10(27.8%)	21(23.9%)	
41-60 y	0(0%)	0(0%)	2(50%)	1(25%)	8(29.6%)	15(41.7%)	26 (29.5%)	
61-80 y	1(10%)	1(14.3%)	1(25%)	1(25%)	14(51.9%)	5(13.9%)	23(26.1 %)	
≥81 y	0 (0%)	0 (0%)	0 (0%)	0(0%)	2(7.4%)	6(16.7%)	8(9.1 %)	
Gender								
Male	7(70%)	2(28.6%)	2(50%)	2(50%)	20(74.1%)	21(58.3%)	54(61.4%)	0.238
Female	3(30%)	5 (71.4%)	2(50%)	2(50%)	7(25.9%)	15(41.7%)	34(38.6%)	
Sampling procedure								
Appendectomy	10(58.8%)	7(41.2%)	0(0%)	0(0%)	0(0%)	0(0%)	17(19.3%)	≤0.0001
Endoscopic biopsy	0(0%)	0(0%)	4(100%)	0(0%)	0(0%)	0(0%)	4(4.5%)	
Polypectomy	0(0%)	0(0%)	0(0%)	4(12.9%)	27(87.1%)	0(0%)	31(35.2%)	
Colectomy	0(0%)	0(0%)	0(0%)	0(0%)	0(0%)	36(100%)	36 (40.9%)	
Total	10(11.4%)	7(8%)	4(4.5%)	4(4.5%)	27(30.7%)	36(40.9%)	88 (100.0%)	

* Pearson Chi-square p-value is significant at $p < 0.05$.

Table 2: Acidic and neutral mucin profiles distributed by the histopathological diagnosis of the 88 cases included in the study

Mucin type	Acute suppurative appendicitis (n; 10, 11.4%)	Follicular appendicitis (n; 7, 8%)	Ulcerative colitis (n; 4, 4.5%)	Non-neoplastic polyp (n; 4, 4.5%)	Adenomatous polyp (n; 27, 30.7%)	Adenocarcinoma (n; 36, 40.9%)	Total (n; 88, 100%)
Acidic	4(40%)	4(57.1%)	4(100%)	4(100%)	12(44.4%)	31(86.1%)	59(67.1%)
Neutral	6(60%)	4(57.1%)	3(75%)	4(100%)	16(59.3%)	8(22.2 %)	41(46.6%)

*Pearson Chi-square p-value is < 0.0001 . The result is significant at $p < 0.05$, n; number.

Table 3: Acidic and neutral mucin profiles distributed by the histopathological grade of the 36 colonic adenocarcinomas included in the study

Mucin type	Grade 1 (n; 19, 52.7%)	Grade 2 (n; 10, 27.8%)	Grade 3 (n; 7, 19.4%)	Total (n; 36, 100%)	P value *	R square **
Acidic	18(94.7%)	8(80%)	5(71.4%)	31(86.1%)	0.0955	0.9777
Neutral	2(10.5 %)	3(30%)	3(42.8%)	8(22.2 %)	0.0759	0.9859

n; number,* Linear regression analysis at 95% confidence interval. The result is significant at $p < 0.05$, ** R square close to 1 indicates that the regression predictions perfectly fit the data.

using mucin histochemical staining. In addition, the mucin profile was compared in different grades of colonic adenocarcinoma. In order to achieve this, tissues from 88 patients diagnosed with different colonic and appendiceal lesions were enrolled in the study. Overall, the AB; 2.5/DPAS technique revealed that the acidic mucin is more frequently positive in colonic lesions than neutral mucin. Inflammatory lesions of the appendix as well as UC revealed increased neutral mucin and reduced acidic mucin as compared to normal colon. Neutral mucins were

identified in 75% of UC tissues, which was quite higher than neutral mucin positivity in other colonic lesions such as adenomatous polyps and adenocarcinomas. Previous studies have demonstrated a change in mucin secretion in chronic inflammatory conditions of the colon. In inflamed colonic mucosa, there seem to be differences in the mucin structure as a result of reactive oxygen species-mediated injury and the associated process of mucosal repair dominated with increased epithelial turnover.^{19,22} Thus, evidences suggest that the thickness and effectiveness

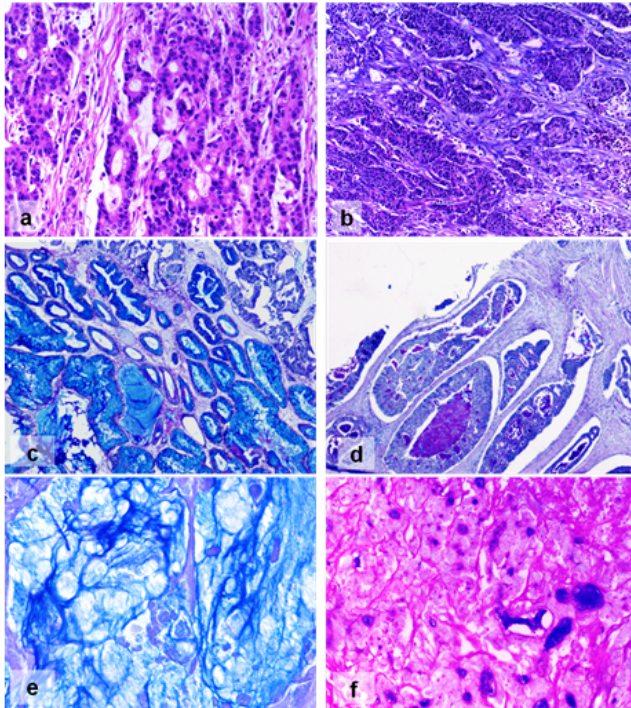


Fig. 2: Adenocarcinomas of the colon. Grade 1 (H&E, 200x) (a); Grade 3 (H&E, 100x) (b); Adenocarcinoma with blue acidic mucin (AB; 2.5/DPAS, 200x) (c); Adenocarcinoma with magenta luminal neutral mucin and scanty blue acidic mucin (AB; 2.5/DPAS, 250x) (d); Mixed acidic and neutral mucins with prevalence of extracellular acidic mucin (AB; 2.5/DPAS, 400x) (e); Grade 3 adenocarcinoma with prevalence of neutral magenta mucin (AB; 2.5/DPAS, 400x) (f)

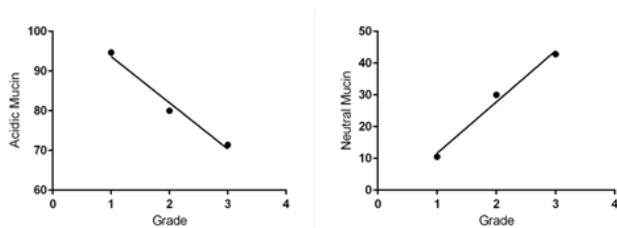


Fig. 3: Linear regression analysis curve at 95% confidence interval showing decline of acidic mucin (left panel) and increase of neutral mucin (right panel) positivity during progression from grade 1 to grade 3 colonic adenocarcinoma

of the mucus barrier are reduced in UC.¹⁹ The question remains, however, as to whether a primary defect in epithelial mucin could be a factor in the etiology of UC. Altered glycosylation of mucin side-chains and changed expression of core proteins at transcriptional, translational or post-translational levels have also been assumed to occur in inflammatory bowel diseases.⁹

In the present study, both mucin types were detected in all cases of non-adenomatous polyps. While conventional

knowledge claims that hyperplastic polyps and mixed polyps show a reduction in the ratio of goblet cells to columnar cells, a recent evidence indicates that the so called columnar cells constitute the source of excess mucin due to mucin gene up-regulation in this subset of cells.⁹

Adenomatous polyps showed a reversed mucin profile when compared to normal colon, as neutral mucin was more frequently detected (59.3%) than acidic mucin. In adenomas, increased neutral mucin could be explained by the arrested maturation of crypt differentiation to recapitulate crypt base.⁹ It is well known that goblet cells with neutral mucins are present in the lower two-thirds of the crypts in the caecum and the colon.²³ A preceding study considered this change in mucin production as a marker to identify precursor lesions in adenoma- carcinoma sequence of colorectal carcinogenesis.¹² Additionally, changes in mucin glycosylation and distribution were found to play an important role in the same sequence.¹³ On the contrary, adenocarcinomas in this study recapitulated the normal colonic tissue that demonstrates predominance of acidic mucin (80%) and scantiness of neutral mucin (20%).¹⁴ Similarly, an earlier study performed to assess the histochemical composition of mucin in CRC indicated the presence of acidic and neutral mucin mixed secretions with a peculiar prevalence of acidic ones (more than 80%).²⁴

A former study including patients from Saudi Arabia demonstrated the role colonic mucin alteration in the progression of CRC.¹⁵ Nevertheless, an important finding brought in the current study is the trend of acidic and neutral mucins to change by the grade of colonic adenocarcinoma. Acidic mucin revealed a trend to be high in grade 1 lesions (94.7%) and to decrease in frequency with increasing tumor grades. Conversely, neutral mucin was detected in 10.5% of grade 1 adenocarcinomas, but demonstrated a trend to increase in higher adenocarcinoma grades. This mucin profile in CRC could be related to midgut epithelial metaplasia affecting neoplasms of the distal large bowel.⁹ A recent comparable study revealed also a general decline in the acidic mucin as the adenocarcinomas of the colon progress from the well-differentiated adenocarcinoma (73.3%) through the moderately differentiated and poorly differentiated adenocarcinomas (63.7%), whilst there was a corresponding upsurge in the positivity of neutral mucins (26.3% and 36.3% respectively), but the authors reported an opposing pattern in a small subpopulation of the high-grade colonic cancers.¹⁴ In this context, acidic mucins have been suggested to inhibit tumor growth,²⁵ and to be involved in the control of cell division. Therefore, a down regulation of acidic mucin expression is suggested to drive the colonic tissue to malignancy.¹⁴ In contrast to our findings, Jain, et al.⁸ reported increased secretion of mostly acidic mucin and also neutral mucin in CRC and Ali et al.⁷ demonstrated positivity for acidic mucin and negativity for neutral mucin in all cases of CRC. Differences may be attributed to the

various pathways of neoplastic progression that contribute to the molecular and biological heterogeneity exhibited by CRCs.¹² The on/off switching of gastrointestinal mucin genes could be a biomarker for genetic instability, thereby explaining the associations with gastrointestinal neoplasia.⁹

5. Conclusion

In this study, altered acidic and neutral mucin profiles has been demonstrated in a variety of non-neoplastic and neoplastic lesions from the colon. A decline of acid mucin from grade 1 to grade 3 adenocarcinoma of the colon with a corresponding increase in neutral mucins was documented in this work. Determination of mucin profile may be of value in evaluating the preneoplastic colorectal lesions. Future efforts are warranted to determine the utility of mucin profile in risk stratification of different colonic lesions to enhance early stage management of this malignancy.

6. Acknowledgments

The authors' institutions are acknowledged.

7. Compliance with Ethical Standards

8. Ethical Statement

The study was conducted following the aforementioned ethical considerations.

9. Conflict of Interest

The authors declare that they have no conflict of interest.

References

- Kufe DW. Mucins in cancer: Function, prognosis and therapy. *Nat Rev Cancer*. 2009;9:874–85. Available from: [10.1038/nrc2761](https://doi.org/10.1038/nrc2761).
- Pelaseyed T, Bergström JH, Gustafsson JK, Ermund A, Birchenough GM, et al. The mucus and mucins of the goblet cells and enterocytes provide the first defense line of the gastrointestinal tract and interact with the immune system. *Immunol Rev*. 2014;260(1):8–20. Available from: [10.1111/imr.12182](https://doi.org/10.1111/imr.12182).
- Finnie IA, Dwarakanath AS, Taylor BA, Rhodes JM. Colonic mucins synthesis is increased by sodium butyrate. *Gut*. 1995;36(1):93–9.
- Wesley A, Mantle M, Man D, Qureshi R, Forstner G, et al. Neutral and acidic species of human intestinal mucin. Evidence for different core peptides. *J Biol Chem*. 1985;260(13):7955–9.
- Castro MA, Ferreira U, Martins MH, Stoppiglia RM, Junior NRN, et al. Histological and histochemical changes of the intestinal mucosa at the urothelial-enteric anastomotic site. *Int Braz J Urol*. 2006;32(2):222–7. Available from: [.org/10.1590/S1677-55382006000200017](https://doi.org/10.1590/S1677-55382006000200017).
- Subbuswamy S. Mucosubstances in neoplasms of the human colon and rectum. *Gut*. 1971;12(3):200–7.
- Ali U, Nagi AH, Naseem N, Ullah E. Mucin histochemistry in tumors of the colon, ovaries and lung. *J Cytol Histol*. 2012;3(7):1–4. Available from: [.org/10.4172/2157-7099.1000163](https://doi.org/10.4172/2157-7099.1000163).
- Jain P, Monda SK, Sinha SK, Mukhopadhyay M, Chakraborty I. Diagnostic and prognostic significance of different mucin expression, preoperative CEA, and CA-125 in colorectal carcinoma: A clinicopathological study. *J Nat Sci Bio Med*. 2014;5(2):404–8. Available from: [10.4103/0976-9668.136207](https://doi.org/10.4103/0976-9668.136207).
- Jass JR, Walsh MD. Altered mucin expression in the gastrointestinal tract: a review. *J Cell Mol Med*. 2001;5(3):327–51. Available from: [.org/10.1111/j.1582-4934.2001.tb00169.x](https://doi.org/10.1111/j.1582-4934.2001.tb00169.x).
- Vernygorodskiy S, Rekun T, Zhuchenko P. Comparative histochemical evaluation of mucins expression in fetal esophagus and adenocarcinomas of the gastroesophageal junction. *Exp Oncol*. 2018;40(3):223–7.
- Adsay NV, Merati K, Nassar H, Shia J, Sarkar F, et al. Pathogenesis of colloid (pure mucinous) carcinoma of exocrine organs: Coupling of gel-forming mucin (MUC2) production with altered cell polarity and abnormal cell-stroma interaction may be the key factor in the morphogenesis and indolent behavior of colloid carcinoma in the breast and pancreas. *Am J Surg Pathol*. 2003;27(5):571–8.
- Krishn SR, Kaur S, Smith LM, Johansson SL, Jain M, et al. Mucins and associated glycan signatures in colon adenoma-carcinoma sequence: Prospective pathological implication(s) for early diagnosis of colon cancer. *Cancer Lett*. 2016;374(2):304–14. Available from: [10.1016/j.canlet.2016.02.016](https://doi.org/10.1016/j.canlet.2016.02.016).
- Xu F, Fan C, Fan S, Liu F, Wen T, et al. Expression profile of mucin-associated sialyl-Tn antigen in Chinese patients with different colorectal lesions (adenomas, carcinomas). *Int J Clin Exp Pathol*. 2015;8(9):11549–54.
- Danquah KO, Adjei E, Quayson S, Adankwah E, Gyamfi D, et al. Mucin expression patterns in histological grades of colonic cancers in Ghanaian population. *Pan Afr Med J*. 2017;27:267. doi: 10.11604/pamj.2017.27.267.9793. eCollection 2017. Available from: "https://www.dx.doi.org/10.11604/pamj.2017.27.267.9793" doi:10.11604/pamj.2017.27.267.9793. *Pan Afr Med J*. 2017;27:267. Available from: [10.11604/pamj.2017.27.267.9793](https://doi.org/10.11604/pamj.2017.27.267.9793)..
- Al-Khayal K, Abdulla M, Al-Obaid O, Zubaidi A, Vaali-Mohammed MA, et al. Differential expression of mucins in Middle Eastern patients with colorectal cancer. *Oncol Lett*. 2016;12(1):393–400. Available from: [10.3892/ol.2016.4672](https://doi.org/10.3892/ol.2016.4672).
- Bray F, Ferlay J, Soerjomataram I, Siegel RL, Torre LA, et al. Global cancer statistics 2018: GLOBOCAN estimates of incidence and mortality worldwide for 36 cancers in 185 countries. *CA Cancer J Clin*. 2018;68(6):394–424. Available from: [10.3322/caac.21492](https://doi.org/10.3322/caac.21492).
- Al-Madouj AN, Alshahrani ZS, Alrawaji AI, Hayder MS, Al-Shridah MM, Al-Shamrani TH. Kingdom of Saudi Arabia Saudi Health Council Saudi Cancer Registry of 2016. Cancer Incidence Report Saudi Arabia 2013. Available from: <https://nhic.gov.sa/eServices/Documents/2013.pdf> [Accessed 8th March 2018] ;.
- Alsanea N, Abduljabbar AS, Alhomoud S, Ashari LH, Hibbert D, et al. Colorectal cancer in Saudi Arabia: incidence, survival, demographics and implications for national policies. *Ann Saudi Med*. 2015;35(3):196–202. Available from: [10.5144/0256-4947.2015.196](https://doi.org/10.5144/0256-4947.2015.196).
- Shirazi T, Longman RJ, Corfield AP, Probert C. Mucins and inflammatory bowel disease. *Postgrad Med J*. 2000;76:473–8.
- Sakai E, Morioka T, Yamada E, Ohkubo H, Higurashi T, et al. Identification of preneoplastic lesions as mucin-depleted foci in patients with sporadic colorectal cancer. *Cancer Sci*. 2012;103(1):144–9. Available from: [10.1111/j.1349-7006.2011.02125.x](https://doi.org/10.1111/j.1349-7006.2011.02125.x).
- Yoshimi N, Morioka T, Kinjo T, Inamine M, Kaneshiro T, et al. Histological and immunohistochemical observations of mucin-depleted foci (MDF) stained with Alcian blue, in rat colon carcinogenesis induced with 1,2-dimethylhydrazine dihydrochloride. *Cancer Sci*. 2004;95(10):792–7. Available from: [10.1293/tox.2013-0028](https://doi.org/10.1293/tox.2013-0028).
- Brownlee I, Knight J, Dettmar PW, Pearson JP. Action of reactive oxygen species on colonic mucus secretions. *Free Radic Biol Med*. 2007;43(5):800–8. Available from: [800-808.d:10.1016/j.freeradbiomed.2007.05.023](https://doi.org/10.1016/j.freeradbiomed.2007.05.023).
- Greco V, Lauro G, Fabbri A, Torsoli A. Histochemistry of the colonic epithelial mucins in normal subjects and in patients with ulcerative colitis A qualitative and histophotometric investigation. *Gut*. 1967;8:491–6.
- Ionil M, Mrgitescu CL, Pirici D, Mogoant SS. Mucinous adenocarcinoma of the colon-a histochemical study. *Rom J Morphol Embryol*. 2011;52(3):783–90.

25. M L. A proposed role for mucopolysaccharides in the initiation and control of cell division. *Trans NY Acad Sci.* 1965;27:342–60.

Basem Hassan El- Esawy Faculty of Medicine

Author biography

Magdi Mansour Salih Faculty of Medical Laboratory Sciences

Amal Abd El hafez Faculty of Medicine

Cite this article: Salih MM, Abd El hafez A, El- Esawy BH. Mucin histochemical profile in a variety of human colonic non-neoplastic and neoplastic lesions. *J Diagn Pathol Oncol* 2019;4(3):159-165.