

A rare vascular lesion of the breast

Durga Devi S^{1*}, Jayaganesh P²

¹Post Graduate, ²Associate Professor, ^{1,2}Dept. of Pathology, ^{1,2}Saveetha Medical College and Hospital, Saveetha Nagar, Thandalam, Kancheepuram, Chennai, Tamil Nadu, India

***Corresponding Author: Durga Devi S**

Email: durdoc0409@gmail.com

Abstract

Introduction: Breast angiosarcoma is an unusual malignancy accounting for 1% of all soft tissue sarcomas. It occurs in both a primary form and a secondary form that has been associated with a history of irradiated breast tissue. This malignant vascular tumour occurs primarily in young women. Epithelioid angiosarcoma, which is a rare aggressive variant of angiosarcoma, arises in the deep soft tissues of the extremities, thyroid gland, skin, adrenal glands, and bone can also be involved. Adverse prognostic factors include advanced age, increased tumor size, retroperitoneal primary site, and an increased proliferative index (MIB >10%). Immunostaining for factor VIII-related antigen, CD31 and CD34 helps with the diagnosis of angiosarcoma of the breast. The prognosis of breast angiosarcoma is poor. Here we report a rare case of 37 year old female presented with swelling of left breast with rapid growth of the tumour. Trucut biopsy was done at the time of diagnosis and thereafter underwent mastectomy and diagnosed as Angiosarcoma of the breast which was then confirmed by CD34 Immunohistochemistry.

Keywords: Epithelioid angiosarcoma, CD 34, Breast malignancy.

Case Report

A 37 year old premenopausal woman presented with a 4 months history of lump in the left breast which was progressively increasing in size with pain and redness. A trucut biopsy was done outside suggestive of Angiosarcoma left breast. Patient was referred to surgery OPD at our hospital. No history of radiation. On physical examination, the lump was 15x15cm involving all the quadrants, soft to firm in consistency which was fixed to the underlying structure. Overlying skin was stretched and no axillary or supraclavicular nodes were palpable. The contralateral breast and axilla were found to be normal. CT-Thorax was done showing a large lobulated soft tissue mass lesion involving all the quadrants with multiple satellite nodules and extensive skin thickening. Left breast mastectomy was done with 2cm skin clearance and specimen sent for histopathological examination. Grossly, the lesion was ill-defined and haemorrhagic measuring 8x7x2cm seen centrally and in the lower outer quadrant with spongy consistency. Microscopy revealed a high grade malignancy of epithelioid morphology infiltrating the fibro collagenous stroma. Round to elongated cells with moderate to abundant eosinophilic cytoplasm with central ovoid vesicular nuclei and prominent nucleolus. Anastomosing vascular channels seen with focal areas of haemorrhage and necrosis. Mitotic figures noted. CD34 immunohistochemical staining showed 100% strong positivity in the tumour cells. Ductal epithelial markers were not demonstrated.

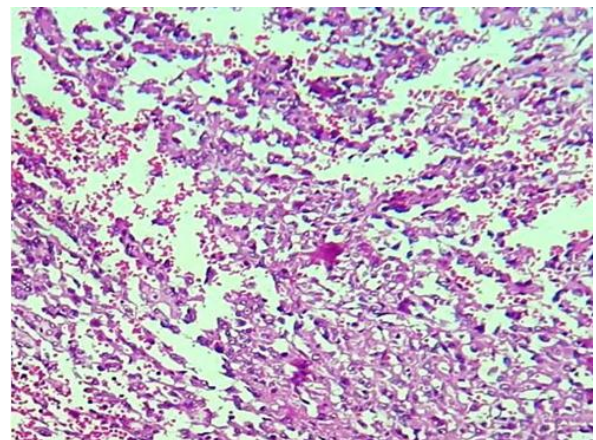


Fig. 1. Low power photomicrograph (10X) of the infiltrating malignant tumour cells.

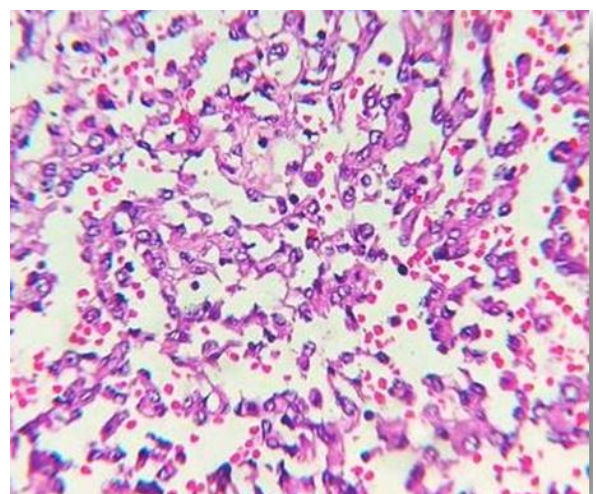


Fig. 2: High power photomicrograph (40X) shows anastomosing vascular channels surrounded by cells of epithelioid morphology

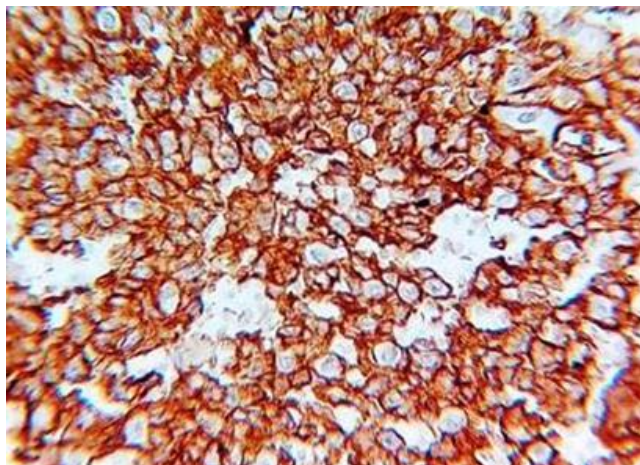


Fig. 3: High power photomicrograph (40X) shows CD34 strong positivity in the tumour cells.

Discussion

Angiosarcomas are rare malignancies of endothelial origin lining the vascular channels. These neoplasms account for 1% of all the soft tissue tumours.¹ They range from well differentiated tumours to high grade malignancies with variable endothelial cell atypia. Epithelioid angiosarcoma is a rare variant which predominantly possess an epithelioid appearance in contrast to the conventional type of angiosarcoma. The primary sites that has been documented in the previous studies are in soft tissues, thyroid gland, skin, adrenal gland and bone, the most common being the deep soft tissues of the extremities.² The tumour commonly presents in the young women (20-50 years)³ and also has a male predilection. Epithelioid angiosarcoma of breast possess a variety of clinical presentations depending upon the two entities 1) primary site^{4,5} and 2) aggressiveness of the tumour. The tumour may range from a small lump to a large haemorrhagic mass leading to long bone fractures when there is bony involvement.

Microscopically, Epithelioid angiosarcoma of breast composed of large round to polygonal epithelioid cells with moderate to abundant eosinophilic or amphophilic cytoplasm. The neoplastic cells show mild to moderate pleomorphism with centrally placed vesicular nuclei with prominent nucleoli. The tumour is arranged in sheets, islands, nests and cords architecturally. An irregularly anastomosing vessel formation is usually a common feature in epithelioid angiosarcoma. Increased mitotic activity with areas of necrosis and haemorrhage is usually noted. The malignant endothelial cells may sometimes present with intracytoplasmic lumina containing erythrocytes which helps in the diagnosis of this vascular lesion.

The differential diagnosis includes Ductal carcinoma of breast due to its solid growth pattern morphology, poorly differentiated sarcomas, melanoma, epithelioid hemangioendothelioma and other metastatic or primary malignancies.⁶ Immunohistochemistry plays an important role in aiding the diagnosis. As Epithelioid angiosarcoma demonstrates Mesenchymal intermediate filament

expression, Vimentin is strongly positive in most of the cases.⁷ CD34 is considered as a sensitive marker in Epithelioid angiosarcoma which stains weakly positive in all the cases.⁸ Other endothelial markers like Factor VIII, CD31 or Fli-1 differentiates the lesion from other carcinomas. Solid infiltrative growth pattern, epithelioid morphology, vascular spaces lined by malignant endothelial cells with intracytoplasmic lumina, anastomosing vascular channels, increased mitotic activity, necrosis and haemorrhage on H&E sections aids in ruling out the differentials from epithelioid angiosarcoma of breast.

The standard treatment for Angiosarcoma breast is mastectomy with wide surgical resection⁹ Adjuvant chemotherapy and radiotherapy is given in metastatic cases. As Epithelioid angiosarcoma is a highly aggressive malignancy, it has a very poor prognosis and poor survival rate of 2 years in 50% of patients and 20% to 30% of disease free cases from the time of diagnosis.¹⁰

Conclusion

Epithelioid angiosarcoma of breast is a very rare variant and highly aggressive malignancy of endothelial origin.¹¹ Most commonly affected are the young women (20-50 years) and they possess a varied clinical presentations. Morphology in H&E sections and immunohistochemistry helps in differentiating this rare vascular lesion from other malignancies. The primary aim of the treatment is to achieve complete resection of the tumour with clear margins to prevent local recurrences and to increase the survival rate.^{12,13}

Conflicts of interest: None.

References

- Bennani A, Chbani L, Lamchahab M. Primary angiosarcoma of the breast: a case report. *Diagn Pathol* 2013;8:66.
- Muzumbder. Primary epithelioid angiosarcoma of breast masquerading as carcinoma. *Curr Oncol* 2008;17(1):64-9.
- Glazebrook, primary angiosarcoma of breast. *AJR Women's imaging* 2008;190(1):533-8.
- Arora. Angiosarcoma of the breast. *Gland Surg* 2014;3(1):28-34.
- Alessandra F, Nascimento. Primary angiosarcoma of breast. *Am J Surg Pathol* 2008;32(1):1896-1904.
- Saira Shah, Marilin Rosa. Radiation associated angiosarcoma of the breast. *Arch Pathol Lab Med* 2016;140(1):477-81.
- Ana Luísa Cunha Isabel Amendoeira. High-Grade Breast Epithelioid Angiosarcoma Secondary to Radiotherapy Metastasizing to the Contralateral Lymph Node: Unusual Presentation and Potential Pitfall. *Breast Care* 2011;6:227-9.
- Billings SD. Cutaneous angiosarcoma following breast conserving surgery and radiation: an analysis of 27 cases. *Am J Surg Pathol* 2004;28:781-8.
- Wang ZS, Zhan N, Xiong CL. Primary epithelioid angiosarcoma of the male breast: report of a case. *Surg Today* 2007;37:782-6.
- Rosen PP. Mammary angiosarcoma. The prognostic significance of tumor differentiation. *Cancer J* 1988;62: 2145-51.
- Mobini N. Cutaneous epithelioid angiosarcoma: a neoplasm with potential pitfalls in diagnosis. *J Cutan Pathol* 2009;36:362-9.

12. Ohta M, Tokuda Y, Kuge S: A case of angiosarcoma of the breast. *J Clin Oncol* 1997;27(2):91–94.
13. JessHart. Epithelioid angiosarcoma: A brief diagnostic review and differential diagnosis. *Arch path Lab med* 2011;135:268-72.

How to cite this article: Durga DS, Jayaganesh P, A rare vascular lesion of the breast. *J Diagn Pathol Oncol* 2019;4(2):148-150.