

Study of histopathological patterns of thyroid lesions in rural medical college

Piyush Prakash Narkhede^{1*}, Tooba Fatima², Kashinath S. Bhople³

¹Assistant Professor, ²Professor, ³Professor and HOD, ¹⁻³Dept. of Pathology, ¹⁻³JIIU'S IIMSR, Warudi Jalna, Maharashtra, India

*Corresponding Author: Piyush Prakash Narkhede

Email: narkhede.piyush664@gmail.com

Abstract

Aim and objectives: To study histopathological features of thyroid lesions, their age and sexwise distribution and frequency of thyroid lesions in thyroidectomy specimens in rural population along with their benign and malignant behaviour.

Materials and Methods: Present study is cross-sectional retrospective study conducted between January 2014 to December 2018 for period of five years, at the department of Pathology JIIU'S IIMSR WARUDI, Rural Medical College Badnapur, Jalna in Maharashtra. All the thyroidectomy specimens received for histopathological examination during year 2014 to 2018 in Department of Pathology, were included in present study

Result: Out of 233 cases studied, 204 were females [87.55%] and 29 were males [12.45%]. Mean age of presentation was 34.68 yrs. Range of the age of presentation was 2yr-70 yr. with maximum patients [60.52%] between 21-40 yrs. There were 191 non-neoplastic lesions [81.97] and 42 were neoplastic [18.03]. Most common non-neoplastic lesions were hyperplastic lesions 149 cases [63.95%]. Multinodular goitre was most common hyperplastic lesion. [47.21%]. Second most common non-neoplastic lesions were congenital lesions 18 cases [7.72%] with most common congenital lesion being Thyroglossal cyst [6.44%]. Inflammatory lesions were found to be [6.44%], all were Hashimoto thyroiditis. Out of 42 neoplastic cases, 29 were benign [12.45%] and 13 were malignant [5.58%]. Follicular adenoma was found to be most common benign neoplastic lesion [10.73%]. Papillary carcinoma was found to be most common malignant neoplastic lesion [3%].

Conclusion: Study shows that thyroid gland lesions were common amongst rural population in Jalna district with females out-numbering males. Non-neoplastic lesions were more common than neoplastic lesions. Benign lesions out-numbered malignant lesions. Multinodular goitre was found to be commonest non-neoplastic lesion. Follicular adenoma was found to be most common benign neoplasm, while papillary thyroid carcinoma was found to be commonest malignant neoplasm. Though other modalities like, FNAC and Sonography were useful in diagnosis of most of the cases, Histopathological examination was found to be mainstay for final diagnosis.

Keywords: Rural, Thyroid lesions, Histopathology, Goitre, Adenoma, Carcinoma.

Introduction

The normal adult thyroid gland composed of two symmetrical lobes joined by "H" shaped isthmus which lies against second, third, fourth tracheal rings, situated in lower part of neck extending from the level of fifth cervical to first thoracic vertebrae.¹ Histologically thyroid gland is covered by fibrous capsule underneath show thyroid follicles containing colloid lined by follicular cells that rests on basement membrane. Thyroid gland also contains C-cells [parafollicular cells] which intervene between follicular cells and basement membrane or lie in intervals between follicles. Spaces in between follicles contain stroma containing numerous capillaries and lymphatics.²

The primary hormone secreted by thyroid is Thyroxine (T₄), much lesser amounts of Triiodothyronine (T₃) and calcitonin [by parafollicular cells]. The primary function of the thyroid gland is to maintain the level of metabolism in the tissue that is optimal for their normal function. Thyroid hormones stimulate O₂ consumption by most of the cells in body, help to regulate lipid, carbohydrate metabolism, therefore necessary for normal growth and maturation as well as proper development of the central and peripheral nervous system. Thyroid gland also secrete calcium lowering calcitonin hormone by parafollicular cells.³

Diseases of thyroid include conditions associated with excessive hormone secretion [hyperthyroidism], thyroid hormone deficiency [hypothyroidism] and mass lesion.⁴ Diseases of the thyroid are manifested by alterations in

hormone secretion, enlargement of the thyroid gland (goitre) or both. Thyroid enlargements may be diffuse or nodular.⁵ Nodular lesion presents clinically as nodule and comprised of hyperplasias, benign and malignant tumours.⁶ Thyroid lesions can be classified pathologically⁷ as

1. Congenital abnormalities [Thyroglossal duct cyst, heterotopic thyroid tissue]
2. Thyroiditis [Acute, Granulomatous, Autoimmune, Riedel, multifocal sclerosing]
3. Hyperplasias [Dyshormonogenic goitre, Graves disease, Multinodular goitre].
4. Tumours
 - a. Benign:-[Follicular Adenoma, Hurthle cell adenoma]
 - b. Malignant:-[Papillary carcinoma, Follicular carcinoma, Hurthle cell carcinoma, medullary carcinoma, Poorly differentiated carcinoma, undifferentiated carcinoma, lymphomas, sarcomas metastatic lesions, etc].

There are different modalities used to evaluate and diagnose thyroid nodule, like history and clinical examination, thyroid function tests specially serum TSH, USG, FNAC, histopathological examination.⁸

FNAC is most appropriate investigation to define the nature of thyroid nodule and decide whether surgical intervention is needed or not.⁹ According to Practice

guidelines set by American Thyroid Association and National Comprehensive Cancer Network, FNAC Should be used as an initial diagnostic test because of its superior diagnostic reliability and cost-effectiveness, before both thyroid scintigraphy and ultrasonography.¹⁰ Though FNAC is simple, cost effective diagnostic test it has its own limitations like specimen adequacy, sampling techniques, skill of performing aspiration, interpretation of aspirate and overlapping cytological features between benign and malignant follicular neoplasm. Hence histopathological examination of thyroid tissue is needed and it is considered as final diagnostic test. Surgical excision and histopathological examination is crucial to rule out malignancy in nodules.¹¹

About 42 million people in India are suffering from Thyroid diseases. Thyroid nodules are very common in India, about 12.2% population have palpable thyroid nodule. The incidence of thyroid cancer is 8.7 per 100, 000 people per year. This tends to be increasing over the years. Whenever a patient presents with a thyroid swelling, main role of clinician is to distinguish between benign and malignant nodule.^{8,12}

Present study was performed on rural population to know the frequency of various thyroid lesions, their histopathological features and demographic features in this population.

Materials and Methods

Present study is cross-sectional retrospective study conducted between January 2014 to December 2018 for period of five years, at the department of pathology JIU'S IIMSR Rural Medical College, Badnapur, Jalna, Maharashtra.

Data for present study was obtained from departmental records of histopathology section for specified period of time. All the specimens of thyroid and related lesions submitted to department of pathology during specified time were included in present study.

Tissue Collection and Processing

For each case, laboratory request forms and duplicate copy of histopathological report were obtained and relevant clinical information like age, sex and histological type of thyroid diseases were noted.

Gross findings of the specimens were noted. Received specimens were fixed in 10% formalin. Sections from required areas were taken. Processing of the sections was done in Automatic tissue processor. After that processed tissue was embedded into paraffin wax blocks with help of L moulds. Blocks were trimmed using rotatory microtome. Sections of 3-5 micrometre were cut and taken onto slides. Routine Haematoxylin and Eosin staining was performed. Stained slides were examined under light microscope. Lesions were broadly classified into congenital, Hyperplastic lesions, inflammatory and neoplastic lesions. International guidelines set by WHO were used for further classification of neoplastic lesions.¹³

Subsequently data was analysed and represented using bar diagram, pie diagram and frequency tables.

Observations and Result

Total 233 specimens were received over period of 5 years in dept. of pathology.

Table 1: Sex-wise and lesion wise distribution of study subjects

Lesion	Male	Female	Total No.	Percentage
Hyperplastic lesions	12	137	149	63.95
Hashimoto thyroiditis	0	15	15	6.44
Thyroglossal cyst	7	8	15	6.44
Ectopic thyroid	2	1	3	1.28
Colloid cyst	2	7	9	3.86
Follicular adenoma	3	22	25	10.73
Hurthle cell adenoma	0	4	4	1.72
Papillary carcinoma	2	5	7	3.00
Follicular carcinoma	0	4	4	1.72
Medullary carcinoma	1	1	2	0.86
Total	29[12.45%]	204[87.55%]	233	100

Out of 233 patients, 204 were females [87.55%] and 29 were males [12.45%]. In each group, Female patients outnumbered male patients. Thyroglossal cyst and ectopic thyroid shows no sex predilection.

Table 2: Age-wise and Sex-wise distribution of study subjects

Range of age in years	Female	%	Male	%	Total
1-20	18	7.72	8	3.43	26[11.15%]
21-40	126	54.08	15	6.44	141[60.52%]
41-60	51	21.89	5	2.14	56 [24.03%]
61-70	9	3.86	1	0.43	10 [4.29%]
Total	204	87.55	29	12.45	233[100%]

Range of the age of presentation was 2-70 year, with maximum patients [60.52%] between 21-40 years.

Table 3: Mean age of presentation in different pathological lesions

Lesions	Mean age of presentation in years
Hyperplastic lesions	36.16
Hashimoto thyroiditis	36.2
Thyroglossal cyst	18.53
Ectopic thyroid	12.33
Colloid cyst	35.77
Follicular adenoma	35.4
Hurthle cell adenoma	32
Papillary carcinoma	34.42
Follicular carcinoma	34.25
Medullary carcinoma	43

Overall mean age of presentation was 34.68 years. Hyperplastic lesions presented with mean age of 36.16 years, Hashimoto thyroiditis presented with mean age of 36.2 years. Thyroglossal cyst presented with mean age of 18.53years, Follicular adenoma presented with mean age of 35.4 years. Papillary carcinoma presented with mean age of 34.42 yrs. medullary carcinoma presented with mean age of 43 years.

Table 4: Distribution of Study subjects according to Pathological Lesions

Lesions	Total No.	Percentage%
1. Non -neoplastic lesions	191	81.97
a. Hyperplastic lesions	149	63.95
b. Hashimoto thyroiditis	15	6.44
c. Congenital lesions	18	7.72
• Thyroglossal cyst	15	6.44
• Ectopic thyroid	3	1.28
d. Colloid cyst	9	3.86
2. Neoplastic lesions	42	18.03
a. Benign lesions	29	12.45
• Follicular adenoma	25	10.73
• Hurthle cell adenoma	4	1.72
b. Malignant lesions	13	5.58
• Papillary carcinoma	7	3.00
• Follicular carcinoma	4	1.72
• Medullary carcinoma	2	0.86
Total	233	100%

Out of 233 cases, 191[81.97%] cases were non-neoplastic lesions and 42[18.03%] were neoplastic lesions.

Most common lesion was Hyperplastic lesion with 149[63.95%] cases. Thyroglossal cyst was found in 15[6.44%] cases and was the most common congenital lesion.

Follicular adenoma with 25 cases [10.73%] was found to be most common neoplastic lesion and second most common lesion overall.

Papillary carcinoma with 7 cases [3 %] was found to be most common malignant lesion Medullary thyroid carcinoma was found in 2 cases [0.86%].

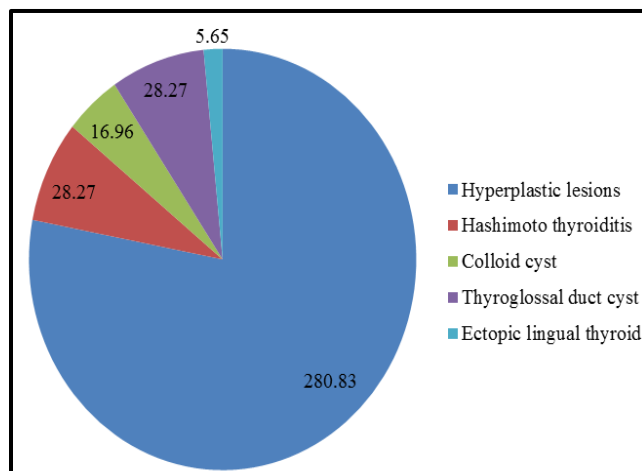


Fig. 1: Distribution of non-neoplastic lesions

Out of 191 non-neoplastic lesions, 149 cases were found to be Hyperplastic lesions [63.95%] which comprised mainly of Multinodular goitre 110 cases [47.21%] and diffuse colloid goitre 39 cases [16.74%]. 9 cases were colloid cyst [3.86%], 15 cases [6.44%] were inflammatory lesions, comprising of Hashimoto thyroiditis. 18 cases were Congenital lesions [7.72%], commonest was Thyroglossal duct cyst with 15 cases [6.44%], 3 cases of ectopic thyroid tissue lingual, submandibular and pre-laryngeal respectively [1.28%].

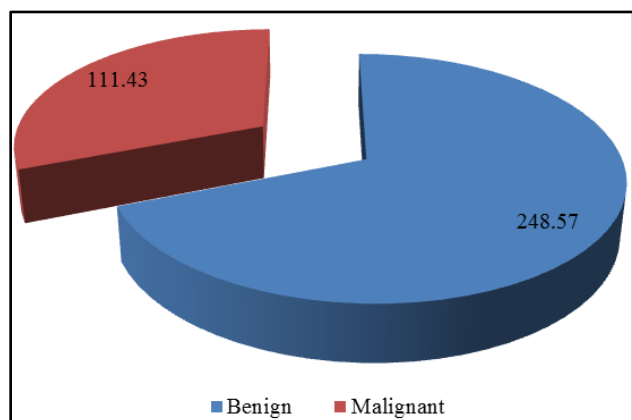


Fig. 2: Distribution of benign and malignant neoplastic lesions

Out of 42 neoplastic lesions, 29 cases [12.45%] were benign and 13 cases [5.58%] were malignant neoplastic lesions

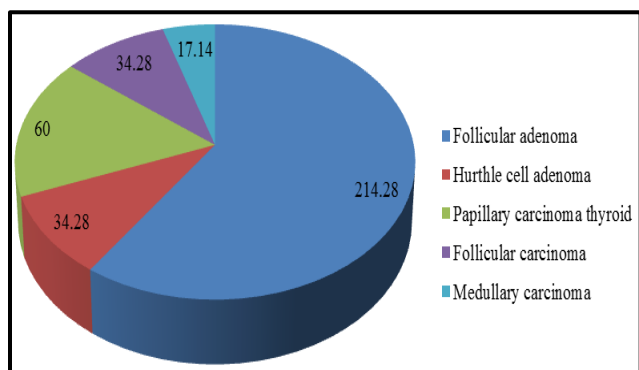


Fig. 3: Distribution of neoplastic lesions

Out of total 42 neoplastic lesion, 29 were benign cases comprised of 25 cases of follicular adenoma [10.73%] and 4 cases of hurthle cell adenoma [1.72%].

Out of total 42 neoplastic lesion, 13 cases were malignant lesions which comprised of 7 cases of papillary carcinoma [3%], 4 cases of follicular carcinoma [1.72%] and 2 cases of medullary carcinoma [0.86%]

Table 5: Cyto-histopathological correlation

Cytology diagnosis	No. of cases	Histopathology diagnosis
Autoimmune thyroiditis	2	Hashimoto thyroiditis with follicular adenoma
Autoimmune	1	Papillary carcinoma in background

thyroiditis		of Hashimoto
Colloid Goitre	2	Papillary carcinoma in background of multinodular goitre
Colloid goitre	1	Follicular variant of papillary carcinoma
Colloid Goitre	1	Papillary carcinoma
Hyperplastic nodule	2	Medullary carcinoma
Suspicious for FN	2	Multinodular goitre

Above table shows that 11 lesions which were not correlated on histopathology with cytology

Discussion

Diseases of the thyroid gland are among the most abundant disorders worldwide. About 300 million people in the world are suffering from thyroid disorders and about 42 million people India reside in India.¹⁴ Present study was carried out in Dept. of Pathology, JIU's IIMSR Rural Medical College Warudi, Badnapur, Jalna from Jan. 2014 to Dec.2018, for period of five years. Total 233 specimens of thyroidectomy were received in Dept. of Pathology in 5 years.

Table 6: Comparison of distribution of cases according to sex

Various studies	Female	Male
Modi et al ¹⁸	83 %	17 %
Magdalene et al ¹⁶	89.2 %	10.8 %
Solomon et al ¹⁹	86.4%	13.6%
Present study	87.55%	12.45%

In present study there were 204 females [87.55%] and 29 were males [12.45%], with female preponderance. Present study is consistent with Solomon et al and Magdalene et al studies.

Table 7: Comparison of distribution of cases according to age

Various studies	Mean age years	Range in years
Magdalene et al ¹⁶	37.4	-----
Modi et al ¹⁸	37.4	21-40
Solomon et al ¹⁹	36.3	30-39
Present study	34.68	21-40

Overall mean age of presentation was 34.68 years, most common age group of presentation was 21-40 years. Present study is consistent with Solomon et al study.

Table 8: Comparison of distribution of Neoplastic and non-neoplastic lesions

Various studies	Non-neoplastic	Neoplastic
Dash M et al ¹⁵	73.3%	26.3%
Magdalene et al ¹⁶	66.7%	33.3%
Padmavathi et al ¹⁷	70.10%	29.90%
Present study	81.97%	18.03%

Like all above mentioned studies, Non-neoplastic lesions outnumbered neoplastic lesions with 191 cases were non-neoplastic [81.97%] and 42 lesions were neoplastic [18.03%].

Table 9: Comparison of distribution of Hyperplastic lesions

Various studies	% of Hyperplastic lesions
Modi et al ¹⁸	46
Solomon et al ¹⁹	57.2
Dwarish et al ²⁰	53.5
Present study	63.95

Most common lesion in present study was hyperplastic lesion 63.95% comprised of multinodular goitre [47.21%], diffuse colloid goitre [16.74%].137 were females and 12 males. Most common age group of presentation was 21-40 years. Present study is consistent with Solomon et al.

Table 10: Comparison of distribution of Inflammatory lesions

Various studies	% of inflammatory lesions
Magdalene et al ¹⁶	11.7
Modi et al ¹⁸	8
Dwarish et al ²⁰	7
Present study	6.44

Inflammatory lesions were consisted of Hashimoto thyroiditis, with mean age of presentation of 36.2 years. All were females. Less no. of cases 6.44% as compared to other studies is explained by effective screening by FNAC and conservative management of these cases, lower age of presentation as compared to other studies is explained by demographic variation. Present study is consistent with Dwarish et al study.

Table 11: Comparison of distribution of congenital lesions

Various studies	% congenital lesions	
	Thyroglossal cyst	Ectopic thyroid
Magdalene et al ¹⁶	4.2	-----
Solomon et al ¹⁹	6.9	-----
Present study	6.44	1.28

Congenital lesions in present study were consisted of thyroglossal cysts 15 cases and ectopic thyroid 3 cases lingual, submandibular and pre-laryngeal respectively. The most common congenital lesion was found to be thyroglossal cyst 15 cases [6.44%] with mean age of presentation 18.53 years, followed by 3 cases [1.28%] of ectopic thyroid lingual, submandibular and pre-laryngeal respectively with mean age of presentation 12.33 yrs. No specific female and male predilection was noted in present study for thyroglossal cyst with 8 females and 7 males and also for ectopic thyroid with 2 males and 1 female. Present study is consistent with Solomon et al study.

Table 12: Comparison of Distribution of Benign Neoplastic lesions

Various studies	% out of total lesions
Modi et al ¹⁸	27
Solomon et al ¹⁹	17.4
Dwarish et al ²⁰	15.5
Present study	12.45

Total 29 cases of benign neoplastic lesions [12.45%] were there in present study. Out of which, 25 cases were follicular adenoma with mean age of presentation was 35.4 years. 22 cases were females, 3 cases were males. 4 cases of Hurthle cell adenoma with mean age of presentation was 32 years. All cases were female. Present study is consistent with Dwarish et al and Solomon et al studies.

Table 13: Comparison of distribution of Malignant Neoplastic lesions

Various studies	% out of total lesions
Modi et al ¹⁸	16
Solomon et al ¹⁹	12.6
Dwarish et al ²⁰	24
Present study	5.58

Most common malignant lesion was papillary carcinoma 7 cases, 53.04% of total malignant neoplastic lesion. Out of 7 cases of papillary carcinoma, one was follicular variant of papillary carcinoma [infiltrative], two were Papillary microcarcinoma, One case presented with papillary carcinoma in the background of Hashimoto thyroiditis. Remaining three cases were papillary carcinoma classic variant. Mean age of presentation was 34.42 yrs. There were 2 males and 5 females. According to in the 4th edition WHO classification, papillary micro-carcinoma is defined as papillary carcinoma measuring 1 cm or less in diameter. Papillary carcinoma composed almost completely of follicles, with classic papillary nuclear features were classified as Follicular variant of papillary carcinoma thyroid which was sub-classified into encapsulated and non-encapsulated (infiltrative) variants. The encapsulated follicular variant PTC was further divided into invasive and non-invasive. The non-invasive encapsulated follicular variant of PTC was downgraded from carcinoma to non-invasive follicular thyroid neoplasm with papillary-like nuclear features, and cases with incomplete invasion were downgraded from carcinoma to well differentiated tumour of uncertain malignant potential.¹³

4 cases were follicular carcinoma with mean age of presentation 34.25 years. One case was widely invasive Follicular carcinoma [infiltrating adjacent thyroid tissue], other three cases were minimally invasive follicular carcinoma [capsular invasion only]¹³

2 cases were medullary carcinoma, one male and one female, with mean age of presentation was 43 years.

Total malignant cases were less as compared to other studies [5.58% of total lesions], however Papillary

carcinoma was most common malignant lesion like other studies.

Cyto-Histopathological Correlation

From table 5, 11 lesions were not correlated on histology with cytology. Inability to hit the target lesion during FNAC was seen in first 5 cases, as many times neoplasm presents with other non-neoplastic lesions like multinodular goitre and Hashimoto thyroiditis. Interpretation problems of FNAC was seen in next 4 cases. Last two cases showed

overlapping features in the case of adenomatous hyperplasia with follicular neoplasm on cytology. This indicates that though FNAC is reliable, initial diagnostic modality, has its own limitations and surgical excision and histopathological examination for final diagnosis is mandatory. Present study also correlates with other studies like Kumar et al,⁹ Bagga et al,¹⁰ Nandedkar et al²¹ showing FNAC has both false positive and false negative rates.

Histopathological characteristics of some important Thyroid Lesions

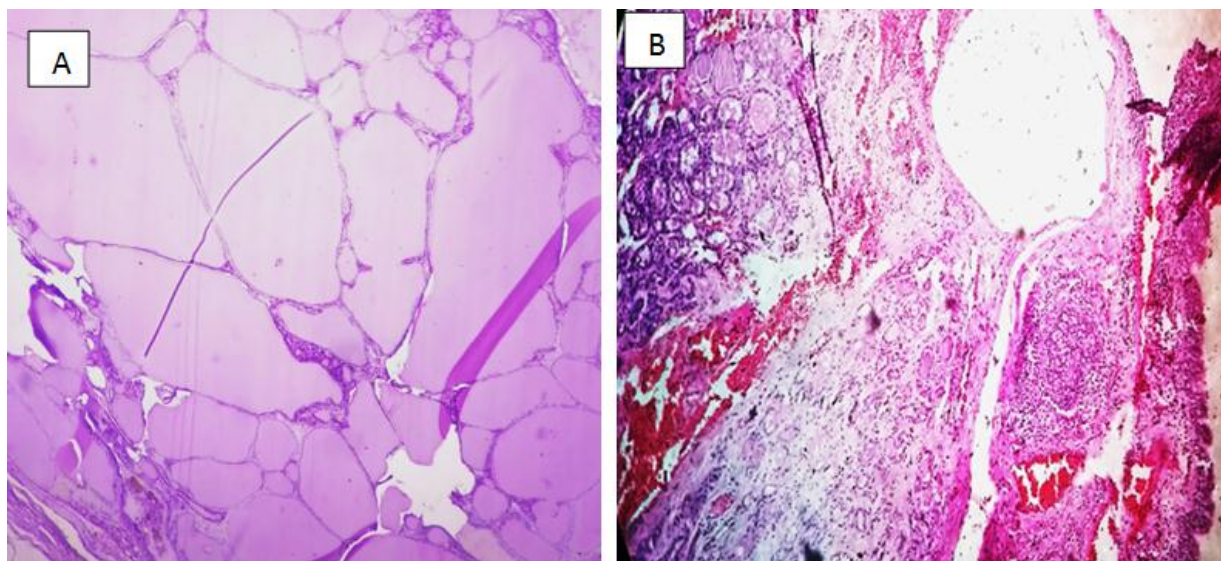


Fig. 4: A. Diffuse Colloid Goitre, B. Thyroglossal cyst with Respiratory lining and underneath thyroid tissue

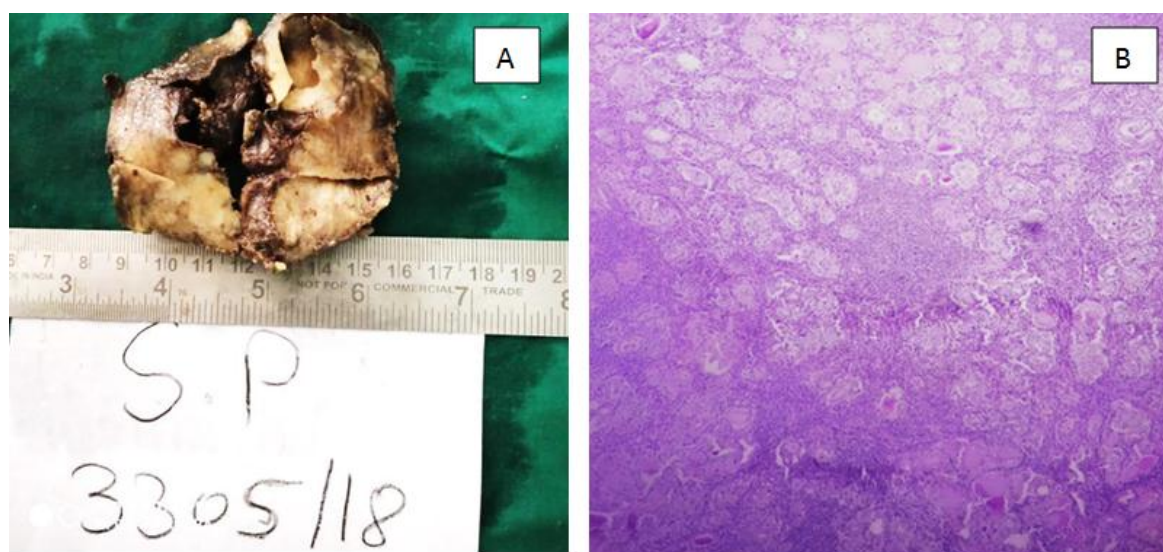


Fig. 5: A. Gross Hashimoto Thyroiditis, B. Microscopy Hashimoto Thyroiditis

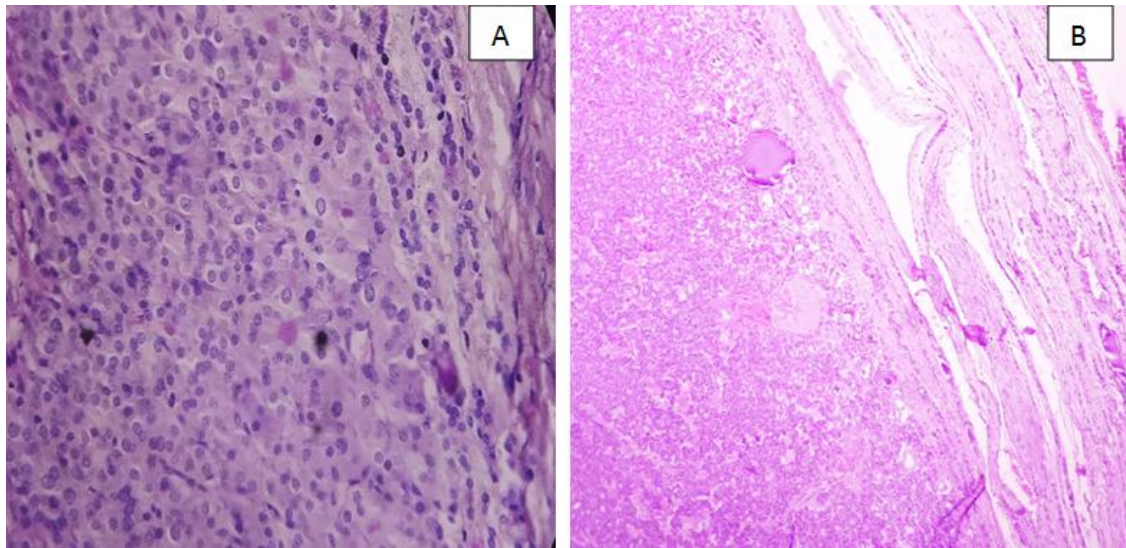


Fig. 6: A. Hurthle cell Adenoma, B. Follicular Adenoma with intact capsule

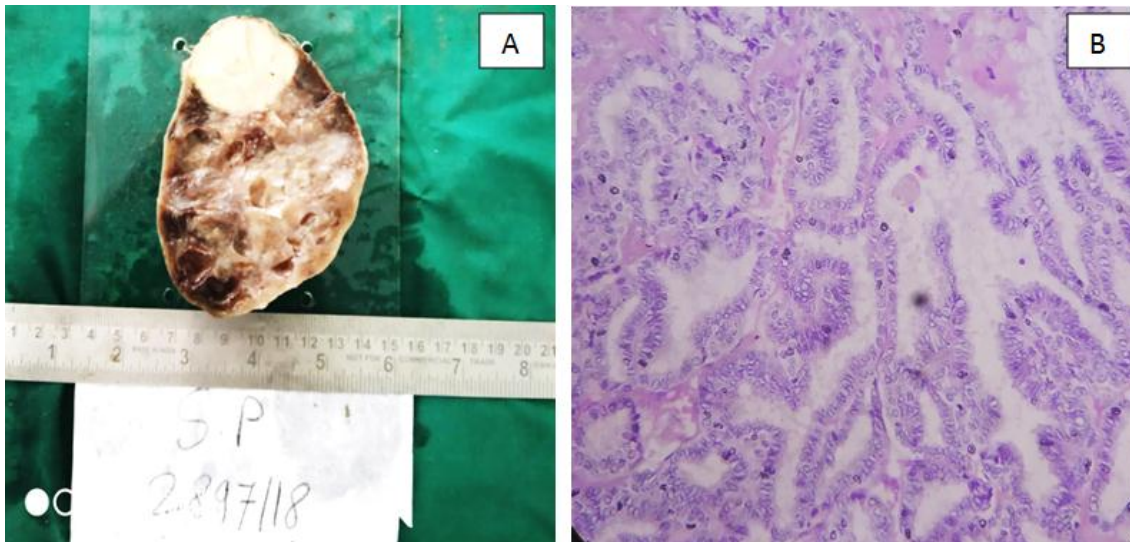


Fig. 7: A. Gross Papillary Carcinoma with colloid goitre, B. Microscopy Papillary Carcinoma with orphan Annie nuclei

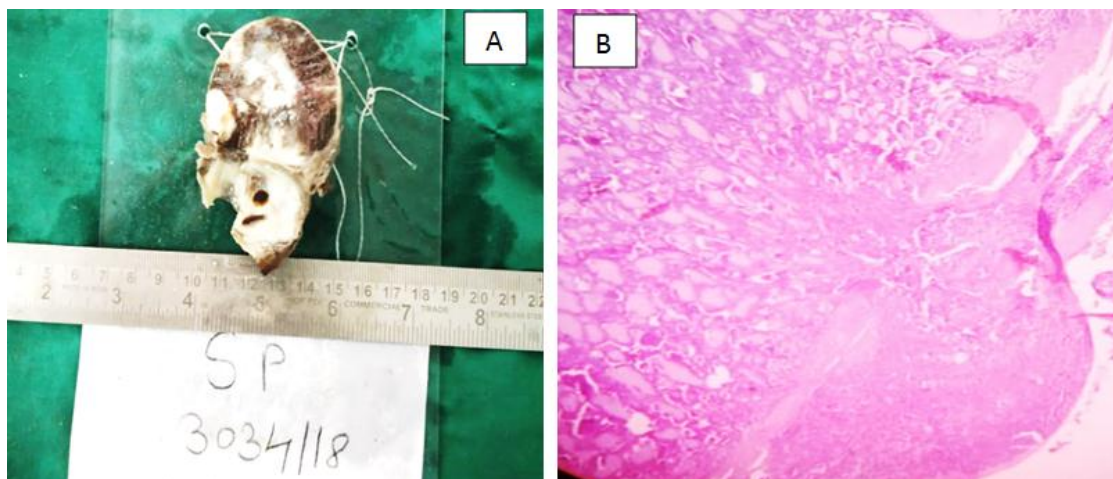


Fig. 8: A. Gross Follicular Carcinoma with infiltration in adjacent thyroid, B. Microscopy Follicular Carcinoma with capsular invasion tissue

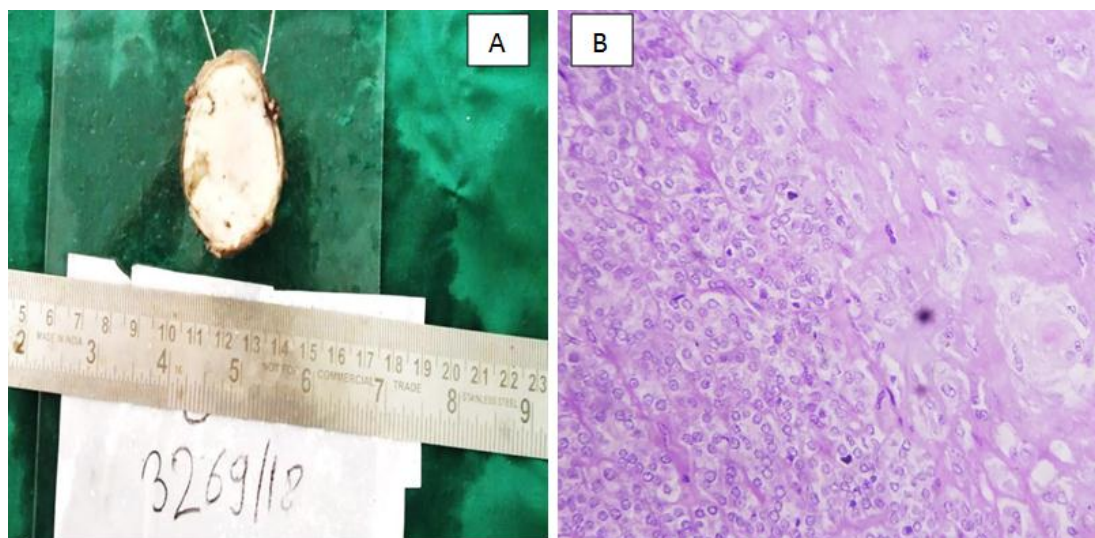


Fig. 9: A. Gross Medullary Carcinoma, **B.** Microscopy Medullary carcinoma

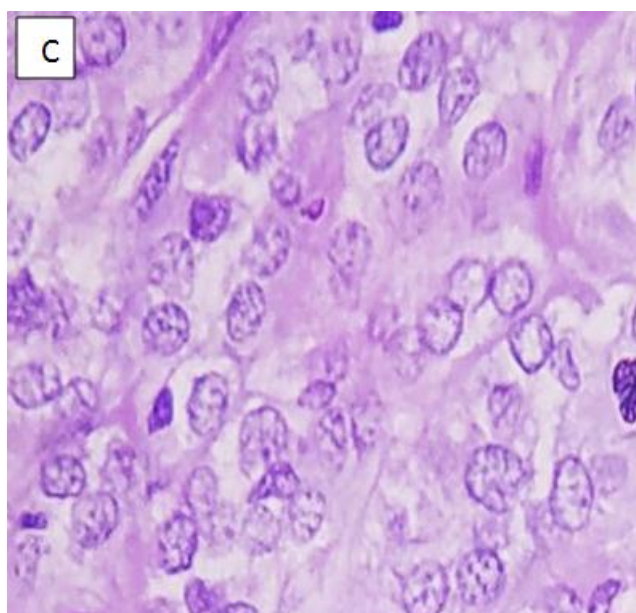


Fig. 9: C. Medullary carcinoma- round to polygonal cells with salt- paper chromatin.

Conclusion

1. In rural population, Thyroid lesions were more common in females than in males
2. Most common age group of presentation was 21-40 yrs.
3. Non-neoplastic lesions were more common than neoplastic lesions.
4. Most common lesions were hyperplastic lesions. Multinodular goitre was found to be commonest non-neoplastic lesion and most common lesion overall
5. Thyroglossal cyst was most common congenital lesion.
6. Benign neoplastic lesions outnumbered malignant lesions.
7. Most common benign neoplastic lesion and second most common lesion was follicular adenoma
8. Most common malignant lesion was found to be papillary carcinoma thyroid.
9. Though other modalities like, FNAC, Sonography were useful in diagnosis of most of the cases, Histopathological examination was found to be mainstay for final diagnosis.

Recommendations

1. Considering daily load of Thyroid cases to Department of Pathology in our Institute, we recommend a broad epidemiological study in this region of Aurangabad-Jalna belt.
2. Iodinization of salt should be sustained in this region as the Goitre is still the most common thyroid lesion.
3. Many times neoplasm presents with other non-neoplastic lesions like multinodular goitre and Hashimoto thyroiditis, therefore we recommend thorough clinical evaluation of any enlarged thyroid. Thyroid lesions should not be ignored just as

multinodular goitre; effort should be made to rule out possibility of hidden neoplasm particularly malignant neoplasm.

- As information conveyed by Pathologist is important to clinician for proper management and prognostication of case, thorough gross and microscopic evaluation of thyroidectomy specimens is mandatory, particularly Thyroid neoplasm should be categorized according to International guidelines set by WHO.

Conflict of Interest: None.

Source of support: None.

References

- Gaikwad S, Joshi R. An Anatomical Study of Morphological Variations of The Thyroid Gland. *Indian J Anatomical Res* 2016;4:665-69
- Singh I B. The Endocrine System. In: *The Textbook of Histology* 4th ed. Rohtak: Jaypee brothers; 2002.p306-07
- Ganong WF. The Thyroid gland. In: Review of Medical Physiology. 23rd ed. San Francisco: McGraw-Hill Co.; 2010:301-13
- Mitra A. The Endocrine System, In: Vinay Kumar, Abbas AK, Aster JC, Robbins and Cotran, Pathologic Basis of Disease, 9th South Asia Ed. Elsevier India 2015;1082-99.
- Tsegaye B, Erget EW. Histopathologic Pattern of Thyroid Disease *East Afr Med J* 2003;80:525-28
- Unnikrishnan AG, Kalra S, Baurah M, Nair G, Nair V, Bantwal G, Sahay RK, Endocrine Society of India management guidelines for patients with thyroid nodules: A position statement. *Indian J Endocrinol Metab* 2011;15(1):2-8.
- Rosai J, Thyroid gland, In: Rosai and Ackerman's Surgical Pathology. 10th ed. Elsevier India 2012;488-64
- Popoveniuc G, Jonklaas J, Thyroid nodules. *Med Clin North Am* 2012;96(2):329-49.
- Kumar A, Sreejayan MP, Remin v, Accuracy of FNAC in Diagnosing Thyroid Nodules: A single Institutional Experience. *Biomed J Sci and Tech Res* 2017(4):1-5.
- Bagga PK, Mahajan NC, Fine needle aspiration cytology of thyroid swellings: How useful and accurate is it? *Indian J Cancer* 2010,47(4):437-42.
- Kumar A, Bhadouriya SK, Narain P, Chauhan JP, Bharti B, Singh J et al. Comparative study of FNAC and Histopathology of thyroid swellings. Diagnostic accuracy and role in its management. *Int J Otorhinolaryngol Head Neck Surg* 2017;3(4):885-92.
- Unnikrishnan AG, Menon UV. Thyroid disorders in India: an epidemiological perspective. *Indian J Endocrinol Metab* 2011;15(6):78- 81.
- Lloyd RV, Osamura RY, Klöppel G, Rosai J World Health Organisation Classification of Tumours of Endocrine organs 4th edition volume 10 IARC press 2017:75-100
- Deokar PG, Nagdeote AN, Lanje MJ, Basutkar DG, Prevalence of Thyroid diseases in Tertiary Care Centre. *Int J Cur Res Rev* 2016;8(9):26-30.
- Dash M, Chandrashekar KPA, Raghu K, Kethireddy S, Histopathological study of neoplastic and non-neoplastic thyroid lesions: An institutional experience of 2 years. *J Eval Med Dental sci* 2016;5(73):5348-51.
- Magdalene KF, Swetha J, Narayanan N, Sumangala B, Histopathological study of thyroid lesions in a tertiary care centre in coastal belt of South India. *Trop J Path Micro* 2017;3(1):77-83.
- Padmavathi M, Jyothi AR, Histopathological spectrum of non-neoplastic and neoplastic lesions of thyroid. *J Med Sci* 2017;3(3):63-68.
- Modi M, Daveshwar M, Histopathological pattern of thyroid Lesions. *International Journal of Biomedical and Advance Research* 2018;9(1):27-36.
- Solomon R, Iliyasu Y, Mohammed AZ, Histopathological pattern of thyroid Lesions in Kano, Nigeria: A 10-year retrospective review. *Niger J Basic Clin Sci* 2015;12(1):55-60.
- Darwish AH, Al Sindi KA, El Kafsi J, Acantab B, Pattern of Thyroid Diseases - A Histopathological Study. *Bahrain Med Bull* 2006;28(4):1-6.
- Nandedkar SS, Dixit M, Malukani K, Varma AV, Shankhini G, Evaluation of thyroid lesions by fine-needle aspiration cytology according to Bethesda system and its histopathological correlation. *Int J Appl Basic Med Res* 2018;8(2):76-82.

How to cite this article: Narkhede PP, Fatima T, Bhople KS, Study of histopathological patterns of thyroid lesions in rural medical college. *J Diagn Pathol Oncol* 2019;4(2):92-100.