

Clear cell sarcoma in an elderly female - A rare case report with literature review

Monal Trisal¹, Sabina Khan^{2*}, Mohd. Jaseem Hassan³, Sujata Jetley⁴, Musharraf Husain⁵

¹Demonstrator, ²Associate Professor, ³Associate Professor, ⁴HOD, Dept. of Pathology, ⁵Professor & HOD, Dept. of Surgery, Hamdard Institute of Medical Sciences & Research, New Delhi

*Corresponding Author:
Email: drsabina1@gmail.com

Abstract

The Clear Cell Sarcoma of Tendons and Aponeurosis is an extremely rare melanin producing soft tissue tumor. It accounts for nearly 1% of all soft tissue tumors. Clear cell sarcoma affects commonly young adults between age group of 20-40 years and most common sites are foot and ankle. It has histological, immunohistochemical, and ultrastructural similarities with the more common primary (or metastatic) malignant melanoma causing major diagnostic confusion. We present a case of a 55-year lady with clear cell sarcoma of right foot which is extremely rare for this age group.

Keywords: Clear cell Sarcoma, Malignant Melanoma of soft parts, Soft tissue tumor

Introduction

Clear cell sarcoma of tendons and aponeurosis (CCSTA) is an extremely rare melanin producing soft tissue tumor accounting for approximately 1% of all soft tissue tumors.⁽¹⁾ It is also known as Malignant Melanoma of Soft Tissues. Despite having histological similarities to malignant melanoma, it is clinically and genetically distinct from it.⁽²⁾ CCSTA is a deep-seated tumor, involving tendons and aponeuroses. It has a predilection for lower extremities, particularly the foot and ankle region, accounting approximately 40% of cases.⁽³⁾ Approximately 70% of the cases possess a balanced translocation t(12;22), (q13;q12) involving ATF1 gene on chromosome 12 and EWS gene on chromosome 22, which is not found in malignant melanoma.⁽⁴⁾ We report a case of an elderly lady which holds importance for its rarity in this age group.

Case Report

A 55-year-old female presented with non-tender, firm soft tissue swelling measuring 2x2cm on dorsum of right foot since childhood. There was no history of trauma. However, there was history of excision of a similar swelling in same foot 2 years back of which no medical record was available.

X-ray: Patient underwent X-ray which was completely normal. A clinical diagnosis of calcified ganglion was made.

On gross examination, globular piece of soft tissue measuring 1.4x1.4x1cm was received. On cut section, firm greyish white areas with tiny brownish foci were identified.

On microscopy, sections revealed a circumscribed lesion comprising of many regular nests and fascicles of polygonal to spindle shaped cells having vesicular nuclei with prominent nucleoli and abundant clear cytoplasm. (Fig. 1a, 1b, 1c) The nests showed fibrous septa at places with abundant intracellular as well as extracellular melanocytic pigment. (Fig. 1d).

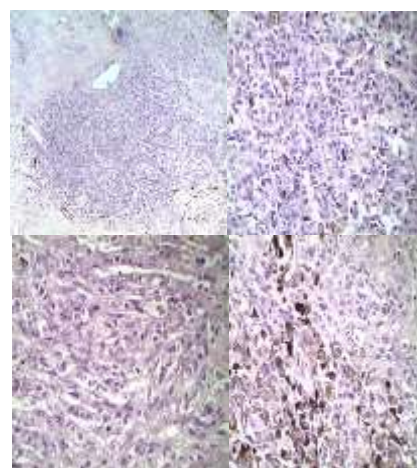


Fig. 1: Photomicrograph showing a tumor composed of nests and fascicles of polygonal to spindle cells (a, b, c) with abundant intracellular as well as extracellular melanocytic pigment (d) ((H&E, 4x, 10x, 40x, 40x respectively))

Histomorphological features were suggestive of Clear Cell Sarcoma of Tendons and aponeurosis.

On Immunohistochemistry, cells were positive for HMB-45 and S-100, thus clinching the diagnosis. (Fig. 2, 3).

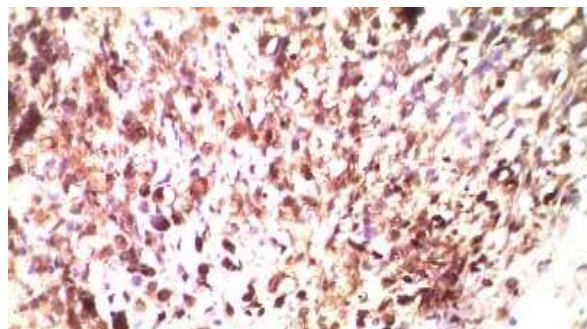


Fig. 2: IHC for HMB-45 showing cytoplasmic positivity in the tumor cells

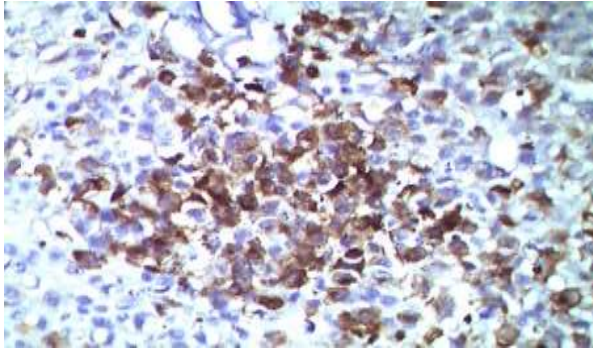


Fig. 3: IHC for S-100 showing nuclear and cytoplasmic positivity in the tumor cells

Discussion

Clear Cell Sarcoma of Tendons and Aponeurosis is very rare, accounting for 1% of all soft tissue sarcomas.⁽¹⁾ It commonly involves lower extremities, especially tendons and aponeurosis of the foot and ankle followed by thigh and toes.⁽³⁾ The exact histogenesis is unclear, but the presence of intracellular melanin in about two-thirds of cases supports an origin from migrated neural crest cells that have the capacity to produce melanin. It predominantly affects young adults between 20-40 years of age with slightly female preponderance.⁽¹⁾ However in our case, patient is an elderly which is very rare. Clinically, it presents as a painless slow growing mass that has been present for several months or years. In our case, patient presented with painless slow growing lesion which surprisingly was present since childhood.

In a study by Hocar et al, 82.69% of the cases were located in the extremities, most common site being foot. In their study as well, 57.69% of patients had lesions that measured less or equal to 4 cm. The mean age was 33 and 26 years (range 6–81 years). Although some reports have found predominance in females, CCS was slightly more common in male than female patients in their series.⁽⁴⁾

In a study by Kawai et al on 75 patients comprised 41 men (55%) and 34 women (45%), and patients ranged in age from 10 years to 71 years. Sixty percent of patients were <40 years, and 91% were aged <60 years. Sixty-five tumors (87%) were located in the extremities, and 10 tumors (13%) were located in the trunk. The most common tumor site was the foot, followed by the hand and the thigh.⁽⁵⁾

In a study by Sara et al seventeen cases of malignant melanoma of soft parts (clear cell sarcoma) were reported. The patients age ranged from 9 to 70 where 13 were between 10 and 40 years of age. There were eight male patients and nine female patients. The most common tumor location was the foot, followed by knee.⁽⁶⁾

Grossly, external surface of the tumor is lobulated or multinodular grey white mass varying in size from 2-6 cm. The cut surface shows focal haemorrhage or necrosis and in small proportion of cases melanin

pigment may be present, so prominent as to reveal a brownish or blackish foci.

Microscopically, tumor is composed of nests and fascicles of uniform to mild pleomorphic round to spindle cells with clear cytoplasm, vesicular nuclei and prominent nucleoli. Tumor cells may have melanin pigment in 50% of the cases. Areas of necrosis and haemorrhage may also be present. On immunohistochemistry, the tumor cells are positive for S100, HMB 45, Melan A, MITF, NSE, Cd57 and negative for desmin and cytokeratin.⁽⁷⁾

A reciprocal translocation t (12;22) (q13;q12) resulting in a EWSR1/ATF1 chimeric transcript, is identified in 70-90% cases, the cytogenetic hallmark of CCS. However, due to financial constraints in our case, genetic studies were not done.

Malignant Melanoma, primary or metastatic, with its histological, immunohistochemical and ultrastructural similarity constitutes the most important diagnostic mimic of CCS.

The other Differential Diagnosis of Clear Cell Sarcoma should include Malignant peripheral nerve sheath tumor, Melanotic Schwannoma, Perivascular epithelioid cell neoplasms (PECOMA), Synovial Sarcoma (monophasic type), Alveolar soft part Sarcoma, Epithelioid Sarcomas and Carcinomas.⁽⁸⁾ A careful histological evaluation coupled with immunohistochemical demonstration of melanocytic differentiation in CCS clinches the diagnosis.

Clear cell sarcoma clinically and radiologically appears as benign lesion but has tendency to recur and metastasis occurs to regional lymph nodes. Overall prognosis is poor. Complete resection of the tumor with sentinel lymph node biopsy is the mainstay of treatment with chemotherapy and radiotherapy showing no proven beneficial effect.⁽⁹⁾

Conclusion

It is critical, yet challenging to recognise clear cell sarcoma of soft tissue due to its rarity, benign presentation and histopathological resemblance to malignant melanoma. Its early diagnosis is of utmost importance so as to optimize the potential benefit which will lead to better patient prognosis.

References

1. Haren V. Oza, Jignasa N. Bhalodia et al. Clear cell sarcoma of gluteal region; malignant melanoma of soft parts. National journal of medical research. 2013;3(2):193-195.
2. Ferrari Andria, Casanova michela et all. Clear cell sarcoma of tendons and aponeuroses in paediatric patients. American cancer society.2002;94(12):3269-76.
3. Sharon W. Weiss, John R Goldblum. Enzinger and Weiss's soft tissue tumors, 5th edition. St Louis, Missouri.
4. O Hocar, A Cesne, S Berissi, P Terrier et al. Clear Cell Sarcoma (Malignant Melanoma) of Soft Parts: A Clinicopathologic Study of 52 Cases. Dermatology Research and Practice. 2012;12.

5. Akira Kawai, Ako Hosono, Robert Nakayama et al. Clear Cell Sarcoma of tendons and aponeurosis. A study of 75 patients. *Cancer Journal*. 2017;109(1):109-116.
6. Alan S. Sara, Harry L. Evans, Robert S. Benjamin. *Cancer Journal*. 1990;65(2):367-374.
7. Dr. Syed M Rahman, Dr. KPA Chandrashekar. Clear cell sarcoma of tendon and aponeurosis- A rare case. *Indian journal of applied research*.2015;5(1):459-460.
8. Dim DC, Cooley LD, Miranda RN. Clear cell sarcoma of tendons and aponeuroses: A review. *Arch Pathol Lab Med*. 2007;131:152–6.
9. Deenik W, Mooi WJ, Rutgers EJ, Peterse JL, Hart AA, Kroon BB. Clear cell sarcoma (malignant melanoma) of soft parts: A clinicopathological study of 30 cases. *Cancer*. 1999;86:969–75.