

Content available at: <https://www.ipinnovative.com/open-access-journals>

IP Journal of Diagnostic Pathology and Oncology

Journal homepage: <https://www.jdpo.org/>

Case Report

Hepatic lymphangioma in a neonate: A rare case report

Anna Sabu^{1*}, Manasa G.C¹

¹Dept. of Pathology, J.J.M Medical College, Davangere, Karnataka, India



ARTICLE INFO

Article history:

Received 12-07-2024

Accepted 29-07-2024

Available online 01-08-2024

Keywords:

Hepatic lymphangioma
Congenital malformation
Lymphatic system
Pediatric liver mass
Differential diagnosis

ABSTRACT

Lymphangiomas are benign neoplasms regarded as congenital malformations of the lymphatic system, composed of dilated endothelial lined spaces of varying sizes containing lymph. Most lymphangiomas (95%) are located in the neck or the axilla. Intra -abdominal cases account for less than 5% of all lymphangiomas, mainly mesenteric or retroperitoneal. Here we have a rare case of hepatic lymphangioma, which presented as an intra-abdominal mass and diagnosed to be congenital hepatic cyst or off-centered mesenteric cyst in NCCT and USG respectively, which was then confirmed to be arising from the liver intraoperatively. Microscopy showed multiple cystic spaces lined by flattened epithelium, for which the differential diagnosis of simple mesothelial cyst and lymphangioma was offered, which was then confirmed by IHC which showed D2-40 positivity and Calretinin negativity. Hepatic lymphangioma which was difficult to be diagnosed definitively prior to surgery. Here, morphological study and IHC turned out to be useful in arriving at definitive diagnosis.

This is an Open Access (OA) journal, and articles are distributed under the terms of the [Creative Commons Attribution-NonCommercial-ShareAlike 4.0 License](https://creativecommons.org/licenses/by-nc-sa/4.0/), which allows others to remix, tweak, and build upon the work non-commercially, as long as appropriate credit is given and the new creations are licensed under the identical terms.

For reprints contact: reprint@ipinnovative.com

1. Introduction

Lymphangiomas are benign neoplasms considered as congenital mal - formations of the lymphatic system, composed of varying sized dilated endothelial - lined spaces containing lymph. Most lymphan - giomas (95%) are located in the neck or the axilla, as the loose connective tissue allows for easy expansion of lymphatic channels. Intra - abdominal cases account for less than 5% of all lymphangiomas, mainly mesenteric or retroperitoneal.¹

Hepatic lymphangiomas are very uncommon, and after it's first description by Ziegler in 1892, only a few cases have been documented. Most lymphangiomas are present at birth and become symptomatic before the second year of life. Since they are the result of congenital malformation of the lymphatic system, hepatic lymphangiomas, characterized by cystic dilatation of the

lymphatic vessels in the parenchyma are seen in children and adolescents more commonly than in adults.

Primary liver masses constitute the third most common group of abdominal tumours in childhood with an incidence of 0.4 – 1.9 per million children each year. Liver masses in children are classified as malignant, benign or indeterminate. Improved imagistic methods facilitate the identification of benign and malignant liver masses. Differentiation is still complex and resection with biopsy and histological diagnosis is necessary. Although the majority of benign masses may be of little consequence, morbidity and mortality can occur. Effect from a tumour mass can cause pain, biliary obstruction and inferior venacava obstruction, limit lung capacity or cause feeding difficulties. A hepatic lymphangioma can be solitary or associated with multiple liver lesions or similar lesions of other viscera. A solitary hepatic lymphangioma is very uncommon. They have been classified in three types: simple lymphangioma, cavernous lymphangioma

* Corresponding author.

E-mail address: annaemil007@gmail.com (A. Sabu).

and cystic lymphangioma. Depending on the location of lymphangioma, the fluid component of a lymphangioma can be serous or chylaceous.^{1,2} In the presence of hemorrhage or infection, a lymphangioma can become bloody or purulent. Most hepatic lymphangiomas are found by routine physical examination or from other complaints and have no specific clinical presentation. Abdominal pain is caused by compression against the surrounding tissues or organs. An abdominal MRI or CT can be used to help differentiate from similar lesions such as mesenteric cyst or hepatic hemangioma.

Lymphangiomas are benign hamartomas but still have a risk of malignant transformation. Another type of complications refers to rupture or compression due to continuous enlargement. Surgical resection of lymphangiomas has been considered standard treatment. For huge or multiple haemangiomas, liver transplantation should be considered.

2. Case Report

3month old female, presented with excessive crying and irritability since 20 days. On per -abdominal examination, mild hepatomegaly noted and an intra-abdominal mass was palpated. USG and NCCT abdomen showed differentials as congenital hepatic cyst and off centred mesenteric cyst respectively. The cyst was surgically resected and sent to histopathology. Gross examination of the specimen revealed a multiloculated cyst measuring 7X4X6 cms, which hemorrhagic serous fluid. Microscopic examination showed multiple cystic spaces lined by flattened epithelium, for which the differential diagnosis of simple mesothelial cyst and lymphangioma was offered, which was then confirmed by IHC which showed D2-40 positivity and Calretinin negativity, thus rendering a diagnosis of lymphangioma.

3. Discussion

Hepatic lymphangiomas have multiple etiopathogenetic theories. The hypothesis that is most widely accepted is the one of a congenital anomaly. It is known that the connection between the venous and the lymphatic system starts during embryogenesis. Whilst the anomaly has an important growth potential, it has never been proven to be malignant or to show any malignant metamorphosis. The term “lymphangioma” has mistakenly been used to designate a lesion that is considered to be a “mesenchymal hamartoma”. This rare benign liver tumour usually occurs in infants and young children who present with a rapidly increasing hepatomegaly due to the accumulation of fluids within the cystic lesion.³

Usually, the mesenchymal hamartoma is located near the lower margin of the liver. Histologically, the lesion is composed mainly of oedematous connective tissue with cyst like spaces with pale eosinophilic secretions in them

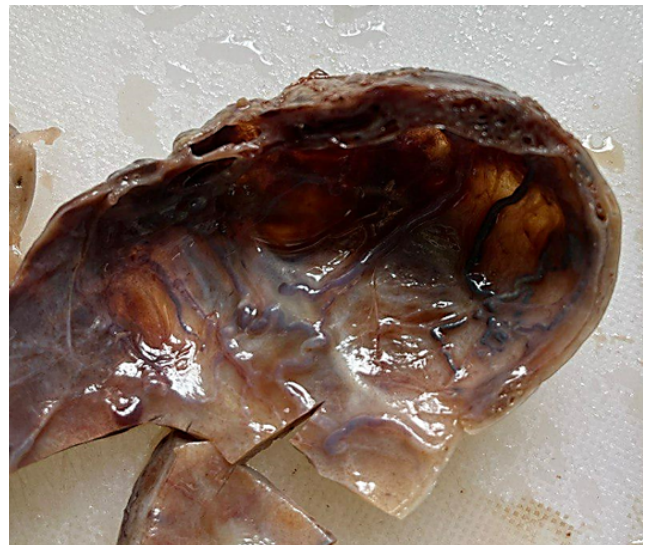


Figure 1: Gross examination of the specimen revealed amultiloculated cyst measuring 7X4X6 cms, with hemorrhagic serous fluid.

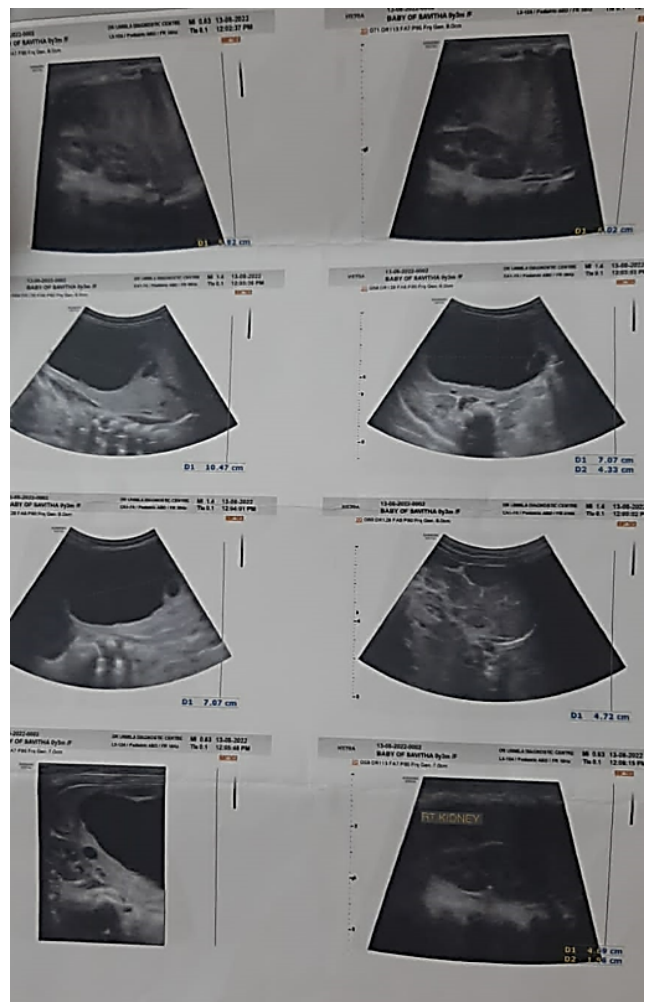


Figure 2:

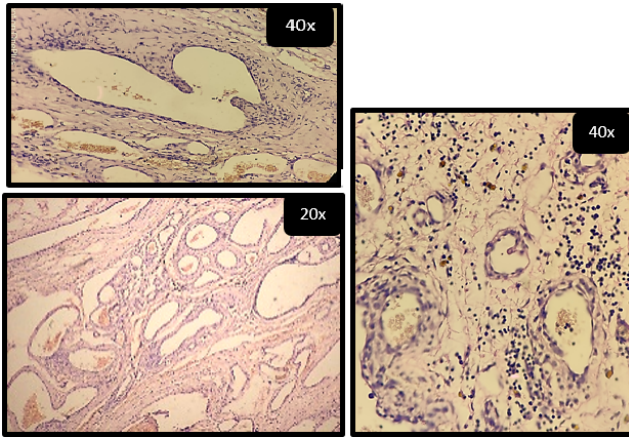


Figure 3: Variably sized, thin walled, dilated lymphatic vessels lined by flattened endothelium. The lumen of these dilated lymphatic vessels shows eosinophilic and amorphous proteinaceous fluid with occasional lymphocytes in them. Focally, the lining of these cysts shows small papillary projections. Also seen is minimal intervening stroma with dilated, congested blood vessels and chronic inflammatory infiltrates.

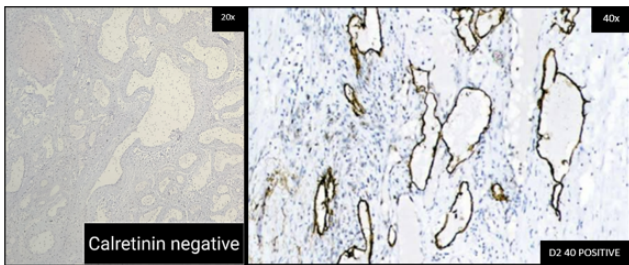


Figure 4:

and mature collagenized connective tissue. The literature shows a predominance of these lesions from the age point of view, the ratio being overwhelmingly balanced to ward childhood.^{4,5} Half of the cases are present at birth, whereas only 10% continue to grow beyond the age of two. The general tendency, from a clinical point of view, is to determine a chronic type of presentation, depending mainly on the rhythm of growth and the size of the tumour. Clinical examination becomes necessary with abdominal pain or the palpable mass, which may or may not modify the symmetry of the abdomen. Most of them are discovered on abdominal ultra sound for another pathology, or unspecific abdominal pain. Few of the cases have an acute onset cystic haemorrhage or infection and few still present in a subacute manner: intestinal obstruction and volvulus. The case management difficulty rises with the rarest eventualities: spontaneous rupture, gastrointestinal bleeding, peritoneal lymphangiomatosis (which could mimic peritoneal carcinomatosis – making the differential diagnosis laborious).

Abdominal ultrasound is the main imaging technique, being reliable as far as the initial evaluation is concerned,

but at the same time non - conclusive. There for CT scan or IRM might be necessary, depending on the size, position, vasculature, malignancy suspicion. The histopathology determines the final diagnostic proof. Here we had a 3 month old female, who presented with excessive crying and irritability for 20 days. On examination, mild hepatomegaly and intra-abdominal mass was noted. USG and NCCT abdomen showed differentials as congenital hepatic cyst and off centred mesenteric cyst respectively. Microscopic examination revealed variably sized, thin walled, dilated lymphatic vessels lined by flattened endothelium.^{6–8} The lumen of these dilated lymphatic vessels had eosinophilic and amorphous proteinaceous fluid with occasional lymphocytes in them. Focally, the lining of these cysts show small papillary projections. Also seen is minimal intervening stroma with dilated, congested blood vessels and chronic inflammatory infiltrates. Immunohistochemical studies showed D2 40 positive and calretinin negative.

The diagnosis of hepatic lymphangioma was made after microscopic examination and IHC. Surgical resection was performed and patient was followed up. The patient after a few months presented with recurrence. Due to smaller size, surgical resection was not performed and the patient was followed up. Further follow ups showed regression of the lesion.^{9,10}

4. Conclusion

Abdominal ultrasound is a good diagnostic tool for hepatic lesions. Abdominal ultrasound along with microscopic findings and IHC markers aids confirmatory diagnosis. Even if hepatic lymphangiomas are rare, there is a need for them to be considered in cystic hepatic lesions in children. Complete surgical resection of hepatic lymphangioma is possible and represents the treatment of choice.

5. Source of Funding

None.

6. Conflict of Interest

None.

References


1. Uduan A, Cocian A, Gocan H. Isolated Hepatic Lymphangiomas in children: Two Case Reports. *J Pediatr Surg Case Rep.* 2020;56:101430. doi:10.1016/j.epsc.2020.101430.
2. Shahi KS, Geeta B, Rajput P. Solitary Hepatic Lymphangioma in a 22-Day-Old Infant. *J Pediatr Surg.* 2009;44(8):9–11.
3. Lee H, Lee S. Case report of solitary giant hepatic lymphangioma. *J Hepato-Biliary-Pancreatic Surg.* 2016;20(2):71–4.
4. Nzegwu MA, Ekenze SO, Okafor OC, Anyanwu PA, Odetunde OA, Olusina DB, et al. Solitary Hepatic Lymphangioma in an Infant. *J Perinat Med.* 2007;35(2):164–5. doi:10.1515/JPM.2007.022.
5. Matsumoto T, Ojima H, Onaya H, Shimada K. Solitary hepatic lymphangioma: Report of a case. *Surg Today.* 2010;40:883–9. doi:10.1007/s00595-010-4255-7.

6. Liu Q, Sui C, Li B, Gao A, Lu J, Yang J, et al. Solitary hepatic lymphangioma: A one - case report. *Springerplus*. 2014;3(1):314. doi:10.1186/2193-1801-3-314.
7. Long L, Zhang L, Cheng Q, Chen Q, Chen XP. Solitary Hepatic Lymphangioma Mimicking Liver Malignancy: A Case Report and Literature Review. *World J Clin Cases*. 2019;8(19):4633–43.
8. Schwartz ME, Roayaie S, Konstadoulakis MM, Gomatos IP, Miller CM. The Mount Sinai experience with orthotopic liver transplantation for benign tumors: brief report and literature review: case reports. *Transplant Proc*. 2008;40(5):1759–62.
9. Ferrero L, Guanà R, Carbonaro G, Cortese MG, Lonati L, Teruzzi E, et al. Cystic intra - abdominal masses in children. *Pediatr Rep*. 2017;9(3):7284. doi:10.4081/pr.2017.7284.
10. Makni A, Chebbi F, Fetirich F, Ksantini R, Bedioui H, Jouini M, et al. Surgical management of intra - abdominal cystic lymphangioma.

Report of 20 cases. *World J Surg*. 2012;36(5):1037–43.

Author biography

Anna Sabu, Post Graduate  <https://orcid.org/0009-0006-2394-8699>

Manasa G.C., Professor  <https://orcid.org/0000-0003-3031-8696>

Cite this article: Sabu A, Manasa G.C. Hepatic lymphangioma in a neonate: A rare case report. *IP J Diagn Pathol Oncol* 2024;9(2):138-141.