

Content available at: <https://www.ipinnovative.com/open-access-journals>

IP Journal of Diagnostic Pathology and Oncology

Journal homepage: <https://www.jdpo.org/>

Case Report

Anterior mediastinal schwannoma: A rare case report

Milan Tripathy¹, Meenakshi Mohapatro^{1*}, Swati Smita Sahoo¹, Deepika Mishra¹, Alakananda Balbantray¹, Shushruta Mohanty²

¹Dept. of Pathology, PGIMER and Capital Hospital, Bhubaneswar, Odisha, India

²Dept. of Pathology, MKCG Medical College & Hospital, Bhubaneswar, Odisha, India



ARTICLE INFO

Article history:

Received 17-07-2023

Accepted 04-10-2023

Available online 05-12-2023

Keywords:

Mediastinal tumors

Neurogenic tumors

Schwannomas

Thymomas

Germ cell tumors

ABSTRACT

Mediastinal schwannomas are rare tumors that develop from peripheral nerve sheath in the mediastinum. Most commonly they are located in posterior mediastinum and are very unusual in anterior mediastinum like the present study of a 51 year old male. He presented with breathlessness, dyspnea and cough for 3 months. Radiological imaging, CT scan reports revealed a cystic SOL in anterior superior mediastinum. The patient underwent thoracotomy and on histopathological examination revealed features of schwannoma which was further confirmed by immunohistochemical study with S-100 protein. Prognosis is good for such tumors and no recurrence is yet reported.

This is an Open Access (OA) journal, and articles are distributed under the terms of the [Creative Commons Attribution-NonCommercial-ShareAlike 4.0 License](https://creativecommons.org/licenses/by-nc-sa/4.0/), which allows others to remix, tweak, and build upon the work non-commercially, as long as appropriate credit is given and the new creations are licensed under the identical terms.

For reprints contact: reprint@ipinnovative.com

1. Introduction

Mediastinal tumours are very rare and are growths arising in the mediastinum. Neurogenic tumours are more common in posterior mediastinum and commonly occur in children. Schwannomas being the most common neurogenic tumors with up to 9% cases in mediastinum.¹ Thymomas, Germ cell tumors commonly arise in anterior mediastinum with schwannomas being very rare arising mostly from intrathoracic peripheral nerves.² They are encapsulated develops from the peripheral nerve sheath.^{1,2} Mediastinal tumours observed as well demarcated lesions with rare calcifications on radiological investigations including chest x-ray computed tomography (CT), magnetic resonance imaging (MRI).³ Histopathological testing through percutaneous puncture biopsy or post-surgery provides a confirmatory diagnosis.^{4,5} Such tumours are treated by resection through thoracoscopy.

2. Case Report

A 51 years old male, complained of breathlessness, dyspnea and intermittent cough since 3 months. He had no history of hypertension, diabetes mellitus, asthma, tuberculosis, chronic heart disease, or allergies. His physical condition was stable, with blood pressure of 114/78 mmHg.

A cystic SOL measuring 7.8x6.1x8.4 cm was discovered during radiological examination (chest X-ray, and thoracic CT scan) (Figure 1) in the anterior superior mediastinum abutting the adjacent portion of arch of aorta. An abdominal ultrasound revealed that the structures of the liver, gallbladder, pancreas and kidneys were normal. Thus a mediastinal tumour was diagnosed. The CT guided fine needle aspiration biopsy (FNAB) results revealed no evidence of malignancy. The patient underwent thoracoscopic surgery, which revealed a cystic, encapsulated anterior superior mediastinal tumor. The tumor was excised (Figure 2). The gross pathology examination revealed that the tumor tissue was partially cystic and solid. On histopathology, the solid area consisted

* Corresponding author.

E-mail address: drmeenakshi1988@gmail.com (M. Mohapatro).

of hypocellular and hypercellular areas of monotonous appearing proliferating cells with oval-spindle wavy nuclei, fine chromatin. (hematoxylin and eosin staining) In denser areas, tumor cells were often arranged in palisades. On Immunohistochemical study it revealed strong staining of S-100 protein, thus clarifying our diagnosis of schwannoma. No signs of malignancy were evident (Figure 3).

Written informed consent was obtained from the patient for the publication of the case report and accompanying images.

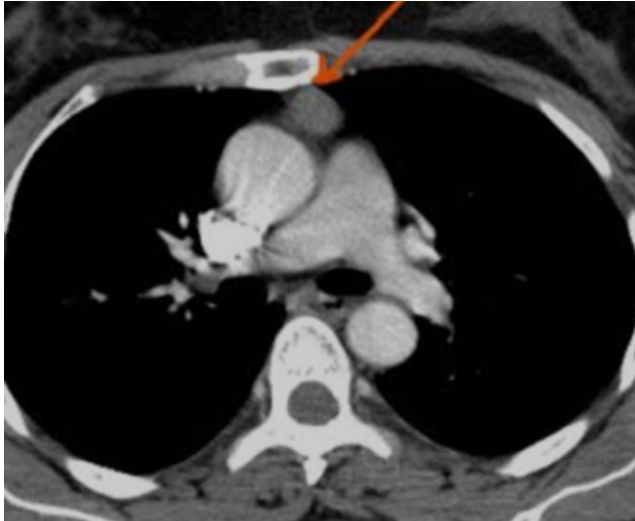

Figure 1: Thoracic CT showing anterior mediastinal mass.

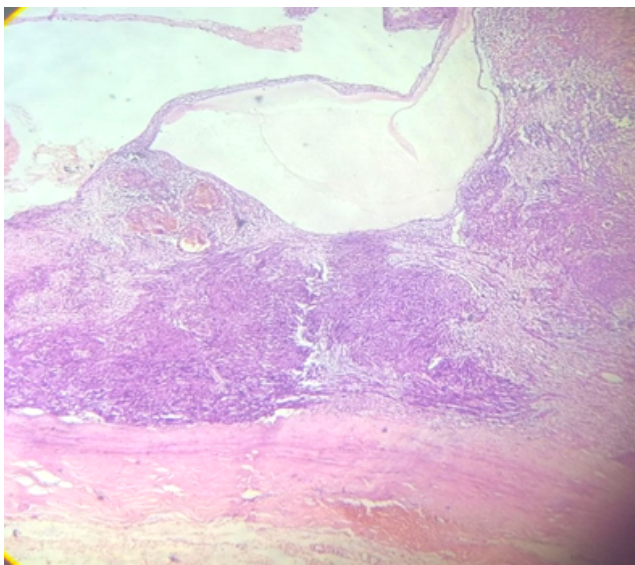


Figure 2: (H&E-40X) Histosection showing tumour with solid and cystic areas

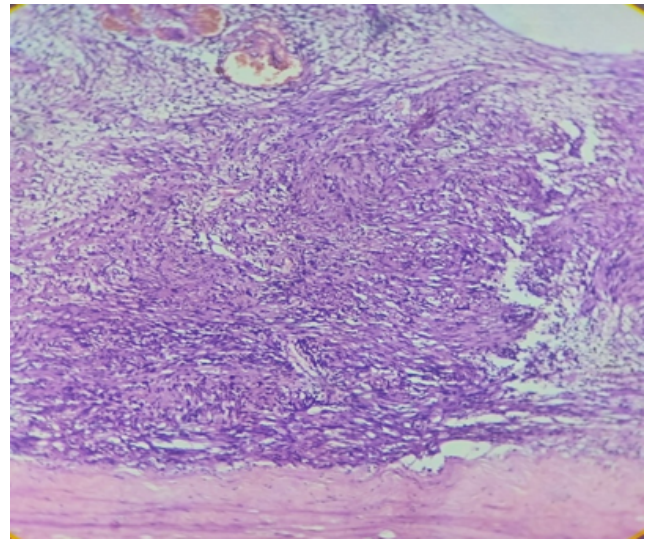


Figure 3: (H&E-200X) solid area showing hypocellular and denser areas with spindle cells having wavy nuclei.

3. Discussions

Mediastinal masses based on the location are classified as anterior, middle and posterior mediastinal tumours. Primary tumours of Anterior mediastinum are mostly Thymomas, germ cell tumours whereas neurogenic tumours are most commonly located in posterior mediastinum.⁶ 12–39% of all mediastinal tumors are Neurogenic tumors of which schwannomas account for around 95%.⁷ Other neurogenic tumors include neurofibroma, neurinoma, sympathetic neuroma, neural sarcoma, paraganglioma, paraganglioma, pheochromocytoma and neuroblastoma.⁸ Schwannoma or neurilemmoma, is a benign peripheral nerve sheath tumor of Schwann cell origin.^{9,10} Neurogenic tumors are slow growing, arising from mediastinal peripheral nerves, sympathetic and parasympathetic ganglia, and embryonic remnants of nerve sheaths.¹¹ These tumors typically develop from spinal nerve roots, can also develop from intrathoracic nerves. Schwannomas can also be discovered in lungs in about 0.2% of cases.¹²

Clinical symptoms of mediastinal benign schwannoma include cough, chest discomfort and obstructive pneumonia. May sometime present as facial edema and pericardial effusion.¹³ Mediastinal tumors can be detected by radiological investigations like Chest X-ray, MRI, Enhanced chest CT where they appear as well-defined lesions with or without calcifications.¹² On a CT scan, schwannoma appears as spherical, smooth, hypodense lesions with or without cystic patches. Histopathological examination of a schwannoma reveals macroscopic features of a grey-white tumor that is well-defined, encapsulated, solid may exhibit cystic degeneration.¹⁴ Microscopic histological examination revealed the proliferation of Schwann cells with spindle wavy nuclei and pointed ends, with 2 growth

patterns identified: Antony A (hypercellular, with nuclei foci arranged like palisades called Verocay bodies) and Antony B (hypocellular, loosely arranged).¹⁵ Subsequent immunohistochemical analysis with S-100 protein further aid in the definite diagnosis.¹⁶

The treatment for all benign neurogenic tumors is surgical resection, except for neuroblastoma.^{14,15} The thoracotomy surgical technique is used for resection of large mediastinal tumors, whereas video-assisted thoracoscopy is ideal for smaller tumor masses free from surrounding vital structures.¹

4. Conclusion

To conclude, schwannomas in anterior mediastinum is a rare finding. Multiple imaging techniques, such as CT, MRI along with histopathological and immunohistochemical studies aid to arrive at a definitive diagnosis of mediastinal tumours. Schwannomas are treated surgically by thoracotomy or VATS (video assisted thoracoscopic surgery). Mediastinal schwannomas have good prognosis with no recurrence reported till date.

5. Conflict of Interest

None.

6. Source of Funding

None.

References

1. Kapoor A, Singhal MK, Narayan S, Beniwal S, Kumar HS. Mediastinal schwannoma: a clinical, pathologic, and imaging review. *South Asian J Cancer*. 2015;4(2):104–5.
2. Strollo DC, Rosado-De-Christenson ML, Jett JR. Primary mediastinal tumors: part II. Tumors of the middle and posterior mediastinum. *Chest*. 1997;112(5):1344–57.
3. Tomiyama N, Honda O, Tsubamoto M, Inoue A, Sumikawa H, Kuriyama K, et al. Anterior mediastinal tumors: Diagnostic accuracy of CT and MRI. *Eur J Radiol*. 2009;69(2):280–8.
4. Marchevsky AM. Mediastinal tumors of peripheral nervous system origin. *Semin Diagn Pathol*. 1999;16(1):65–78.
5. Wijaya SY, Koesoemoprodjo W. Indonesian female with bilateral chylothorax and mediastinal non-Hodgkin lymphoma: A case report. *Int J Surg Case Rep*. 2023;p. 102:107827. doi:10.1016/j.ijscr.2022.107827.
6. Priola AM, Priola SM, Cardinale L, Cataldi A, Fava C. The anterior mediastinum: Diseases. *Radiol Med (Torino)*. 2006;111(3):312–42.
7. Shimizu J, Arano Y, Murata T, Ishikawa N, Yachi T, Nomura T, et al. A case of intrathoracic giant malignant peripheral nerve sheath tumor in neurofibromatosis type I (von Recklinghausen's disease). *Ann Thorac Cardiovasc Surg*. 2008;14(1):42–7.
8. Hussein HA, Goda HA. Paravertebral neurogenic tumors with intraspinal extension: Preoperative evaluation and surgical approach. *J Egypt Natl Canc Inst*. 2009;21(1):12–22.
9. O'sullivan P, Dwyer H, Flint J, Munk PL, Muller N. Soft tissue tumours and mass-like lesions of the chest wall: a pictorial review of CT and MR findings. *Br J Radiol*. 2007;80(955):574–80.
10. Maranatha D, Yuniati SK. Seorang Laki-Laki dengan tumor mediastinal posterior (malignant peripheral nerve sheath tumor): [malignant peripheral nerve sheath tumor in a man: a case report. *Jurnal Respirasi*. 2016;2(3):82–90.
11. Quartey B, Lenert J, Deb SJ, Henry LR. Giant posterior mediastinal ancient schwannoma requiring Thoracoabdominal resection: a case report and literature review. *World J Oncol*. 2011;2(4):191–4.
12. Yukawa T, Shimizu K, Hiramitsu Y, Okita R, Saisho S, Maeda A, et al. A case report of intrapulmonary schwannoma. *Gen Thorac Cardiovasc Surg*. 2014;62(4):252–4.
13. Mordant P, Pimpec-Barthes FL, Riquet M. Neurogenic tumors of the mediastinum in adults. *Rev Pneumol Clin*. 2010;66(1):81–94.
14. Chrysikos S, Kaponi M, Triantafyllidou C, Karampitsakos T, Tzouveleki A, Anyfanti M, et al. A rare case of primary intrapulmonary Neurilemmoma diagnosed in a 43-year-old asymptomatic man with a well-defined intrapulmonary mass. *Front Oncol*. 2018;8:11. doi:10.3389/fonc.2018.00011.
15. Kale SS, Gosavi VS, Jagadale RV. Ancient chest wall schwannoma: A case report with review of literature. *Med J DY Patil Univ*. 2015;8(4):505–7.
16. Cho JH, Kim J, Kim K, Choi YS, Hk KIM, Shim YM, et al. A comparative analysis of video-assisted mediastinoscopy and conventional mediastinoscopy. *Ann Thorac Surg*. 2011;92(3):1007–11.

Author biography

Milan Tripathy, Assistant Professor

Meenakshi Mohapatro, Assistant Professor

Swati Smita Sahoo, Assistant Professor

Deepika Mishra, Senior Resident

Alakananda Balbantray, Senior Resident

Shushruta Mohanty, Assistant Professor

Cite this article: Tripathy M, Mohapatro M, Sahoo SS, Mishra D, Balbantray A, Mohanty S. Anterior mediastinal schwannoma: A rare case report. *IP J Diagn Pathol Oncol* 2023;8(4):241-243.