

Content available at: <https://www.ipinnovative.com/open-access-journals>

IP Journal of Diagnostic Pathology and Oncology

Journal homepage: <https://www.jdpo.org/>

Case Report

Ovarian myeloid sarcoma with concurrent acute myeloid leukemia- A case report

Brijesh Thakur^{1*}, Seema Acharya¹, Sucheta Bansal¹, Priti Mishra¹

¹Dept. of Pathology, Shri Guru Ram Rai Institute of Medical & Health Sciences, Dehradun, Uttarakhand, India



ARTICLE INFO

Article history:

Received 10-06-2023

Accepted 29-08-2023

Available online 05-12-2023

Keywords:

Child

Flowcytometry

IHC

Myeloid sarcoma

Ovary

ABSTRACT

Introduction: Myeloid sarcoma is a rare extramedullary tumor of immature myeloid cells that can be composed of cells showing granulocytic or monocytic differentiation. It is frequently detected as masses in subcutaneous soft tissue, bone, skin, GIT, reproductive organs, CNS, heart, lungs, kidney and breast. We report a pediatric case of myeloid sarcoma presenting with bilateral ovarian masses.

Case Report: A 12 years old female presented with complaints of fever, lethargy, decreased appetite and easy fatigability. Patient further developed swelling and pain in large joints along with slurring of speech and difficulty in swallowing. Examination revealed polyserositis along with hepatosplenomegaly. ANA IFA profile was positive. CECT abdomen showed heterogeneous lesions in bilateral adnexae along with a few enlarged matted lymph nodes in left para-aortic region (?Neoplastic/ ?Histiocytosis/ ?EM hematopoiesis). GBP was suggestive of leucoerythroblastic reaction. BM study with flowcytometry was suggestive of Acute myeloid leukemia with monocytic differentiation. Biopsy from both adnexae showed features consistent with poorly differentiated malignancy, favour haematolymphoid neoplasm. Immunophenotyping by IHC showed the cells to be positive for CD45 (dim), MPO & CD117, thus establishing diagnosis of Myeloid sarcoma, both ovaries.

Conclusion: Myeloid sarcoma is uncommon ovarian neoplasm and the clinical presentation may be with or without acute leukemia / MPN. Immunohistochemistry and ancillary studies are necessary to recognize this entity.

This is an Open Access (OA) journal, and articles are distributed under the terms of the [Creative Commons Attribution-NonCommercial-ShareAlike 4.0 License](https://creativecommons.org/licenses/by-nc-sa/4.0/), which allows others to remix, tweak, and build upon the work non-commercially, as long as appropriate credit is given and the new creations are licensed under the identical terms.

For reprints contact: reprint@ipinnovative.com

1. Introduction

Myeloid sarcoma (MS) is an extramedullary tumoral mass composed of immature myeloid cells myeloblasts, previously also known as Granulocytic Sarcoma (GS) and Chloroma (Chloro=Green in Greek) because of macroscopic greenish hue attributed to high myeloperoxidase content. MS is usually associated with concurrent acute myeloid leukemia (AML), but may represent post therapy relapse in cases of AML, myeloproliferative neoplasm (MPN), or myelodysplastic syndrome (MDS).^{1,2} More frequently involved sites in

pediatric population are skin, soft tissue and orbit.^{3,4} MS in the female genital tract occurs more commonly in the ovary and uterus, however, few cases have been described involving the vulva, vagina or cervix.^{1,5}

Incidence of MS in children has been reported from 5.7% to 40% with an average of 10-25% as compared to only 4-9% in adults. The reason is not elucidated about this discrepancy but thought to be attributed to differences in diagnostic evaluations performed or inherent differences in mutational spectrum of the leukemias developing in children. Fluorodeoxyglucose (FDG) positron emission tomography (PET) scans are increasingly being used for diagnosing extramedullary disease (displaying moderate uptake of FDG), particularly in paediatric cases with

* Corresponding author.

E-mail address: drbrijeshthakur03@gmail.com (B. Thakur).

medullary involvement.⁶

We report a pediatric case of myeloid sarcoma presenting with bilateral ovarian masses.

2. Case Report

A 12 years old female presented to pediatric OPD with fever, polyarthritis, polyserositis and mild to moderate ascites with clinical suspicion of Systemic-onset Juvenile Idiopathic Arthritis. She gave history of being prescribed steroids, multivitamins and three units of blood transfusion one month back. She recently developed nasal intonation of voice with 2-3 episodes of vomiting and difficulty in deglutination, although there was no history of nasal regurgitation. CECT scan (abdomen) revealed moderate ascites, hepatomegaly, heterogeneously enhancing areas in bilateral adnexae, pelvic bones, sacrum and lumbar vertebral bodies, suggestive of possibilities including Neoplastic /Histiocytosis /Extramedullary hematopoiesis. MRI (Brain) revealed subdural collections with mild pachymeningitis. Routine haematological investigations revealed; Hb:5.3gm%, TLC:8310 cells/cumm., DLC: N55%, L32%, M10%, Immature cells03%. GBP was suggestive of leucoerythroblastic reaction. Bone marrow aspirate smears were hemodiluted and aparticulate, however bone marrow biopsy imprint smears revealed a few atypical cells. Bone marrow biopsy sections showed suppressed hematopoiesis and diffuse infiltration by small to medium sized atypical cells/ blasts, suggestive of hematology malignancy. Histomorphological evaluation of guided core biopsies from ovarian masses showed sheets of small to intermediate sized cells and differential diagnoses of hematology malignancy and granulosa cell tumor were considered.

Additional sections from bone marrow biopsy and ovarian mass core biopsy were taken on Poly-L-lysine coated slides and subjected to immunostaining for IHC panel (CD45, CD34, TdT, CD3, CD20, CD10, MPO, CD4, CD68, CD117, Ki-67). Tumor cells were positive for CD45 (dim), MPO, CD4, CD68 and CD117 while negative for CD34, TdT, CD3 and CD20. Ki-67 proliferation index was 85%. A final diagnosis of Ovarian Myeloid Sarcoma with monocytic differentiation was made and further molecular studies were suggested.

3. Discussion

MS are immature cell proliferations that are morphologically composed of myeloblasts, monoblasts/promonocytes, and rarely promyelocytes along with a variable number of mature myeloid cells leading to effacement of architecture of tissue/ organ. A majority of cases have myelomonocytic or pure monoblastic morphology and immunophenotype.² Symptomatic involvement of the female genital tract is a rare presentation

of extramedullary AML.⁵ GS of the genital tract appeared more frequent in women than in men. There is no clear explanation for this male/female discrepancy. However, several publications have reported concomitant granulocytic sarcoma of the female gynecologic tract and granulocytic sarcoma in breasts. It has then been postulated that some AML may have steroid hormonal receptors, which was not confirmed further.⁵ Oliva et al. described a series of 11 cases of GS of the female genital tract, 7 of which presented as ovarian masses.⁷

The morphological differential diagnoses include a variety of malignant tumors, of which the most common ones are malignant lymphoma, neuroblastoma, small cell carcinoma, primitive neuroectodermal tumor, rhabdomyosarcoma and undifferentiated tumor. MS has been subdivided into two categories, either granulocytic or monoblastic, based on morphology.⁴ The gold standard for diagnosis is biopsy / fine needle aspiration complemented with immunophenotype (IPT) by IHC or flowcytometry. Touch imprint smears prepared from biopsy fragments can be subjected to special cytochemical stains like myeloperoxidase or Sudan black B along with flowcytometry of bone marrow aspirate. At times, there is also a need to perform a follow-up bone marrow aspiration and biopsy to rule out simultaneous bone marrow involvement.

IPT has proved that MS can express multiple lineages within a same tumour.⁴ Variable expression of CD68/KP1, MPO, CD117, CD99, CD68/PG-M1, and lysozyme, concordant with the myelomonocytic differentiation, can be seen. Other than these markers, CD34, TdT, CD56, CD30, glycophorin A, and CD4 are also useful for diagnosis. CD68 and MPO are commonly expressed, whereas CD34 is negative, especially in cases with monocytic differentiation. Patra et al. evaluated 38 cases of MS and found commonest location being lymph node (12/38, 31%), followed by breast, vertebra and other unusual sites. Myeloperoxidase (MPO) (31/38, 81.5%), CD117 (25/35, 71.4%), CD45 (21/23, 91.3%), CD43 (14/22, 63.6%), CD68 (12/28, 42.8%), CD34 (15/37, 40.5%), CD33 (14/14, 100%), CD13 (15/16, 93.7%), HLA-DR (11/12, 91.6%), CD99 (3/29, 10.3%) and TdT (1/9, 11.1%) were expressed by tumor cells. Negative expression of epithelial, mesenchymal, B and T lymphoid markers was noted.⁴

Akyol et al. described a 42 years old female patient with left ovarian myeloid sarcoma exhibiting positive immunorexpression with LCA, CD117, MPO, CD43, lysozyme, CD34, and CD68, in the absence of a history of leukemia.⁸ Kahn et al. presented a case of a 48 years old woman with MS involving the uterine corpus, fallopian tubes, and left ovary, after post-therapy clinical remission.⁹ Ding et al. also reported a 27 years old female, with a diagnosis of undifferentiated ovarian MS mass expressing focal CD45 and CD68 along with strong MPO and CD43

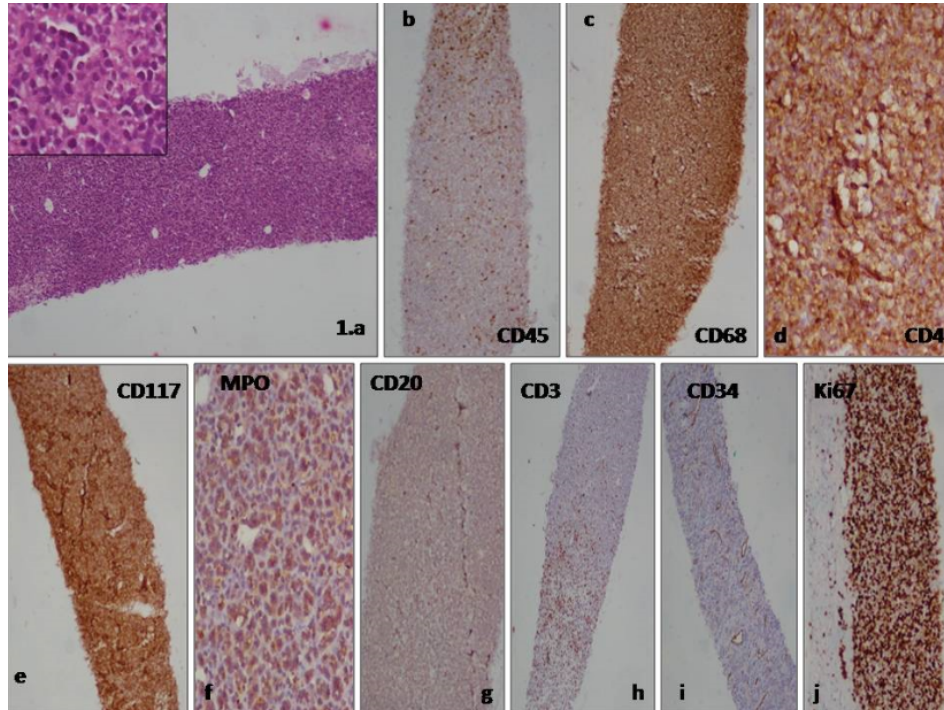


Figure 1: Core biopsy from ovarian mass showing sheets of small to intermediate sized cells (a) with positive expression of dim CD45 (b), CD68 (c), CD4 (d), CD117 (e), MPO (f), and negative expression of CD20 (g), CD3 (h), CD34 (i) with high Ki-67 index (j).

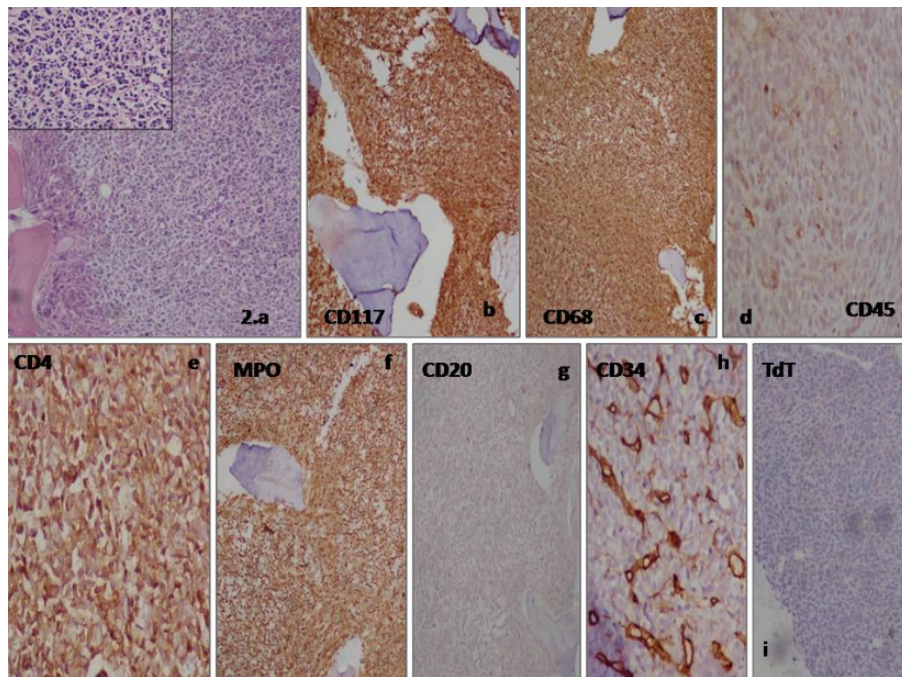


Figure 2: Bone marrow biopsy showing sheets of small to intermediate sized cells (a) with positive expression of CD117 (b), CD68 (c), dim CD45 (d), CD4 (e), MPO (f) and negative expression of CD20 (g), CD34 (h), TdT (i).

positive reaction. Bone marrow studies confirmed the diagnosis of AML.¹⁰

Choi et al. discussed a case of bilateral ovarian masses in a 30 years old patient diagnosed as acute myelomonocytic leukemia, wherein treatment was successful with high-dose chemotherapy, followed by allogenic hematopoietic stem cell transplantation without oophorectomy. CT and PET follow-up examination revealed markedly decreased size and obliteration of FDG uptake of both ovarian masses.¹¹

Management modalities of MS include systemic and local treatment involving chemoradiotherapy, targeted therapy, and bone marrow transplantation. The outcome of patients suffering from MS is usually poor. Literature mentions an approximate 5-year survival rate of 20% with appropriate therapeutic interventions.¹ Treatment of uterine myeloid sarcoma has been described with combinations of surgery, radiation and chemotherapy. Surgical resection of the bulk of the tumor has only a diagnostic value, and patients should receive adjuvant chemotherapy. Granulocytic sarcoma responds well to radiotherapy, but it is unclear whether radiotherapy improves survival.⁵ The overall survival and prognostic factors are ill-defined and vary significantly depending on the patient's age, sex, race, and sites of presentation.¹²

4. Conclusion

Clinical presentation of acute myeloid leukemia (AML) in infants and pediatric age group as an ovarian tumor is rare. Isolated MS in differential diagnosis in its primary presentation is necessary to prevent misdiagnosis and to proceed for early treatment of these patients.

5. Conflict of Interest

The authors do not have any conflicts of interest.

6. Source of Funding

None.

References

- Jadhav T, Baveja P, Sen A. Myeloid sarcoma: an uncommon presentation of myeloid neoplasms; a case series of 4 rare cases reported in a tertiary care institute. *Autops Case Rep.* 2021;11:e2021339. doi:10.4322/acr.2021.339.

- Kaygusuz G, Kankaya D, Ekinci C, Topcuoğlu P, Kuzu I. Myeloid Sarcomas: A Clinicopathologic Study of 20 Cases. *Turk J Haematol.* 2015;32(1):35–42.
- Samborska M, Derwich K, Sadowska JS, Kurzawa P, Wachowiak J. Myeloid sarcoma in children - diagnostic and therapeutic difficulties. *Contemp Oncol (Pozn).* 2016;20(6):444–8.
- Patra S, Parikh BP, Kaur K. Myeloid Sarcoma: Evaluation of Histopathology, Immunoprofile and Cytogenetics. *J Clin Diagn Res.* 2021;15(3):10–4.
- Quintela A, Ducreux S, Lequeu H, Chassagne C, Plesa A, Jeune C, et al. Granulocytic Sarcoma Involving the Gynecologic Tract: One Case Report and Review of the Literature. *Ann Hematol Oncol.* 2015;2(8):1058.
- Zorn KE, Cunningham AM, Meyer AE, Carlson KS, Rao S. Pediatric Myeloid Sarcoma, More than Just a Chloroma: A Review of Clinical Presentations, Significance, and Biology. *Cancers (Basel).* 2023;15(5):1443. doi:10.3390/cancers15051443.
- Oliva E, Ferry JA, Young RH, Prat J, Srigley JR. Granulocytic sarcoma of the female genital tract: a clinicopathologic study of 11 cases. *Am J Surg Pathol.* 1997;21(10):1156–65.
- Akyol S, Atalay F. Primary Myeloid Sarcoma of Ovary: A Case Report and Review of the Literature. *Turk Patoloji Derg.* 2021;37(3):249–53.
- Kahn RM, Gordhandas S, Chapman-Davis E, Margolskee E, Matrai C, Chadburn A, et al. Acute Myeloid Leukemia Presenting as Myeloid Sarcoma with a Predisposition to the Gynecologic Tract. *Case Rep Oncol Med.* 2019;p. 4189275. doi:10.1155/2019/4189275.
- Ding J, Li H, Qi Y, Wu J, Liu Z, Huang B, et al. Ovarian granulocytic sarcoma as the primary manifestation of acute myelogenous leukemia. *Int J Clin Exp Pathol.* 2015;8(10):13552–6.
- Choi JY, Kim HY, Kang MG, Shin JK, Lee WS, Song HN, et al. Bilateral ovarian granulocytic sarcoma as the primary manifestation of acute myelogenous leukemia treated with allogenic stem cell transplantation: A case report. *Medicine.* 2019;98(52):e18390. doi:10.1097/MD.00000000000018390.
- Weber A, Ovilla R, Mateos AS, Weber P. Ovarian Granulocytic Sarcoma in a Patient with Philadelphia Chromosome-Positive Acute Biphenotypic Leukemia: Case Report. *Med J Clin Trials Case Stud.* 2019;3(2):000203. doi:10.23880/mjccs-16000203.

Author biography

Brijesh Thakur, Professor  <https://orcid.org/0000-0002-4600-5267>

Seema Acharya, Professor and HOD

Sucheta Bansal, Senior Resident

Priti Mishra, Junior Resident IIIrd Year

Cite this article: Thakur B, Acharya S, Bansal S, Mishra P. Ovarian myeloid sarcoma with concurrent acute myeloid leukemia- A case report. *IP J Diagn Pathol Oncol* 2023;8(4):237-240.