

Content available at: <https://www.ipinnovative.com/open-access-journals>

IP Journal of Diagnostic Pathology and Oncology

Journal homepage: <https://www.jdpo.org/>

## Case Report

# Male breast cancer: Clinicopathological characteristics

Sunil V. Jagtap<sup>1,\*</sup>, Shubham S. Jagtap<sup>2</sup>, Harsh Machhi<sup>1</sup>, Vaibhav Chavan<sup>1</sup>,  
Manasi Bhade<sup>1</sup>

<sup>1</sup>Dept. of Pathology, KVV, Krishna Institute of Medical Sciences Deemed University, Karad, Maharashtra, India

<sup>2</sup>Dept. of Medicine, KVV, Krishna Institute of Medical Sciences Deemed University, Karad, Maharashtra, India



### ARTICLE INFO

#### Article history:

Received 23-06-2023

Accepted 02-08-2023

Available online 28-08-2023

#### Keywords:

Lump in breast

Mastectomy

Male breast cancer

Invasive breast carcinoma

### ABSTRACT

**Background :** Male breast cancer is a very rare neoplasm which accounts for 1% of all breast cancers. In males breast tissue is much smaller than females and these cancer can easily invade the skin and pectoral muscles.

**Case Presentation:** A 62-year old male patient with chief complaint of swelling in right breast since 6 months, the size of which had increased rapidly in last three months and associated with pain. Sonomammography reveals lobulated hypoechoic lesion in right retroareolar region. Fine needle aspiration cytology reported as positive for carcinoma cells right breast. Right breast modified radical mastectomy was performed. On histopathological findings reported as invasive breast carcinoma. RB score: 1+2+2=5 Grade I. The immunohistochemistry for hormone receptor showed positive estrogen receptor (ER) and progesterone receptor (PR), while HER2 was negative. All surgical margins and lymph nodes received from right axillary clearance were free from tumor.

**Conclusion:** We are presenting this extremely rare case of male breast cancer for its clinico-pathological findings. The tumor was medium size, with no axillary lymph node metastasis and on histopathology reported as invasive breast carcinoma grade I, which favored good prognostic criteria.

This is an Open Access (OA) journal, and articles are distributed under the terms of the [Creative Commons Attribution-NonCommercial-ShareAlike 4.0 License](https://creativecommons.org/licenses/by-nc-sa/4.0/), which allows others to remix, tweak, and build upon the work non-commercially, as long as appropriate credit is given and the new creations are licensed under the identical terms.

For reprints contact: [reprint@ipinnovative.com](mailto:reprint@ipinnovative.com)

## 1. Introduction

Male breast cancer represents a rare malignancy, with the incidence of less than 1 case in 100,000 men. The breast cancer in male with respect to women is 1: 100.<sup>1</sup> In recent years, there has been an increase in the incidence of this disease. Male patients with new-onset breast masses are recommended to undergo diagnostic mammograms and breast ultrasound for further evaluation. Mammography has demonstrated 90% sensitivity and specificity in terms of diagnosing male breast cancer.<sup>2</sup> The carcinoma of the male breast has many similarities with the breast cancer which occurs in women. Male breast cancer is more likely to be

ER, PR hormone receptor positive and less likely to be HER2 positive than female breast cancer.<sup>3</sup>

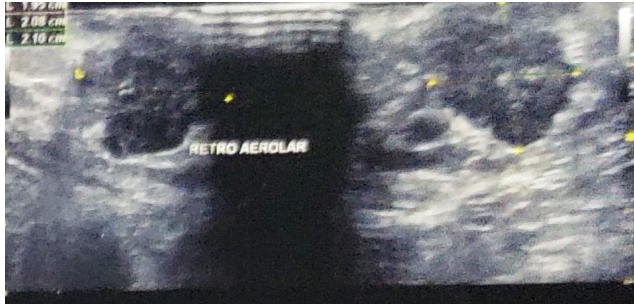## 2. Case Report

A 62 year old male patient with chief complaint of swelling in right breast since 6 months, the size of which had increased rapidly in last three months and associated with pain. The overlying skin was ulcerated with areas of necrosis. The nipple, areola were retracted. The right axillary lymphadenopathy was noted. Also left breast gynecomastia was noted. There was no lymphadenopathy in left axillary region. There was no history of trauma, familial breast cancer, gynecomastia, solid organ tumor, hormonal treatment or any other malignancies. Both testicles were

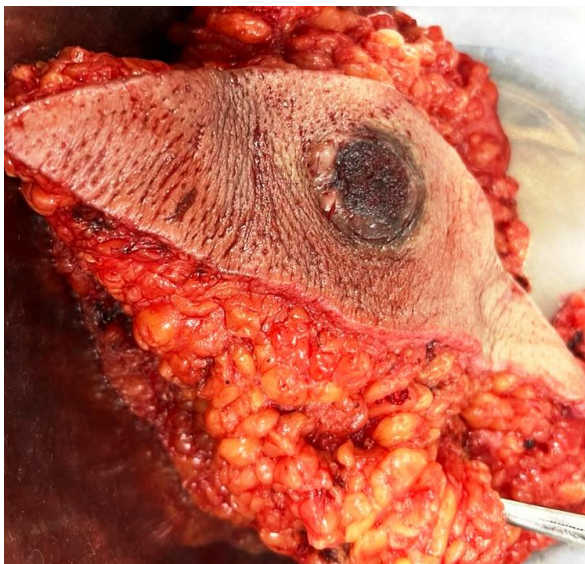
\* Corresponding author.

E-mail address: [drsvjagtap@gmail.com](mailto:drsvjagtap@gmail.com) (S. V. Jagtap).

normal. The routine haematological and biochemical investigations were normal. Sonomammography reveals lobulated hypoechoic lesion in right retroareolar region, possibility of malignant mass on the right breast was given (Figure 1). On radiological investigations of abdomen and pelvis there was no evidence of metastasis. Fine needle aspiration cytology was performed, which yielded hyper cellular smears of malignant neoplastic epithelial cells, reported as positive for carcinoma cells right breast. Left breast FNAC is suggestive of benign breast lesion. The excision of left breast lump was done.

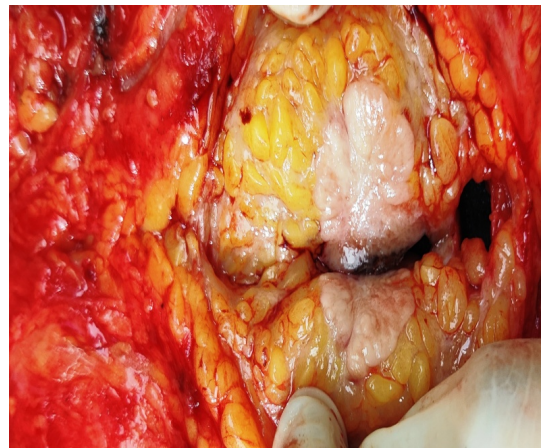


**Fig. 1:** Sonomammography: nodular, irregular mass lesion, with macrolobulations, hypoechoic mass, located in the retroareolar region of the right breast.

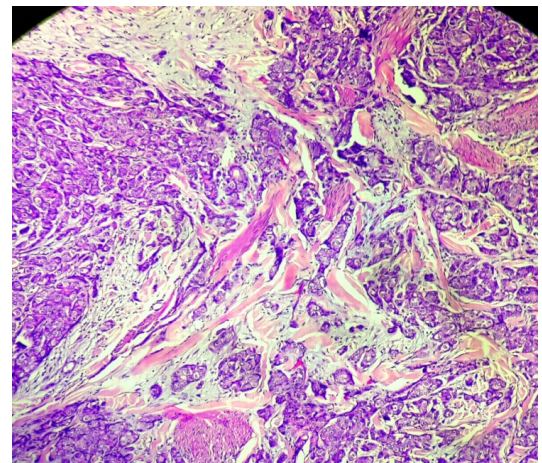


**Fig. 2:** The grossspecimen right breast mass with ulceration at nipple areola.

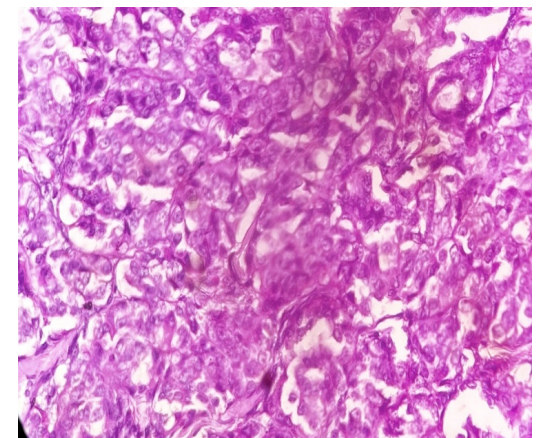
Right breast modified radical mastectomy was performed. (Figure 2). On gross we received specimen right right breast with mass measuring 23 x 12 x 3 cm, and weigh 361 grams. Covering skin flap measured 17 x 4.5 cm. Nipple and areola was ulcerated, inflamed, necrosed and retracted. Serial cut sectioning revealed a



**Fig. 3:** Cut surface of tumor -grey white, firmwith infiltrating borders.



**Fig. 4:** Right breast invasive breast carcinoma Grade I with areas of myxoid changes(H &E stain, 100x)



**Fig. 5:** Right breast invasive breast carcinoma Grade I(H &E stain, 400x)

tumor measuring 3 x 2.5 x 2 cm, located in subareolar region. Tumor was grey white, firm in consistency, showed infiltrating borders. (Figure 3). Deep surgical margin is 0.5 cm away from the tumor. Overlying skin is 0.2 cm away from the tumor. The peripheral surgical margin was 4 cm away from tumor. Adjacent breast tissue appears unremarkable. Right axillary clearance showed fatty, grey yellow tissue measured 12 x 8 x 1.5 cm. Serial cut section revealed 11 lymph nodes. Largest lymph node measured 2.5 x 1.5 x 0.5 cm. On histopathological findings of right modified mastectomy reported as invasive breast carcinoma. Elston–Ellis modification of the Bloom and Richardson grading classification score: 1+2+2=5 Grade I with areas of inflammation, mxyoid change and tumor is invading nipple areola complex. (Figures 4 and 5). All surgical margins and 11 lymph nodes received from right axillary clearance were free from tumor. The immunohistochemistry for hormone receptor–showed positive estrogen receptor (ER) and progesterone receptor (PR), while was HER2 neu negative.

### 3. Discussion

Male breast cancer is a rare neoplasm which accounts for 1% of the total cases of breast cancer.<sup>4</sup> Male breast cancer is most often present between the ages of 60 - 70 years. The various etiological risk factors of male breast cancer are given are potential genetic, environmental ,older age, hormone therapy, exposure to estrogen, cirrhosis of the liver, Klinefelter’s syndrome, Cowden syndrome (PTEN tumor suppressor gene), Obesity, orchiectomy, family history of breast cancer etc can increase risk of male breast cancer.<sup>4</sup> Male with BRCA2 carrier mutation have a 6% increased risk and BRCA1 with a 4% risk of developing the male breast cancer.<sup>5</sup>

Clinically male breast cancer patients commonly present with painless mass in a unilateral breast. Other potential symptoms include nipple retraction, nipple discharge, ulceration, pain, redness of skin Nipple discharge. There is frequent involvement of the skin or the chest wall, which leads to its fixation. In our case it was invading the overlying skin and nipple areola complex. Synchronous, bilateral male breast cancer is an exceptional finding in male breast.<sup>6</sup> The commonest cause of male breast enlargement is gynaecomastia. The gynecmastia may mask the condition.

The various diagnostic procedures used are local breast examination, ultra sonomammogram, magnetic resonance imaging, fine-needle aspiration cytology, core niddle biopsy, incisional or excisional biopsy. Mammography is a useful tool to differentiate between breast cancer and gynecomastia.<sup>7</sup> The ultrasound-guided core biopsy gives the most definitive diagnosis of MBC.

On histopathology, the most common type of breast cancer in male is invasive breast carcinoma(90%) other types are medullary, papillary, lobular ,mucinous

carcinoma, tubular carcinoma.<sup>8,9</sup> In male the commonest histopathological type detected is invasive breast carcinoma grade 2, no special type. The lymph node metastases are more common in men than women. The staging workup regarding male breast cancer is classified similarly to breast cancer in females and consists of the tumor type, nodal status and metastasis (TMN) staging system. But due to common delayed in diagnosis, approximately 40% of all male breast cancer at the initial diagnosis are at advanced stage i.e III or IV disease.<sup>10</sup>

The hormone expression in male breast cancer, approximately 90 % express the estrogen receptor (ER), and 81% express the progesterone receptor.<sup>11</sup> In our case, immunohistochemical staining, the tumor was positive for estrogen receptors and progesterone receptors, whereas HER2 receptor status was negative.

In our case, tumor was medium size, with no axillary lymph node metastasis and on histopathology reported as invasive breast carcinoma grade I, which favored good prognostic criteria. The several studies have mentioned axillary lymph node metastasis is between 50% and 65%. Patients with lymph node metastasis have a 50% higher risk of mortality than those without lymph node involvement.<sup>11</sup> The various poor prognostic factors for male breast cancers are, tumor size over 2 cm, presence of lymphatic tumor emboli, poor histological differentiation, HER2 overexpression, p53 expression.

For early-stage disease, treated with mastectomy and axillary lymph node dissection. The simple or modified radical mastectomies are the preferred choice of resection. Additional plan of management is radiation, hormonal therapy and chemotherapy as per requirement are also used.<sup>5</sup> In our case patient responded well to treatment and there was no evidence of recurrence or any metastasis on follow up.

### 4. Conclusion

We are presenting this extremely rare case of male breast cancer for its clinico-pathological findings. The tumor was medium size, with no axillary lymph node metastasis and on histopathology reported as invasive breast carcinoma grade I, which favored good prognostic criteria.

### 5. Conflict of Interest

The authors declare that there are no conflicts of interest pertaining to the publication of this paper.

### 6. Source of Funding

None.

### References

1. Wroński K. Male breast cancer - case report and review of literature. *New Med.* 2014;2:52–4.




2. Liu N, Johnson KJ, Ma CX. Male Breast Cancer: An Updated Surveillance, Epidemiology, and End Results Data Analysis. *Clin Breast Cancer*. 2018;18(5):997–1002. doi:10.1016/j.clbc.2018.06.013.
3. Evans DG, Susnerwala I, Dawson J, Woodward E, Maher ER, Lalloo F, et al. Risk of breast cancer in male BRCA2 carriers. *J Med Genet*. 2010;47(10):710–1.
4. Ruddy KJ, Winer EP. Male breast cancer: risk factors, biology, diagnosis, treatment, and survivorship. *Ann Oncol*. 2013;24(6):1434–43.
5. Harris JR, Lippman ME, Morrow M, Osborn CK. Male breast cancer. In: *Disease of the Breast*. Philadelphia, Lippincott Williams and Wilkins; 2000. p. 661–7.
6. Jagtap SV, Chougule PG, Khatib W, Shukla DB, Jagtap SS. Male breast cancer: presenting as synchronous, large, bilateral masses. *J Clin Diagn Res*. 2014;8(4):7–8.
7. Khan L, Dixon M. Case report: Male breast cancer. *Am J Hematol/Oncol*. 2016;12(6):11–4.
8. Giordano S. A review of the diagnosis and management of male breast cancer. *The Oncologist*. 2005;10:471–9. *Oncologist*. 2005;10(7):471–9. doi:10.1634/theoncologist.10-7-471.
9. Jagtap SV, Beniwal A, Chougule PG. Invasive lobular carcinoma of breast histopathological subtypes: clinicopathological study. *Int J Health Sci Res*. 2016;6(7):105–11.
10. Fentiman I. Male breast cancer: a review. *Ecancermedicalscience*. 2009;3:140. doi:10.3332/ecancer.2009.140.
11. Giordano SH, Cohen DS, Buzdar AU, Perkins G, Hortobagyi G. Breast carcinoma in men: a population-based study. *Cancer*.

2004;101(1):51–7. doi:10.1002/cncr.20312.

## Author biography

**Sunil V. Jagtap**, Professor  <https://orcid.org/0000-0002-4844-7624>

**Shubham S. Jagtap**, Assistant Lecturer  <https://orcid.org/0000-0002-8304-8581>

**Harsh Machhi**, Assistant Lecturer  <https://orcid.org/0009-0004-0490-6325>

**Vaibhav Chavan**, Assistant Lecturer  <https://orcid.org/0009-0008-9184-5952>

**Manasi Bhade**, Assistant Lecturer  <https://orcid.org/0009-0001-8004-0971>

**Cite this article:** Jagtap SV, Jagtap SS, Machhi H, Chavan V, Bhade M. Male breast cancer: Clinicopathological characteristics. *IP J Diagn Pathol Oncol* 2023;8(3):168-171.