

Content available at: <https://www.ipinnovative.com/open-access-journals>

IP Journal of Diagnostic Pathology and Oncology

Journal homepage: <https://www.jdpo.org/>

Case Report

Oropharyngeal schwannoma- A relatively common entity at an uncommon site

Garima Rawat^{1,*}, Hema Malini Aiyer¹, Anshuman Kumar², Arun Kumar Sharma³

¹Dept. of Pathology, Dharamshila Narayana Superspeciality Hospital, New Delhi, India

²Dept. of Surgical Oncology, Dharamshila Narayana Superspeciality Hospital, New Delhi, India

³Dept. of Surgical Oncology, Shrimann Superspeciality Hospital, Jalandhar, Punjab, India



ARTICLE INFO

Article history:

Received 20-04-2023

Accepted 10-06-2023

Available online 22-06-2023

Keywords:

Neural

Schwannoma

Vallecula

ABSTRACT

Schwannomas are peripheral nerve sheath benign tumors which arise from the schwann cells. These neoplasms are most frequently seen in the 3rd to 6th decade of life and affecting the limbs followed by head and neck region. Oropharyngeal vallecular involvement by schwannomas is extremely rarely reported in the previous literature. We report a case of a 25 year old male with lesion in the vallecula which was subsequently diagnosed as Schwannomas on histopathology.

This is an Open Access (OA) journal, and articles are distributed under the terms of the [Creative Commons Attribution-NonCommercial-ShareAlike 4.0 License](https://creativecommons.org/licenses/by-nc-sa/4.0/), which allows others to remix, tweak, and build upon the work non-commercially, as long as appropriate credit is given and the new creations are licensed under the identical terms.

For reprints contact: reprint@ipinnovative.com

1. Introduction

Schwannomas are benign peripheral nerve sheath tumors that arise from differentiated schwann cells. They are not uncommon in the head and neck region but plausibly they are rarely reported consequently causing the scarcity of published literature. Schwannomas most commonly occur spontaneously in 90% cases and uncommonly can be seen associated with familial tumor syndromes like neurofibromatosis type 2 (NF2), schwannomatosis or Carney complex.^{1,2} We present a case of a 26 year old male which was diagnosed as a Schwannoma of vallecula of the oropharyngeal region.

2. Case Report

A 26 year old male presented to the out patient department with the chief complaint of difficulty in swallowing since some days. There was no other contributory medical history or deleterious habit history or family history. The patient was overall in a healthy state. The case was discussed

and planned for Direct laryngoscopy was performed which revealed a pedunculated well defined lesion attached to right Vallecula, the findings were suggestive of a benign lesion. Fine needle aspiration cytology was attempted but was not diagnostic so excision was planned. On Magnetic Resonance imaging (MRI), a soft tissue lesion was seen attached to the Vallecular surface with smooth and well defined outline. An informed consent was obtained and the patient was planned for excisional biopsy of the lesion. The excised specimen was submitted for histopathological examination. On gross examination it was single nodular soft tissue piece measuring 2.5x1.5x1 cm (Figure 1) with the cut surface showing grey white firm areas; the specimen was processed in toto. The microscopic sections showed a well circumscribed neural tumor with hypercellular (Antoni A) and hypocellular (Antoni B) areas (Figure 1A), palisaded Verocay bodies (Figure 1B-yellow arrow) and thick walled vessels with overlying squamous epithelium & lymphoid follicles. The Antoni A areas contain spindle cells with wavy nuclei (Figure 1C). The features were suggestive of Benign peripheral nerve sheath tumor- favoring Schwannoma. The patient has been under

* Corresponding author.

E-mail address: garima3103@gmail.com (G. Rawat).

follow since then and has reported no recurrence till date.

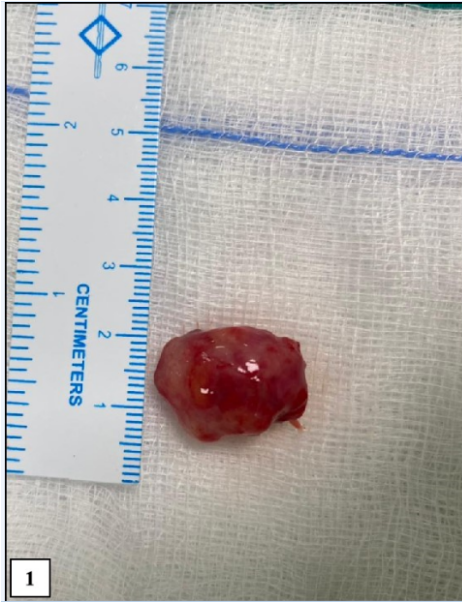

Fig. 1: Gross specimen showing single nodular soft tissue piece.

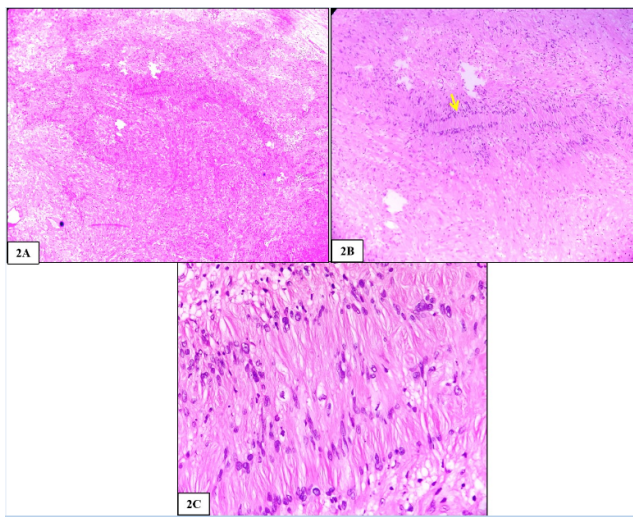


Fig. 2: Microscopy; **A:** Photomicrograph showing hypercellular antoni A and hypocellular antoni B areas. (HE 40x); **B:** Photomicrograph showing palisaded Verocay bodies. (HE 100x); **C:** Photomicrograph showing hypercellular antoni A with spindle wavy nuclei. (HE 400x)

3. Discussion

Schwannoma are benign encapsulated nerve sheath tumors composed entirely or nearly entirely of differentiated neoplastic Schwann cells. Head and neck region schwannomas account for upto 25 - 45% of all the extracranial schwannomas. In the head and neck region, commonly involved sites are floor of mouth and tongue,

however oropharyngeal region especially the vallecula has been infrequently reported. Patients are usually in the 4th to 6th decade of their life and lesions in the oropharynx present with difficulty or painful swallowing and occasionally with altered voice.^{1,3,4} Our patient on the contrary was in the also presented with the similar symptoms of dysphagia and odynophagia. The diagnostic aids for these lesions are radiology and histopathology being the gold standard. On microscopy the findings are characteristic with Antoni A areas containing spindle cells with wavy nuclei alternate with hypocellular Antoni B areas, which contain a myxoid matrix and variable lymphohistiocytic infiltrate. Within the Antoni A areas, parallel rows of nuclei (Verocay bodies) may be seen. Mitoses are rare. In the ancient schwannoma variant, degenerative nuclear atypia is noted which at times can be mistaken for aggressive lesion. Other rarer subtypes include plexiform, epithelioid, cellular, neuroblastoma-like and microcystic/reticular schwannoma.^{5,6} In the present case being discussed there were no degenerative changes and the microscopic picture was characteristic for a Schwannoma.

The treatment of choice is surgical excision which is associated with a good prognosis and no recurrence. Malignant transformation is thin on the ground.^{1,6} In our patient also surgical excision was performed under general anesthesia and the patient has been uneventful for last two years.

4. Clinical Significance

Schwannomas although common in the head and neck region are still sparse;y reported in the Vallecula of the oropharynx. With this article the probable occurrence of these neoplams in the oropharyngeal region is highlighted. Correct diagnosis and accurate treatment will help alleviate the symptoms and discomfort of the patients. Histopathological diagnosis is the gold standard and surgical excision of the lesion is the mainstay treatment.

5. Conflict of Interest

There are no conflicts of interest in this article.

6. Source of Funding

None.

7. Acknowledgements

We would like to acknowledge the efforts of the staff members of the laboratory and the operation theatre without whose cooperation this would not have been possible.

References

1. Sharma DK, Sohal BS, Parmar TL, Arora H. Schwannomas of head and neck and review of literature. *Indian J Otolaryngol Head Neck Surg.*

- 2012;64(2):177–80. doi:10.1007/s12070-011-0248-0.
2. Parvathidevi GK, Panduranga C, Munishwar GB. Ancient schwannoma of hypopharynx: a case report with review of literature. *Indian J Otolaryngol Head Neck Surg.* 2011;63(1):60–1. doi:10.1007/s12070-010-0068-7.
 3. Nemade HO, Jaiswal SA, Borade VR. Schwannoma of Oropharynx: A Rare Presentation. *Int J Otorhinolaryngol Clin.* 2013;5(2):14–6.
 4. Lahiri AK, Somashekar KK, Wittkop B, Ayshford C. Large Vallecular Masses; Differential Diagnosis and Imaging Features. *J Clin Imaging Sci.* 2018;8:26. doi:10.4103/jcis.JCIS_15_18.
 5. Zhumabayeva A, Hutinec Z, Bilic M. Hypopharyngeal schwannoma: A case report of a rare entity. *ENT Updates.* 2020;10(1):292–5. doi:10.32448/entupdates.616420.
 6. Ahmed AO, Umar AB, Aluko AA, Yaro MA. Hypopharyngeal schwannoma: A rare case presentation and review of literatures. *Niger J Basic Clin Sci.* 2013;10(1):29–32. doi:10.4103/0331-8540.117243.

Author biography

Garima Rawat, Junior Consultant  <https://orcid.org/0000-0001-6554-0444>

Hema Malini Aiyer, Head and Senior Consultant

Anshuman Kumar, Director and Clinical Lead

Arun Kumar Sharma, Consultant

Cite this article: Rawat G, Aiyer HM, Kumar A, Sharma AK. Oropharyngeal schwannoma- A relatively common entity at an uncommon site. *IP J Diagn Pathol Oncol* 2023;8(2):108-110.