

Content available at: <https://www.ipinnovative.com/open-access-journals>

IP Journal of Diagnostic Pathology and Oncology

Journal homepage: <https://www.jdpo.org/>

Case Report

Appendiceal collision tumor presented as acute appendicitis: A dissonant scenario

Sushma Prasanthi Nagireddi^{1,*}, Rashmi Shetty², Athira K P¹, Madhukar Devadiga¹,
Kuladeepa Ananda Vaidya¹

¹Dept. of Pathology, Srinivas institute of Medical Sciences and Research Centre, Mukka, Mangalore, Karnataka, India

²Dept. of Pathology, Kasturba Medical College, Manipal, Karnataka, India



ARTICLE INFO

Article history:

Received 29-04-2023

Accepted 02-06-2023

Available online 22-06-2023

Keywords:

Appendix

Low grade appendiceal mucinous neoplasm

Neuroendocrine tumours

Collision tumours

ABSTRACT

Neoplastic lesions of appendix occurs only in 1% of the appendectomy specimens. Its often an incidental finding. Collision tumours of appendix composed of a neuroendocrine tumor and low grade appendiceal mucinous neoplasm (LAMN) is a very rare event. We present here such a rare case. A 30 year old male presented clinically as acute appendicitis. But during the histopathological evaluation it was found to have a collision tumor of appendix. Low grade appendiceal mucinous neoplasm of appendix was detected at the tip of the appendix and well differentiated neuroendocrine tumor was detected at the base of the appendix. The diagnosis was further confirmed with immunohistochemistry. After the diagnosis a revised hemicolectomy with pelvic lymph node dissection was performed. No residual tumor or tumor deposits were identified. Since it's a rare condition an optimal treatment plan needs to be structured to avoid future morbidity.

This is an Open Access (OA) journal, and articles are distributed under the terms of the [Creative Commons Attribution-NonCommercial-ShareAlike 4.0 License](https://creativecommons.org/licenses/by-nc-sa/4.0/), which allows others to remix, tweak, and build upon the work non-commercially, as long as appropriate credit is given and the new creations are licensed under the identical terms.

For reprints contact: reprint@ipinnovative.com

1. Introduction

A collision tumour is the presence of two or more neoplasms with diverse histologic types that develop synchronously in one organ as a result of the simultaneous bi-clonal transformation of two separate cellular lines.¹

Primary tumours of the appendix make up about 0.4% of all gastrointestinal tract tumours and are typically discovered incidentally in about 1% of appendectomies. Collision tumours of appendix is incredibly uncommon entity.² Collision tumors composed of a carcinoid and low grade appendiceal mucinous neoplasm (LAMN) are very rare in the appendix. Here, we describe a case of collision tumor of the appendix due to its rarity.

2. Case Report

A 30 year old male presented with complaints of pain abdomen and vomiting for three days. Tenderness was elicited in the right iliac fossa and ultrasonography revealed a concealed appendicular perforation. Hence, with a clinical suspicion of acute appendicitis, appendectomy was performed. Intraoperatively appendix appears inflamed and caecum was pulled up.

Specimen was received for histopathological evaluation. Appendix measured 6cm in length. On cut section the tip of appendix appears dilated and was filled with mucin (Figure 1). The base shows a pale yellow lesion measuring 1x1 cm. Lumen appears to be obliterated at the base.

On histopathological evaluation, a collision tumor was detected in the appendix. A low grade appendiceal mucinous neoplasm was identified at the tip of the appendix. A filiform mucinous epithelial proliferation exhibiting low grade dysplastic changes was identified. (Figure 2)

* Corresponding author.

E-mail address: prasanthisn12@gmail.com (S. P. Nagireddi).

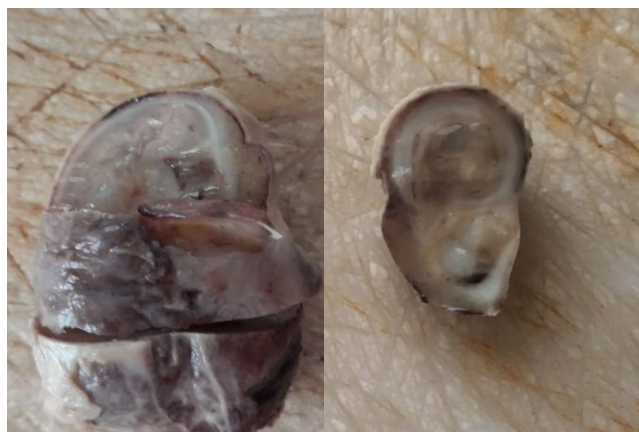

Fig. 1: Picture showing A. dilated appendix. 2. Dilated appendix filled with mucin.

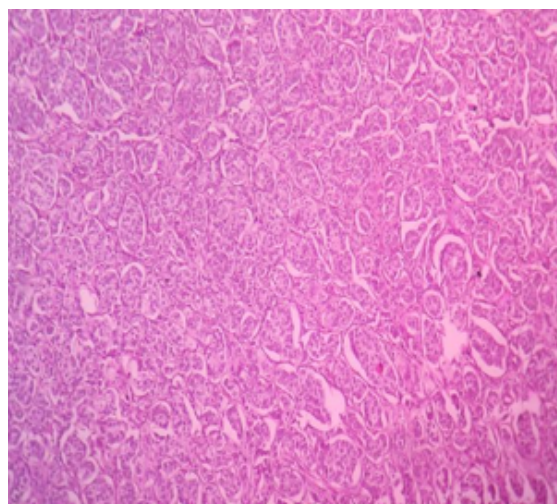


Fig. 4: Picture of Neuroendocrine tumour -Low power.

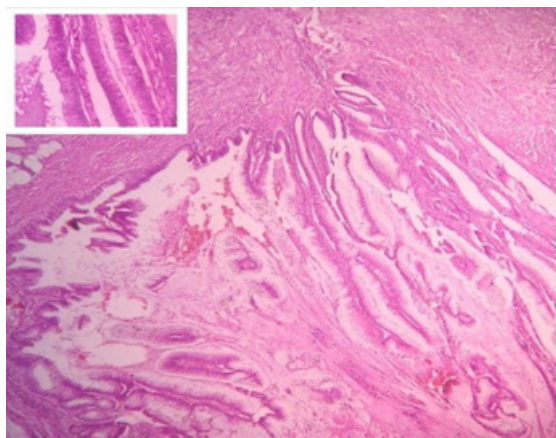


Fig. 2: Picture showing low grade appendiceal mucinous neoplasm. Inside picture showing mucinous epithelial proliferation exhibiting low grade dysplastic changes.

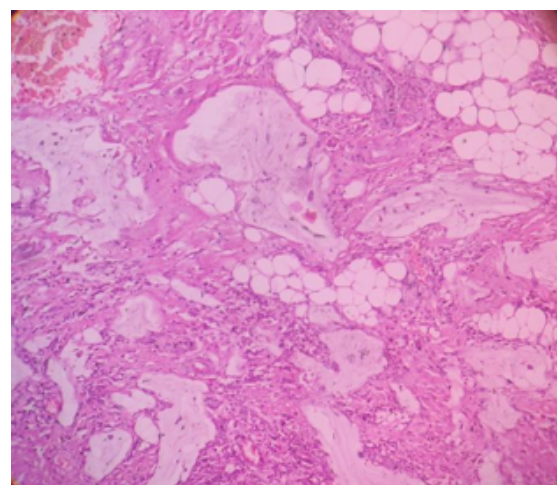


Fig. 5: Extracellular mucin was found to be dissecting the wall of appendix and reaching the subserosa.

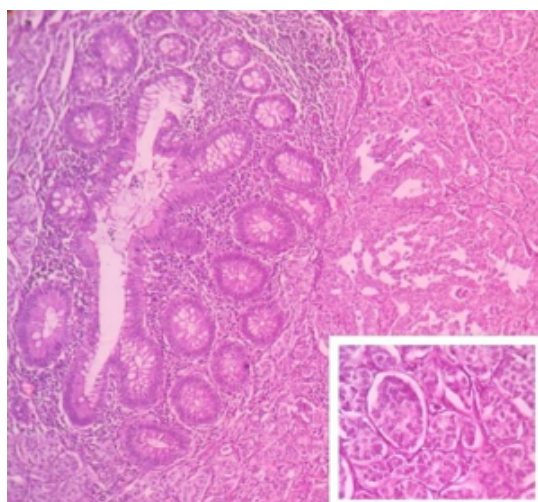


Fig. 3: Picture showing Neuroendocrine tumor arranged in sheets, nests.

Also extracellular mucin was found to be dissecting the wall of appendix and reaching the subserosa. (Figure 5)

A neuroendocrine neoplasm was found at the base of the appendix composed of tumor cells arranged in sheets, nests, clusters and trabecular pattern, predominantly involving the muscularis propria and subserosa (\$). Immunohistochemistry was done to confirm the neuroendocrine tumor(NET). Both synaptophysin and chromogranin was positive in the tumor. Ki67 proliferation index was 4%. Hence a well differentiated NET, grade 2 was confirmed.

Hence, a final diagnosis of combined low grade appendiceal mucinous neoplasm with extension to subserosa (pT3) and well differentiated neuroendocrine tumor, grade 2, involving subserosa (pT3) was given.

A revised hemicolectomy with pelvic lymph node dissection was performed. No residual tumor was identified and the lymph nodes were free of tumor deposits.

3. Discussion

Low grade appendiceal mucinous neoplasm (LAMN) represent up to 73% of mucinous epithelial neoplasms. They are usually non-invasive and have a good prognosis, although up to 18% of cases present with peritoneal mucinous deposits or pseudomyxoma peritonei. Their treatment depends on different neoplastic features such as the grade of their cellular atypia, nodal involvement, and peritoneal spread. In our case, there were no peritoneal mucinous deposits or pseudomyxoma peritonei. NETs comprise approximately 30-80% of all appendiceal tumors. Most of these neoplasms have an excellent prognosis, with a 5-year survival rate close to 100% in the lower tumor stages. Appendiceal NETs are usually detected incidentally during histological examination of appendectomy specimen. Collision tumor composed of both low-grade appendiceal mucinous neoplasia (LAMN) and appendiceal neuroendocrine tumor (ANET) is an extremely rare entity³ with only few cases reported in the literature. Review of literature by Villa M et al showed only 9 cases of collision LAMN and ANET, of these the patient age ranged between 23 and 60 years, and without any significant differences in sex.³

Different hypotheses have emerged to elucidate the pathogenesis of collision tumors, differentiation of two different cell types from a common progenitor cell is the most accepted theory. The prolonged exposure and stimulus from carcinogens in the mucosal layer affecting different regions of adjacent tissue and promoting the coexistence of two or more distinct neoplasms is the second theory. Since the appendix is a tubular structure with a blind end which would facilitate a prolonged exposure to retained intestinal carcinogens, the second theory could be more significant in case of appendix.^{1,4-6}

When both the epithelial tumor and neuroendocrine tumor are present in the same area without any transitional changes in the tumor cells, they are termed as 'collision' tumors. The designation of 'composite' tumor is reserved for those tumors exhibiting transition or intermediate cells between the two components.^{7,8} In the current case, microscopically, two components showed a clear-cut distinction, without any intervening intermediate cell population.

The most common clinical presentation of this condition is acute appendicitis caused by appendicular luminal obstruction by the neoplastic mass. A carcinoid syndrome is rarer and is caused by vasoactive peptides produced by appendiceal neuroendocrine tumors (ANETs), while mucocele and pseudomyxoma peritonei are a typical finding of mucinous neoplasms.⁹ In the current case, patient

presented with pain in the abdomen, ultrasound abdomen showed a mass in appendix, but there was no clear cut evidence of carcinoid syndrome or mucocele.

4. Conclusion

A collision tumour composed of low grade appendiceal mucinous neoplasm (LAMN) and NET of appendix is an extremely rare condition. It's often detected incidentally and patients do not receive adequate treatment at times. Hence, a standard treatment protocol needs to be structured to prevent future morbidity.

5. Conflict of Interest

There are no conflicts of interest in this article.

6. Source of Funding

None.

References

- Melendez AP, Chen X, Esquivel J. Collision Neoplasms of the Vermiform Appendix. *Open J Gastroenterology*. 2022;12(10):307–16.
- Baena-Del-Valle J, Palau-Lázaro M, Mejía-Arango M, Otero J, Londoño-Schimmer E, Cortes N, et al. Well differentiated neuroendocrine tumor of the appendix and low-grade appendiceal mucinous neoplasm presenting as a collision tumor. *Rev Esp Enferm Dig*. 2015;107(6):396–8.
- Villa M, Sforza D, Siragusa L, Guida AM, Manuelli MC, Pirozzi BM, et al. A low-grade appendiceal mucinous neoplasia and neuroendocrine appendiceal collision tumor: a case report and review of the literature. *Am J Case Rep*. 2021;22:e927876. doi:10.12659/AJCR.92787.
- Al-Balas H, Al-Saffar RS, Al-Balas M, Al-Wiswasy M, Al-Sharqi Y, Yousuf MS, et al. Unusual histopathological findings in appendectomy specimens with clinical diagnosis of acute appendicitis: A retrospective cohort analysis. *Ann Med Surg (Lond)*. 2021;69:102720. doi:10.1016/j.amsu.2021.102720.
- Michalinos A, Constantinidou A, Kontos M. Gastric Collision Tumors: An Insight into Their Origin and Clinical Significance. *Gastroenterol Res Pract*. 2015;p. 314158. doi:10.1155/2015/314158.
- Furlan D, Cerutti R, Genasetti A, Pelosi G, Uccella S, Rosa SL, et al. Microallelotyping defines the monoclonal or the polyclonal origin of mixed and collision endocrine-exocrine tumors of the gut. *Lab Invest*. 2003;83(7):963–71. doi:10.1097/01.lab.0000079006.91414.be.
- Singh NG, Mannan AA, Kahvie M, Nur AM. Mixed adenocarcinoma-carcinoid (collision tumor) of the appendix. *Med Princ Pract*. 2011;20(4):384–6. doi:10.1159/000324870.
- Lewin K. Carcinoid tumors and the mixed (composite) glandular-endocrine cell carcinomas. *Am J Surg Pathol*. 1987;11:71–86. doi:10.1097/0000478-198700111-00007.
- Gonzalez HH, Herard K, Mijares MC. A Rare Case of Low-grade Appendiceal Mucinous Neoplasm: A Case Report. *Cureus*. 2019;11(1):e3980. doi:10.7759/cureus.3980.

Author biography

Sushma Prasanthi Nagireddi, Post Graduate

Rashmi Shetty, Senior Resident

Athira K P, Assistant Professor

Madhukar Devadiga, Assistant Professor

Kuladeepa Ananda Vaidya, Professor

Cite this article: Nagireddi SP, Shetty R, Athira K P, Devadiga M, Vaidya KA. Appendiceal collision tumor presented as acute appendicitis: A dissonant scenario. *IP J Diagn Pathol Oncol* 2023;8(2):93-96.