

Content available at: <https://www.ipinnovative.com/open-access-journals>

IP Journal of Diagnostic Pathology and Oncology

Journal homepage: <https://www.jdpo.org/>

Case Report

Xanthogranulomatous cholecystitis - Mimicking carcinoma gall bladder

Jagannath Dev Sharma¹, Tarali Pathak^{1,*}, Anupam Sarma¹, Abhijit Talukdar², Amal C Katak³

¹Dept. of Oncopathology, Dr. B. Borooah Cancer Institute, Guwahati, Assam, India

²Dept. of Surical Oncology, Dr. B. Borooah Cancer Institute, Guwahati, Assam, India

³Director, Dr. B. Borooah Cancer Institute, Guwahati, Assam, India



ARTICLE INFO

Article history:

Received 03-04-2022

Accepted 22-04-2022

Available online 19-05-2022

Keywords:

Xanthogranulomatous cholecystitis

Carcinoma gall bladder

Foamy macrophages

ABSTRACT

Xanthogranulomatous cholecystitis (XGC)- a rare pathological entity of gall bladder, is characterized by marked inflammatory infiltrates of macrophages and foam cells with proliferative fibrosis of the gall bladder wall. Although it is a benign condition, its radiological picture and intra operative findings mimic gall bladder carcinoma- leading to misdiagnosis in most cases. We report a case of XGC in a middle-aged lady who presented with a lump in right hypochondrium. Computed Tomography (CT) scans of the abdomen was inconclusive for her. A CT-guided Fine Needle Aspiration Cytology (FNAC) was obtained, where findings were suggestive of XGC which was finally confirmed on histopathological examination of the cholecystectomy specimen. The characteristic cytologic features of XGC on FNAC in this case helped differentiate it from malignancy, thereby sparing the patient a morbid radical surgery. Preoperative FNAC and intraoperative frozen section are valuable tools for differential diagnosis of XGC and help guide the surgeon towards a correct surgical approach.

This is an Open Access (OA) journal, and articles are distributed under the terms of the [Creative Commons Attribution-NonCommercial-ShareAlike 4.0 License](https://creativecommons.org/licenses/by-nc-sa/4.0/), which allows others to remix, tweak, and build upon the work non-commercially, as long as appropriate credit is given and the new creations are licensed under the identical terms.

For reprints contact: reprint@ipinnovative.com

1. Introduction

Xanthogranulomatous cholecystitis (XGC) is a benign lesion of the gall bladder. This rarely encountered histological entity is an inflammatory condition that shows presence of macrophages and foam cells with extensive proliferative fibrosis of the gall bladder wall.^{1,2} Pre-operative radiological findings and even intraoperative findings in XGC may be indistinguishable from that of Gall Bladder Carcinoma (GBC), often leading to erroneous diagnosis.³⁻⁵ A simple cholecystectomy is often sufficient to treat XGC, while surgery for GBC entails a far extensive and morbid radical cholecystectomy with lymph node sampling. Conclusively differentiating XGC from GBC by radiological investigations such as Ultrasonography (USG),

Computed Tomography (CT) and Magnetic Resonance Imaging (MRI) is often challenging. Hence, pre-operative FNAC can be a helpful aid in differentiating these two conditions, thereby guiding the surgeons in making decisions to limit the extent of surgical procedure from radical to simple cholecystectomy and help reduce patient morbidity.⁶

2. Case History

We report the case history of a 40-year-old lady who presented with complaints of pain abdomen with associated loss of appetite and weight loss for a duration of two months. On clinical evaluation, a palpable non-tender lump was noted in the right hypochondrium that was inseparable from the liver. Ultrasonography showed mass in the fundus of the gall bladder that was likely infiltrating the liver. The gall

* Corresponding author.

E-mail address: tarali8pathak@gmail.com (T. Pathak).

bladder wall was thickened and cholecystitis was also noted. A contrast enhanced CT (CECT) was advised that also showed a thick-walled gall bladder with band formation, intraluminal mass effect and infiltration of peri-cholecystic tissue and liver. No lymphadenopathy was detected but the final impression of CECT report suggested that GBC could not be ruled out for the case (Figure 1). Blood investigations revealed a mildly elevated serum CA 19.9 (42 u/ml) with normal haematological parameters, kidney and liver functions. To obtain a clearer picture of diagnosis, we performed a CT guided FNAC of the gall bladder mass. It showed presence of inflammatory cells, granulation tissue, multinucleated giant cells and foamy macrophages with pigment formation in few foam cells, suggesting a likely diagnosis of XGC (Figure 2). The surgeon went ahead with performing a Open cholecystectomy and intraoperatively a gall bladder, densely adherent to the liver bed was noted and subsequently removed. Grossly, the surgical specimen showed a gall bladder with thickened walls and yellowish irregular, infiltrative nodular lesions over its wall and surface with a single impacted stone in the lumen (Figure 3). On microscopic examination, a hypertrophic fibromuscular layer was noted with presence of polymorphic cellular infiltrates comprising pigment laden foamy histiocytes, giant cells, lymphocytes and fibroblasts. The infiltrates involved the full thickness of gall bladder wall extending into the pericholecystic fatty tissue, although no evidence of malignancy was seen. These features were suggestive of a final histopathologic diagnosis of XGC (Figures 4 and 5). The patient had an uneventful post operative recovery and a satisfactory follow-up thereafter.

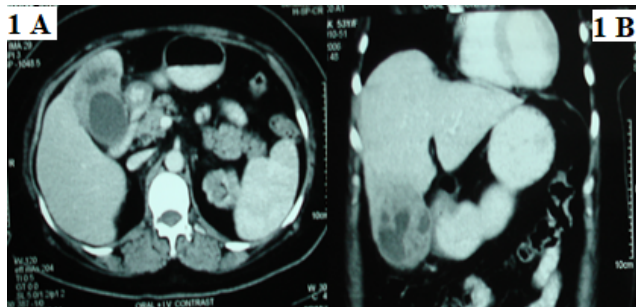


Fig. 1: Computed Tomography (A: Axial, B: Coronal) images showing thick walled GB with band, intraluminal mass effect and infiltration of pericholecystic tissue and liver.

3. Discussion

The pathologic diagnosis of XGC was first made by Christensen and Ishak, who described pseudotumors of gall bladder in seven patients.⁷ This condition has been previously described in literature by various nomenclatures such as ceroid granulomas, ceroid like histiocytosis and fibroxanthogranulomatous inflammation, but the term

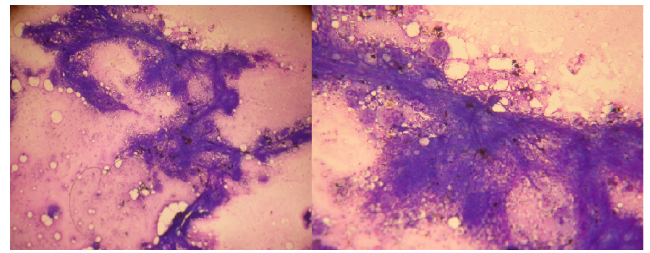


Fig. 2: Micrographic images of FNAC showing foam cell, multinucleated giant cell, pigments in foam cell and inflammatory cells scattered among numerous red blood cells.

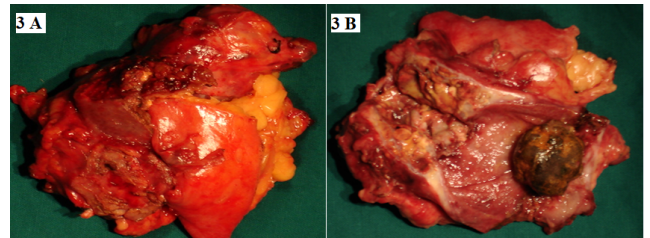


Fig. 3: Gross specimen of gall bladder. A: With adherent fatty tissue and liver. B: Cut section showing thickened wall, impacted stone, yellowish irregular infiltrative nodular lesion in wall and on surface.

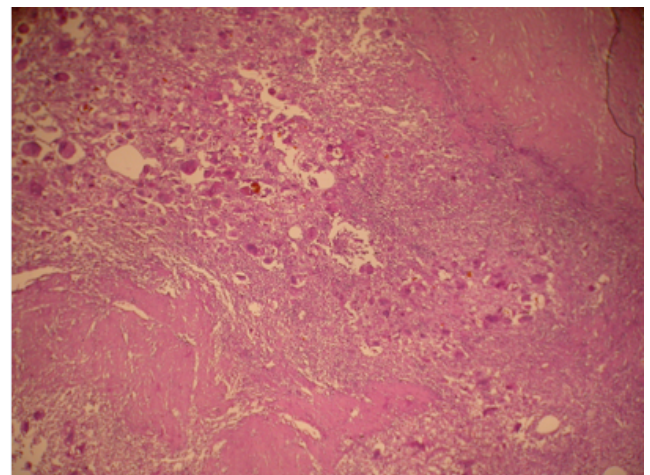


Fig. 4: Photomicrograph (H&E, 400X) showing giant cells and foamy macrophages in muscle wall.

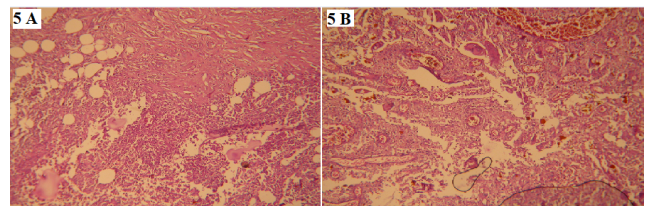


Fig. 5: Photomicrographs (H&E, 400X) showing serosal involvement A; and granulation tissue with giant cells B.

Xanthogranulomatous cholecystitis (XGC) was first coined by the Armed Forces Institute of Pathology.^{7–11}

XGC is a very rare condition and the reported incidence in literature ranges from 0.66–1.8%. It is even rarer to be diagnosed preoperatively and patients are frequently misdiagnosed as having cholelithiasis or carcinoma. There is no sex predilection of XGC with equal incidence in both men and women.¹¹ Gall stones are invariably seen to coexist with XGC (91–100%).¹¹

Although initially thought to be a malignancy, XGC mimics the natural history and characteristics of xanthogranulomatous pyelonephritis (XGP), a benign disorder.^{12,13} Both XGC and XGP are triggered by chronic infection and calculi thereby recruiting histiocytes to initiate the inflammatory cascade and the resultant histopathology.^{12–14} Gallbladder calculi is thought to produce a mechanical trauma to the mucosa thereby initiating the inflammatory response. This inflammation causes a chemical reaction of lecithin and free fatty acids in bile, which produces lysolecithin and causes further damage to the gallbladder mucosa, resulting in a vicious cycle of destructive changes.^{9,15} The progression from cholecystitis to XGC happens when the Rokitsky-Aschoff sinuses in the gall bladder wall get inspissated with bile and mucin and finally become occluded.^{9,15} As the tension in the wall of the gallbladder increases due to distension, the Rokitsky-Aschoff sinuses rupture and the inflammatory process spreads to the adjacent tissues.^{8,10} The phagocytosis of the degraded, insoluble cholesterol crystals and bile salts by histiocytes, results in the appearance of macrophage-laden and foamy histiocytes- the characteristic finding of XGC.^{8–15}

XGC is often radiologically confused with gall bladder carcinoma. Ultrasonography often reports focal or diffuse thickening of the hyperechoic gallbladder wall and presence of characteristic intraluminal hypoechoic nodules in a case of XGC, but these are nonspecific findings.^{16,17} Other conventional radiological methods like CT scan and MRI also lack sensitivity and specificity towards diagnosis of XGC.¹⁷

FNAC, to some extent can differentiate adenocarcinoma, XGC and other coexistent pathologies. Thus, pre-operative FNAC can help in determining the urgent need of treatment and also the surgical procedure in lesions of gall bladder suspicious for XGC.¹⁸

Lastly, there are no specific biochemical or haematological parameters that aid in the diagnosis of XGC. CA 19.9 also fails to provide any definite clue towards diagnosis as exhibited in our patient. The slightly elevated value (42 U/mL) of CA 19.9 in our case, persisted even after jaundice was resolved through placement of an endoscopic stent preoperatively.

4. Conclusion

The differential diagnosis of XGC from gallbladder carcinoma remains a challenge, especially in cases where extensive pseudotumoral involvement of surrounding structures are noted on preoperative imaging or intraoperatively. Radical resection remains the treatment of choice when malignancy cannot be ruled out even after comprehensive preoperative diagnostic evaluation. Preoperative fine needle aspiration cytology and intraoperative frozen section are valuable tools in this regard, which have the scope to accurately guide the extent of surgical resection- thereby limiting patient's morbidity from a radical cholecystectomy.

5. Conflict of Interest

The authors declare no relevant conflicts of interest.

6. Source of Funding

None.

References

- Hale MD, Roberts KJ, Hodson J, Scott N, Sheridan M, Toogood GJ, et al. Xanthogranulomatous cholecystitis: a European and global perspective. *HPB (Oxford)*. 2014;16(5):448–58. doi:10.1111/hpb.12152.
- Kwon AH, Matsui Y, Uemura Y. Surgical procedures and histopathologic findings for patients with xanthogranulomatous cholecystitis. *J Am Coll Surg*. 2004;199(2):204–10. doi:10.1016/j.jamcollsurg.2004.03.018.
- Spinelli A, Schumacher G, Pascher A. Extended surgical resection for xanthogranulomatous cholecystitis mimicking advanced gallbladder carcinoma: a case report and review of literature. *World J Gastroenterol*. 2006;12(14):2293–6.
- Yang T, Zhang BH, Zhang J, Zhang YJ, Jiang XQ, Wu MC, et al. Surgical treatment of xanthogranulomatous cholecystitis: experience in 33 cases. *Hepatobiliary Pancreat Dis Int*. 2007;6(5):504–8.
- Sharma D, Babu R, Sood G, Kapoor G, Solanki RS, Thomas S. Xanthogranulomatous cholecystitis masquerading as malignancy with liver metastasis. *ANZ J Surg*. 2009;79(12):946–7.
- Singh S, Walia DS, Sharma A. Xanthogranulomatous cholecystitis: presenting as gall bladder mass. *J Evolution Med Dent Sci*. 2016;5(29):1504–5.
- Christensen AH, Ishak KG. Benign tumors and pseudotumors of the gallbladder. *Arch Pathol*. 1970;90(5):423–32.
- Reed A, Ryan C, Schwartz S. Xanthogranulomatous cholecystitis. *J Am Col Surg*. 1994;179:249–52.
- Dao AH, Wong SW, Adkins RB. Xanthogranulomatous cholecystitis: A clinical and pathologic study of twelve cases. *Amer Surg*. 1989;55(1):32–5.
- Mccooy JJ, Vila R, Petrossian G, McCall RA, Reddy KS. Xanthogranulomatous cholecystitis; Report of two cases. *J SC Med Assoc*. 1976;72(3):78–9.
- Houston JP, Collins MC, Reed MW. Xanthogranulomatous cholecystitis. *Br J Surg*. 1994;81(7):1030–2. doi:10.1002/bjs.1800810735.
- Povýsil C, Koníčková L. Experimental xanthogranulomatous pyelonephritis. *Invest Urol*. 1972;9(4):313–8.
- Malek RS, Elder JS. Xanthogranulomatous pyelonephritis: A critical analysis of 26 cases and of the literature. *J Urol*. 1978;119(5):589–93.
- Howard TJ, Bennion RS, Thompson JE. Xanthogranulomatous cholecystitis: A chronic inflammatory pseudotumor of the gallbladder. *Am Surg*. 1991;57(12):821–4.

15. Goodman ZD, Ishak KG. Xanthogranulomatous cholecystitis. *Am J Surg Pathol.* 1981;5(5):653–9. doi:10.1097/00000478-198110000-00007.
16. Muguruma N, Okamura S, Okahisa T, Shibata H, Ito S, Yagi K, et al. Endoscopic sonography in the diagnosis of xanthogranulomatous cholecystitis. *J Clin Ultrasound.* 1999;27(6):347–50. doi:10.1002/(sici)1097-0096(199907/08)27:6<347::aid-jcu7>3.0.co;2-l.
17. Parra JA, Acinas O, Bueno J, Guezmes A, Fernandez MA, Farinas MC, et al. Xanthogranulomatous cholecystitis: clinical, sonographic, and CT findings in 26 patients. *Am J Roentgenol.* 2000;174(4):979–83. doi:10.2214/ajr.174.4.1740979.
18. Krishnani N, Shukla S, Jain M, Pandey R, Gupta RK. Fine needle aspiration cytology in xanthogranulomatous cholecystitis, gallbladder adenocarcinoma and coexistent lesions. *Acta Cytol.* 2000;44(4):508–14. doi:10.1159/000328522.

Author biography

Jagannath Dev Sharma, Ex-Professor and HOD

Tarali Pathak, Ex-Senior Resident

Anupam Sarma, Professor and HOD

Abhijit Talukdar, Professor

Amal C Kataki, Director

Cite this article: Sharma JD, Pathak T, Sarma A, Talukdar A, Katak AC. Xanthogranulomatous cholecystitis - Mimicking carcinoma gall bladder. *IP J Diagn Pathol Oncol* 2022;7(2):133-136.