

Content available at: <https://www.ipinnovative.com/open-access-journals>

IP Journal of Diagnostic Pathology and Oncology

Journal homepage: <https://www.jdpo.org/>

## Case Report

# Diagnosis of odontogenic keratocyst on fine needle aspiration cytology: A case report

Kirtijit Chakma<sup>1,\*</sup>, Darlin M Shangpliang<sup>1</sup>

<sup>1</sup>Dept. of Pathology, Nazareth Hospital, Shillong, Meghalaya, India



### ARTICLE INFO

#### Article history:

Received 23-04-2022

Accepted 25-04-2022

Available online 19-05-2022

#### Keywords:

Odontogenic keratocyst

OKC

FNAC

### ABSTRACT

Odontogenic keratocyst (OKC) is an intraosseous odontogenic cyst which present as a painless swelling. We report a case of 22 years old male presenting as painless swelling over mandible since 1 years which is gradually progressive. There was no history of fever, tooth extraction, trauma or any addiction. Cytomorphology was consistent with Odontogenic keratocyst. Histomorphology was consistent with Odontogenic keratocyst. FNAC is an important preoperative diagnostic tool which is quick and safe. We suggest for routine FNAC for the intraosseous jaw lesion along with radiological and histopathological investigation.

This is an Open Access (OA) journal, and articles are distributed under the terms of the [Creative Commons Attribution-NonCommercial-ShareAlike 4.0 License](https://creativecommons.org/licenses/by-nc-sa/4.0/), which allows others to remix, tweak, and build upon the work non-commercially, as long as appropriate credit is given and the new creations are licensed under the identical terms.

For reprints contact: [reprint@ipinnovative.com](mailto:reprint@ipinnovative.com)

## 1. Introduction

Odontogenic keratocyst (OKC) is an intraosseous odontogenic cyst which present as a painless swelling. It can be seen at any age with two peaks, the first during the second to third and the second during the sixth to seventh decades of life.<sup>1,2</sup> OKCs are usually incidentally discovered during routine dental radiographic examinations, frequently appearing as well demarcated unilocular radiolucent lesions, with thin well defined and sclerotic margins. Reports about the use of FNAC in the diagnosis of odontogenic keratocysts are infrequent. We report a case of 20-year-old male with swelling over mandible as Odontogenic keratocyst on FNAC.

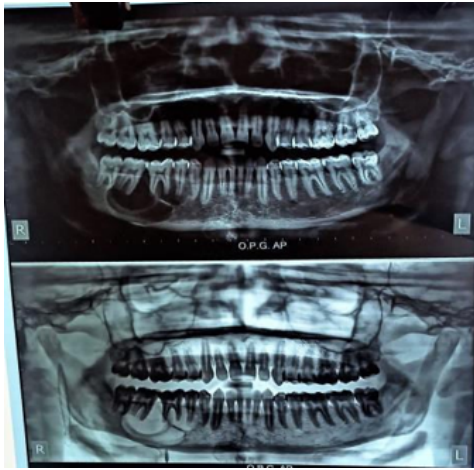## 2. Case

We report a case of 22 years old male presenting as painless swelling over mandible since 1 year which is gradually progressive. There was no history of fever, tooth

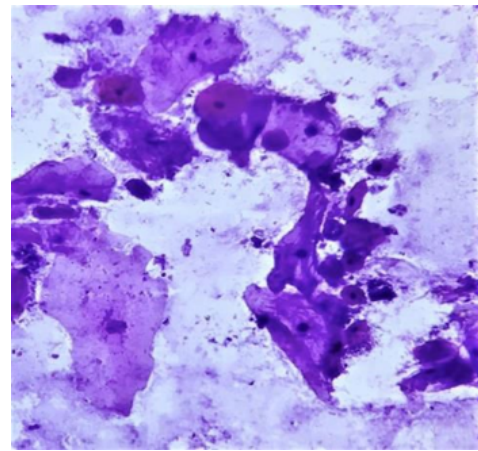
extraction, trauma or any addiction. On orthopantomogram (OPG) and Cone beam CT scan (CBCT) of face, a well-defined, unilocular, radiolucent lesion in the right mandible posterior region is seen (Figures 1 and 2). On clinical examination, a hard swelling was palpated over right side of mandible which was non-tender and non-mobile. Overlying skin and temperature was unremarkable. On FNA, white cheesy material was aspirated. FNA smears showed plenty of squamous cells with benign nucleus and abundant eosinophilic cytoplasm. Keratinous debris, mild inflammation and multinucleated giant cells were also against dirty background. Cytomorphology is consistent with Odontogenic keratocyst (Figures 3, 4 and 5). It was later operated and sent for histopathological examination. Grossly, cyst was received in multiple pieces which were predominantly white soft and fragile mass. On microscopy, sections showed cyst lined by thickened uniform epithelial lining with luminal surface having wavy parakeratotic epithelial cells. The lumen of the cyst is seen filled with keratin debris (Figure 6). There was no evidence of granuloma or any cellular atypia. Histomorphology was consistent with Odontogenic keratocyst.

\* Corresponding author.

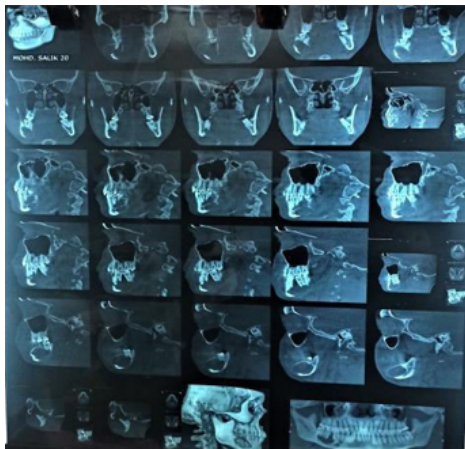
E-mail address: [kirtymster@gmail.com](mailto:kirtymster@gmail.com) (K. Chakma).



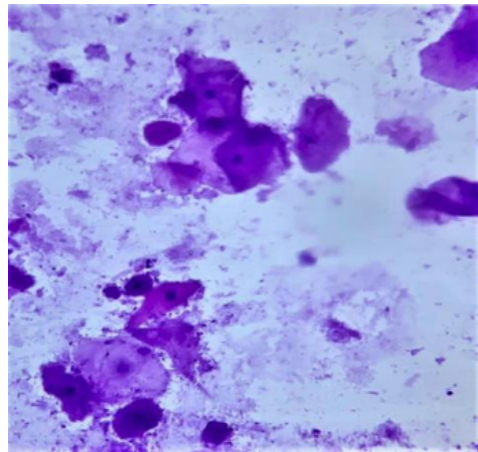
**Fig. 1:** OPG show a well defined unilocular radiolucency with smooth corticated border in the right mandible posterior region



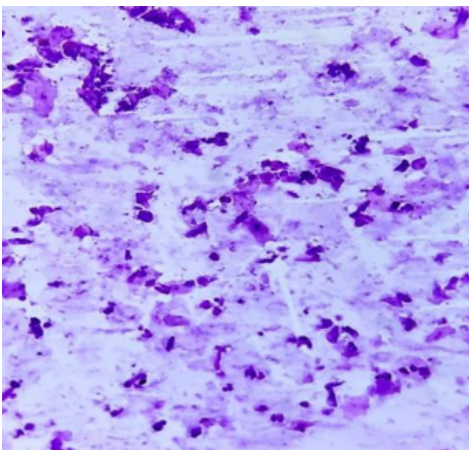
**Fig. 4:** FNAC smear show benign nucleated squamous cells with abundant eosinophilic cytoplasm (40x)



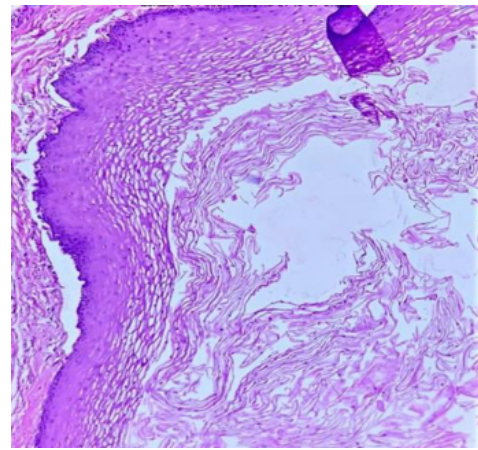
**Fig. 2:** CBCT scan reveals single unilateral, multilocular, well defined radiolucency surrounded by well cortical border in the right mandible posterior region



**Fig. 5:** FNAC smear show benign squamous cells having small hyperchromatic nuclei and abundant eosinophilic cytoplasm against dirty background (20x)



**Fig. 3:** FNAC smear show benign squamous nucleated and anucleated cells along with keratin debris against dirty background (10x)



**Fig. 6:** Section showing partially uniform corrugated parakeratinized epithelial lining and lumen filled with keratin debris (10x)

### 3. Discussion

OKC is an odontogenic cyst with a locally destructive behaviour that most frequently affects male patients during the second to third and sixth to seventh decades of life.<sup>1,2</sup> Most common site of presentation of OKC over mandible is in the posterior region.<sup>2–4</sup> Leandro Santos R et al reported a case of 26 year old man with painless swelling over the left mandibular posterior region consistent with diagnosis of Odontogenic keratocyst.<sup>5</sup> FNAC in the lesion over head and neck is frequently done usually soft tissue lesion but not for bony lesion. FNAC plays an important role in intraosseous jaw lesions in differentiating between benign and malignant lesion. Goyal S et al reported 42 cases aimed at studying the role of FNAC in the diagnosis of intraosseous lesions of jaw and came in to conclusion with 94.7% sensitivity and 100% specificity with a diagnostic accuracy of 97.3%.<sup>6</sup> Key histologic criteria keratocystic odontogenic tumor includes a squamous lined cyst with a palisaded basal layer, parakeratosis, keratin production and corrugated surface. This specific combination of findings is never found in dentigerous cysts, ameloblastomas or radicular cysts.<sup>7</sup>

Conclusion: FNAC is an important preoperative diagnostic tool which is quick and safe. It also help in differentiating the benign and malignant lesions. It also add to take decision for type of surgery to be done if needed. It also helps the management of the patient at the earliest. So we suggest for routine FNAC for the intraosseous jaw lesion along with radiological and histopathological investigation.

### 4. Source of Funding

None

### 5. Conflicts of Interest

None

### References

1. Barnes L, Eveson JW, Reichart P, Sidransky D. World Health Organization Classification of Tumours. Pathology & Genetics Head and Neck Tumors, 1st edn. Lyon, France: IARC Press; 2005.
2. Jones AV, Craig GT, Franklin CD. The range and demographics of odontogenic cysts in a UK population. *J Oral Pathol Med.* 2006;35(8):500–7. doi:10.1111/j.1600-0714.2006.00455.x.
3. Maurette PE, Jorge J, Moraes M. Conservative treatment protocol of odontogenic keratocyst: a preliminary study. *J Oral Maxillofac Surg.* 2006;64(3):379–83. doi:10.1016/j.joms.2005.11.007.
4. Kricbergs A, Bauer HC, Brosjo O. Cytological diagnosis of bone tumours. *J Bone Joint Surg Br.* 1996;78(2):258–63.
5. Santos RL, Ramos-Perez F, Silva GKA, Rocha AC, Prado JD, Perez DEC, et al. Odontogenic keratocyst: The role of the orthodontist in the diagnosis of initial lesions. *Am J Orthod Dentofacial Orthop.* 2017;152(4):553–6. doi:10.1016/j.ajodo.2017.06.013.
6. Goyal S, Sharma S, Kotru M, Gupta N. Role of FNAC in the diagnosis of intraosseous jaw lesions. *Med Oral Patol Oral Cir Bucal.* 2015;20(3):e284–91.
7. Robinson R. Diagnosing the most common odontogenic cystic and osseous lesions of the jaws for the practicing pathologist. *Mod Pathol.* 2017;30(S1):96–103. doi:10.1038/modpathol.2016.191.

### Author biography

**Kirtijit Chakma**, Junior Consultant  <https://orcid.org/0000-0002-7246-0722>

**Darlin M Shangpliang**, Consultant  <https://orcid.org/0000-0002-8679-3720>

**Cite this article:** Chakma K, Shangpliang DM. Diagnosis of odontogenic keratocyst on fine needle aspiration cytology: A case report. *IP J Diagn Pathol Oncol* 2022;7(2):119-121.