

Content available at: <https://www.ipinnovative.com/open-access-journals>

IP Journal of Diagnostic Pathology and Oncology

Journal homepage: <https://www.jdpo.org/>

Letter to Editor

Adenolipoma of breast - Letter to editor

Sumita Tripathy¹, Swetambari Acharya¹, Chaitali Pattnaik¹, Shushruta Mohanty^{1,*}

¹Dept of Pathology, M.K.C.G Medical College, Berhampur, Odisha, India



ARTICLE INFO

Article history:

Received 10-01-2022

Accepted 21-01-2022

Available online 28-02-2022

This is an Open Access (OA) journal, and articles are distributed under the terms of the [Creative Commons Attribution-NonCommercial-ShareAlike 4.0 License](#), which allows others to remix, tweak, and build upon the work non-commercially, as long as appropriate credit is given and the new creations are licensed under the identical terms.

For reprints contact: reprint@ipinnovative.com

Dear Sir,

Adenolipoma of breast is an rare hamartomatous lesion with a variable growth pattern.¹ The exact incidence is still unknown but it can be detected accurately in radiological investigations like mammograms in upto 0.16%² and later confirmed histopathologically. In order to be aware of this rare entity and to avoid incorrect diagnosis that might lead to unnecessary surgery, prompted us to report.

A 30yr female presented to surgery OPD with a mobile tender lump of size 4 x2 cm approx in the upper inner quadrant of the right breast. The swelling was progressive in size since a month. There was no change in the breast skin or any nipple retraction. There was no such lump in the left breast or any enlarged lymphnodes in bilateral axilla. The patient was then referred for fine needle aspiration cytology to our department. FNAC done revealed small duct epithelial cells in clusters and mature adipocytes over a fatty background, corroborating the clinical finding, the diagnosis was suggestive of non-proliferative benign breast disease, possibly fibroadenoma. However there was no typical arrangement of duct epithelial cells in staghorn pattern, or stromal fragments as seen in the typical fibroadenoma on cytology, so excisional biopsy was suggested. There were no history of other medical disease in the patient. All other routine investigations were apparently normal. The patient underwent a subcutaneous

lumpectomy and the specimen was send to our dept for histopathological examination. Grossly it was a globular grayish white encapsulated mass measuring 5x3x2 cm with a smooth external surface, which on cutsection was solid, homogenous and yellowish (Figure 1a-b). Histosection shows disorganised arrangement of ducts and lobules. There is predominantly acini of lobules and paucity of ducts intermingled with mature fat tissue in a hamartomatous pattern embedded in a fibroconnective tissue stroma (Figure 2a-d). Thus a histopathological diagnosis of adenolipoma was rendered.

The term adenolipoma was first suggested by Spalding in the year 1945. It is an uncommon lesion with various synonyms like fibroadenolipoma, hamartoma or post lactational tumours.³ It is usually regarded as a hamartomatous lesion consisting of disorganised collection of mammary tissues including duct and lobules, fat and fibrous tissue as well as smooth muscles admixed in varying proportions. Other rare variants of hamartoma are adenohibernoma, myoid hamartoma and chondrolipoma. Our case was devoid of smooth muscle and cartilage tissue that is seen in myoid hamartoma and chondrolipoma.

Adenolipoma usually presents as a soft mobile well defined mass and is often misdiagnosed as other benign tumours. The typical mammographic finding of adenolipoma is a well circumscribed lesion containing both fat and soft tissue surrounded by a capsule.^{4,5} Microscopically composed of variable mixture of ducts and lobules admixed with fat in varying proportion, however

* Corresponding author.

E-mail address: sushruta.mohanty@gmail.com (S. Mohanty).




Fig. 1: a-b: Gross Pic - Globular grayish white encapsulated mass measuring 5x3x2cm with a smooth external surface, C/s was solid, homogenous and yellowish

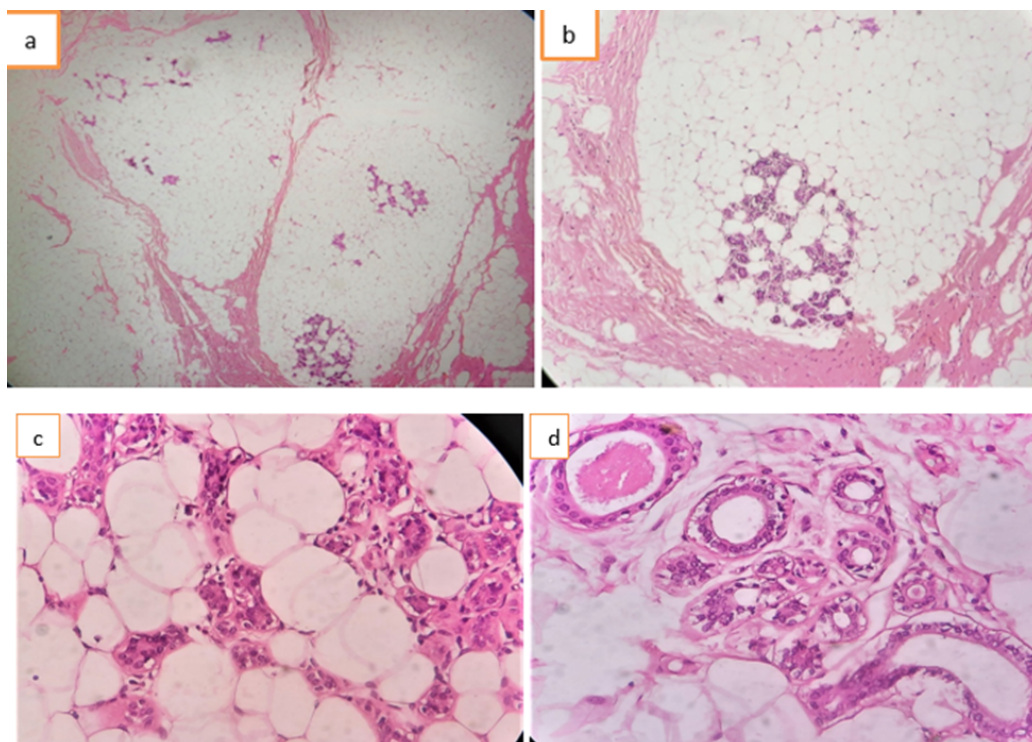


Fig. 2: a: Scanner view 40x:-Clusters of lobules with paucity of ducts embedded in fibrofatty connective tissue stroma; **b:** low power 100x; **c-d:** High power 400x- showing lobules embedded in fibrofatty stroma.

lobules are more numerous than ducts and do not seem to cluster around ducts. Majority of the lesion is composed of fat that is around 5 to 90%.⁶ Four different patterns of hamartoma have been known to be reported in a study conducted by Jones et al after analysis of 17 cases of breast hamartomas: 1) circumscribed fibrocystic changes with fat, smooth muscle or collagen, 2) Fibroadenoma with fat or cartilage 3) fibroadenoma with lobules 4) adenolipoma.⁷ Other associations known to have been reported with this entity includes fibrocystic changes, sclerosing adenosis and pseudoangiomatous stromal hyperplasia.^{6,8} Certain secondary tumours are known to occur in adenolipoma

.Few authors have reported simultaneous coexistence of fibroadenoma with adenolipoma in 12 % patients,⁵ Harigopal et al reported two cases of fibroadenoma arising from adenolipoma.⁹ Neoplastic changes though rare in adenolipoma, one should always exclude a possibility of such transformation. Pervatkar et al reported invasive ductal carcinoma in a mammary hamartoma in a 25 year old.¹⁰

The histopathological differential diagnosis of adenolipoma includes fibroadenoma and phylloides tumour. Presence of lobular structure and its disorganised arrangement clearly distinguishes adenolipoma from

fibroadenoma. On the other hand phylloides tumour is more cellular in comparison to adenolipoma, and cleft like epithelium lined spaces are not seen in adenolipoma.²

The correct diagnosis of adenolipoma is dependent on radiological and histopathological examination. Hamartomas are benign but are prone for recurrences as being noted in 8 % of patients.¹¹ Enucleation is the standard treatment of patients with adenolipoma.^{1,2,6,12}

Conflict of Interest

The authors declare that there is no conflict of interest.

Source of Funding

None.

References

1. Yasuda S, Kubota M, Noto T. Two cases of adenolipoma of the breast. *Tokai J Exp Clin Med.* 1992;17(3-4):139–44.
2. Hanby AM, Walker C, Tavassoli FA, Devilee P. Pathology and Genetics: Tumours of the Breast and Female Genital Organs. WHO Classification of Tumours series - volume IV. *Breast Cancer Res.* 2004;6(133). doi:10.1186/bcr788.
3. Spalding JE. Adenolipoma and lipoma of the breast. *Guy's Hosp Rep.* 1945; 94: 80-2n: IRCA press. IRCA press; 2003.
4. Brebner DM, Cosmann B, Shapiro J. Lipoma of the breast diagnosed by film and xeromammography. *S Afr Med J.* 1976;50(18):685–8.
5. Wahner-Roedler DL, Sebo TJ, Gisvold JJ. Hamartomas of the breast: clinical, radiologic, and pathologic manifestations. *Breast J.* 2001;7(2):101–5.
6. Tse GM, Law BK, Ma TK. Hamartoma of the breast: a clinicopathological review. *J Clin Pathol.* 2002;55(12):951–4.
7. Jones MW, Norris HJ, Wargotz ES. Hamartomas of the breast. *Surg Gynecol Obstet.* 1991;173(1):54–6.
8. Fisher CJ, Hanby AM, Robinson L, Millis RR. Mammary hamartoma—a review of 35 cases. *Histopathology.* 1992;20(2):99–106.
9. Harigopal M, Mudrovich SA, Hoda SA, Rosen PP. Secondary tumors in mammary adenolipomas: a report of 2 unusual cases. *Arch Pathol Lab Med.* 2003;127(3):e151–4.
10. Pervatkar SK, Rao R, Dinesh US, Parameswaraiiah S. Large mammary hamartoma with focal invasive ductal carcinoma. *Indian J Pathol Microbiol.* 2009;52(2):249–51.
11. Daya D, Trus T, D'Souza TJ, Minuk T, Yemen B. Hamartoma of the breast, an underrecognized breast lesion. A clinicopathologic and radiographic study of 25 cases. *Am J Clin Pathol.* 1995;103(6):685–9.
12. Sonmez FC, Guzin Z, Yildiz P, Tosuner Z. Hamartoma of the breast in two patients: A case report. *Oncol Lett.* 2013;6(2):442–4.

Author biography

Sumita Tripathy, Assistant Professor

Swetambari Acharya, Post Graduate

Chaitali Pattnaik, Post Graduate

Shushruta Mohanty, Assistant Professor

Cite this article: Tripathy S, Acharya S, Pattnaik C, Mohanty S. Adenolipoma of breast - Letter to editor. *IP J Diagn Pathol Oncol* 2022;7(1):76-78.