

Content available at: <https://www.ipinnovative.com/open-access-journals>

IP Journal of Diagnostic Pathology and Oncology

Journal homepage: <https://www.jdpo.org/>

Case Report

Mucinous cystadenoma of the Thymus presenting as a mediastinal mass in a child

Sheba S K Jacob^{1,*}, Ashok Parameswaran¹, Rajan Santosham², Rajiv Santosham²

¹Dept. of Pathology, Apollo Hospitals, Chennai, Tamil Nadu, India

²Dept. of Thoracic Surgery, Apollo Hospitals, Chennai, Tamil Nadu, India



ARTICLE INFO

Article history:

Received 19-01-2022

Accepted 26-01-2022

Available online 28-02-2022

Keywords:

Mucinous cystadenoma

Thymus

Mediastinal mass

Child

ABSTRACT

Background: This is the first case report of a mucinous cystadenoma of the thymus. So this case is reported for awareness that mucinous cystadenomas can occur in the mediastinum with a review of literature and the need for complete surgical excision.

Case Report: A twelve year old girl with a cystic mediastinal mass, presented with dry cough for three weeks. The mass was completely excised as it was huge and causing pressure symptoms. On light microscopy, there was thymic tissue with a mucinous cystadenoma. This is the first report of a mucinous cystadenoma in the thymus. Mucinous cystadenomas can grow into large sizes and become symptomatic due to pressure or rupture prompting investigation.

Conclusion: Complete surgical excision is advised as mucinous cystadenocarcinoma of the thymus has to be ruled out by adequate sampling and careful analysis of the morphology.

This is an Open Access (OA) journal, and articles are distributed under the terms of the [Creative Commons Attribution-NonCommercial-ShareAlike 4.0 License](https://creativecommons.org/licenses/by-nc-sa/4.0/), which allows others to remix, tweak, and build upon the work non-commercially, as long as appropriate credit is given and the new creations are licensed under the identical terms.

For reprints contact: reprint@ipinnovative.com

1. Introduction

Mucinous tumours are lined by columnar epithelial cells with intracytoplasmic mucin, forming cysts or glands resembling those of the stomach, endocervix or the intestine. They are found predominantly in females and the histogenesis of these tumours are not yet deciphered. Although mucinous tumours have been described in the ovary, appendix, retroperitoneum and testis,¹⁻⁴ mucinous cystadenoma of the thymus has not been reported. Though it is a benign entity, complications can occur due to rupture⁵ or pressure on the adjacent vital structures due to their nature to grow into enormous size or progress towards malignancy and hence warrants complete excision. We encountered an interesting case of a mucinous cystadenoma of the thymus in a twelve year old girl; the rarity of the case prompting this report.

* Corresponding author.

E-mail address: shebajacob25@gmail.com (S. S. K. Jacob).

2. Case History

A 12 year old girl, with no significant past medical history, presented to our hospital with persistent, dry cough of three weeks duration. She had no other symptoms. Clinical examination was non-contributory, except for reduced breath sounds over the right hemithorax. The chest radiograph revealed a large, well defined opacity in the right hemithorax (Figure 1).

A large, well defined, anterior mediastinal mass was noted on computed tomography (CT) of the chest. It was a predominantly cystic multilocular lesion with a small solid component, with areas of calcification (Figure 2). Positron Emission Tomography (PET) showed no fluorodeoxyglucose (FDG) avid foci.

Serum β - Human Chorionic Gonadotrophin (β HCG) and α fetoprotein (AFP) levels were not elevated. Among the diagnostic considerations entertained was a thymic cyst, a cystic germ cell neoplasm or a lymphoma with cystic degeneration.

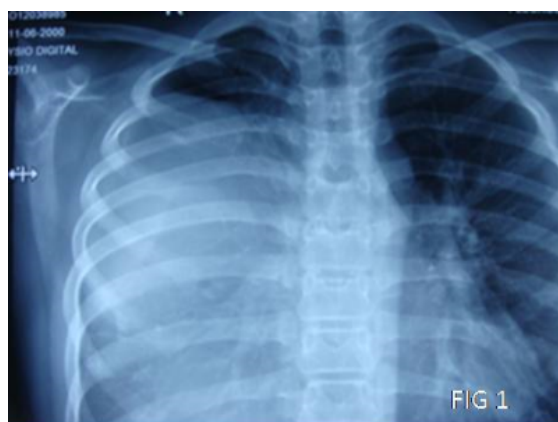


Fig. 1: Chest Xray with a large well defined opacity in the right hemithorax.

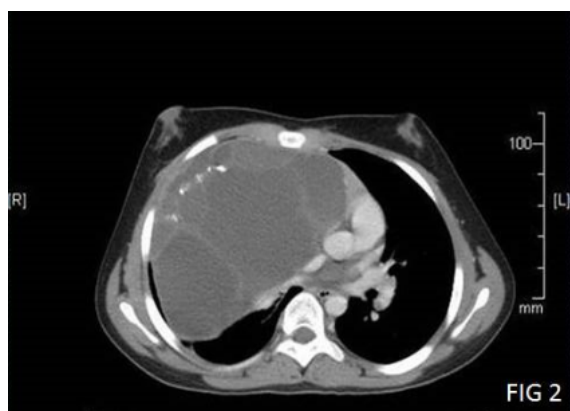


Fig. 2: Computed tomography of the chest displaying a large, well defined, anterior mediastinal mass with multiloculation and focal areas of calcification.

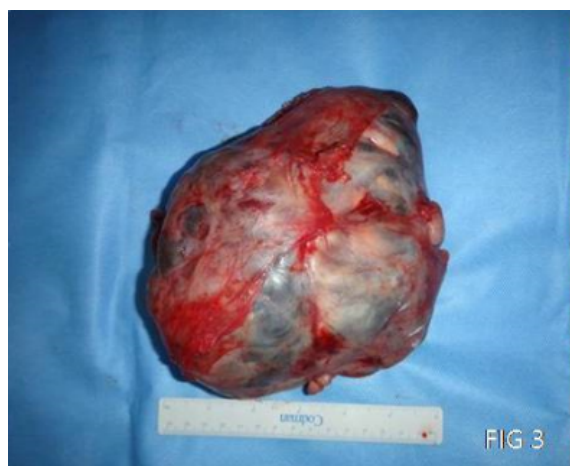

Fig. 3: Grossly the mass was smooth surfaced, cystic and had a well-defined capsule.

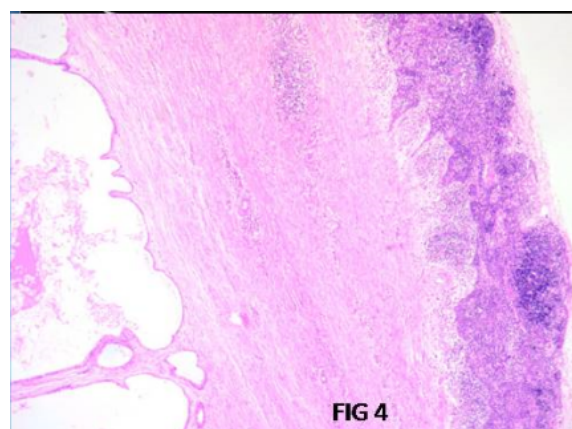


Fig. 4: Multiloculated cyst lined by benign mucinous epithelium with interspersed goblet and Paneth cells surrounded by fibrosed and hyalinised stroma and thymic tissue is noted in the periphery.

A CT guided needle biopsy from the mass was inconclusive; so thoracotomy was done and the mass was excised completely. The mass was 15 x 14 x 10cms and occupied the mediastinum and right hemithorax and compressed the adjacent lung. It was smooth surfaced, appeared cystic, and had a well-defined capsule. (Figure 3).

Cut surface was cystic and multiloculated. The cysts were filled with mucinous material and focal calcified areas were present. At light microscopy, a multilocular cystic neoplasm lined by tall mucinous epithelium with basally arranged bland nuclei and interspersed goblet and Paneth cells was noted. Focal extravasation of mucin into the stroma was also seen. Elsewhere the stroma had areas of fibrosis with hyalinisation, calcification and focal collections of cyst macrophages. The capsule was not breached.

The post-operative period was uneventful and the patient was advised a close follow up; and is doing well ten years post-surgery.

3. Discussion

Primary mucinous cystadenoma is rare in children and tumour arising from the thymus has not been reported. It is a tumour of adults, occurs mostly in the ovary but rare tumours have been reported to occur in the retroperitoneum, appendix, pancreas, ureter, biliary system and the testis.^{6,7} It has been proposed that it may arise from metaplastic epithelium or could be a part of a teratoma or a monodermal teratoma.

These are composed of glands and cysts lined by bland columnar cells with basal nuclei and mucin positivity. They can grow into large masses and cause pressure symptoms prompting investigation. The main differential diagnosis is a primary mucinous adenocarcinoma of the thymus⁸ which has to be ruled out by adequate sampling and careful analysis of the morphology. The other differentials for

cystic lesions in the thymus are congenital thymic cysts which occur in children as an unilocular cyst, lined by flattened, cuboidal, ciliated columnar or stratified squamous epithelium. Multilocular, acquired cysts occur in adults and are lined by squamous or ciliated columnar epithelium. Fibrosis, chronic inflammation and haemorrhage may also be seen.

Malignant tumours like nodular sclerosis Hodgkin lymphoma, seminoma, and thymoma can present with cystic change and the other benign differentials are bronchogenic cyst, pericardial cyst and lymphangioma.

In this case, the cyst was multiloculated and lined by uniform benign mucinous epithelium with interspersed goblet and Paneth cells, and surrounded by fibrosed and hyalinised stroma and thymic tissue. (Figure 4) The tumour had a similar appearance of a mucinous cystadenoma of the ovary.

As this type of tumour has not been described earlier in the thymus, it is difficult to predict the behaviour. Hence, though the tumour was completely resected with uninvolved margins, a follow up was advised.

4. Conclusion

This is the first case report of a mucinous cystadenoma of the thymus in a child. Cystic changes in malignant neoplasms form a differential diagnosis and complications can occur due to pressure effects on the adjacent vital structures or if it ruptures. So complete surgical excision of the mass is warranted.

5. Conflict of Interest

The authors declare that there is no conflict of interest.

6. Source of Funding

None.

References

1. Etensel B, Gürsoy H, Erkuş M. Mucinous cystadenoma: a rare abdominal mass in childhood. *Eur J Pediatric Surg.* 2002;12(5):330–2.
2. Vriens BHR, Klaase JM. Giant mucinous cystadenoma of the appendix. *Am J Surg.* 2007;194(3):392–3. doi:10.1016/j.amjsurg.2006.11.041.
3. Abedalthagafi M, Jackson PG, Ozdemirli M. Primary retroperitoneal mucinous cystadenoma. *Saudi Med J;*30:146–9.
4. Nokubi M, Kawai T, Mitsu S, Ishikawa S, Morinaga S. Mucinous cystadenoma of the testis. *Pathol Int.* 2002;52(10):648–52. doi:10.1046/j.1440-1827.2002.01409.x.
5. Kragel PJ, Devaney KO, Meth BM, Linnoila I, Frierson HF, Travis WD, et al. Mucinous cystadenoma of the lung. A report of two cases with immunohistochemical and ultrastructural analysis. *Arch Pathol Lab Med.* 1990;114(10):1053–6.
6. Zamboni G, Scarpa A, Bogina G, Iacono C, Bassi C, Talamini G, et al. Mucinous cystic tumors of the pancreas: clinicopathological features, prognosis, and relationship to other mucinous cystic tumors. *Am J Surg Pathol.* 1999;23(4):410–22.
7. Jain D, Sethi S, Wadhwa SN. Mucinous cystadenoma of the ureter. *Ann Diagn Pathol.* 2011;15(6):459–61. doi:10.1016/j.anndiagpath.2010.07.007.
8. Kapur P, Rakheja D, Bastasch M, Molberg KH, Sarode VR. Primary mucinous adenocarcinoma of the thymus: a case report and review of the literature. *Arch Pathol Lab Med.* 2006;130(2):201–4.

Author biography

Sheba S K Jacob, Senior Consultant  <https://orcid.org/0000-0002-6515-0697>

Ashok Parameswaran, Senior Consultant

Rajan Santosham, Senior Consultant

Rajiv Santosham, Consultant

Cite this article: Jacob SSK, Parameswaran A, Santosham R, Santosham R. Mucinous cystadenoma of the Thymus presenting as a mediastinal mass in a child. *IP J Diagn Pathol Oncol* 2022;7(1):67-69.