

Content available at: <https://www.ipinnovative.com/open-access-journals>

IP Journal of Diagnostic Pathology and Oncology

Journal homepage: <https://www.jdpo.org/>

Case Report

Primary testicular T cell Non Hodgkin Lymphoma with unusual histomorphology: A rare case

Madan K¹, Nisarga Rani R^{1,*}, Siddhartha Biswas¹, Anuradha C K Rao²

¹Dept. of Oncopathology, Yenepoya Medical College, Mangalore, Karnataka, India

²Dept. of Pathology, Yenepoya Medical College, Mangalore, Karnataka, India



ARTICLE INFO

Article history:

Received 24-10-2021

Accepted 13-11-2021

Available online 28-02-2022

Keywords:

Non Hodgkin lymphoma

Peripheral T cell lymphoma

Testicular lymphoma

ABSTRACT

Primary testicular non-Hodgkin lymphoma (NHL) is an uncommon extra nodal lymphoma presentation, constituting 1-2% of all lymphomas. Majority are of B-Cell type, with very few cases being primary T-Cell phenotype.

A 28 years male presented with painless, unilateral testicular swelling with elevated serum LDH levels, beta HCG and AFP serum levels were within normal limits.

Gross evaluation of high inguinal orchidectomy specimen showed an enlarged homogenous, grey white lobulated mass with adjacent entrapped testicular parenchyma. Microscopy showed diffuse sheets of medium sized, monomorphic atypical lymphoid cells with sparing of adjacent seminiferous tubules. A panel of Immunohistochemistry markers done were suggestive of T-Cell Non-Hodgkin Lymphoma.

Testicular T cell NHL are extremely rare amongst the testicular lymphomas, constituting for 5% of all testicular tumours. This case is being presented for its rarity in literature, especially in young age group and the unusual histomorphology.

This is an Open Access (OA) journal, and articles are distributed under the terms of the [Creative Commons Attribution-NonCommercial-ShareAlike 4.0 License](https://creativecommons.org/licenses/by-nc-sa/4.0/), which allows others to remix, tweak, and build upon the work non-commercially, as long as appropriate credit is given and the new creations are licensed under the identical terms.

For reprints contact: reprint@ipinnovative.com

1. Introduction

Primary testicular lymphoma (PTL) is an uncommon and aggressive form of extra nodal Non Hodgkin lymphoma(NHL), commonly occurring in elderly. Testicular lymphomas accounts for 1 -2% of all lymphomas, 4% of extranodal lymphomas and 5% of testicular neoplasms.¹

PTL are commonly occur at the age over 60 years, with mean age of 64 years. Most of these patients present with a unilateral painless scrotal mass, although bilateral presentation is seen in 15% of the cases.²

Vast majority of Primary testicular lymphomas are of B cell type, the common ones being diffuse large B cell lymphoma (DLBCL) and Follicular lymphoma (FL). DLBCL is the most common (80-90%) histological type

of primary testicular lymphoma, however secondary involvement of testis by leukemic cells in Acute lymphoblastic lymphoma is seen in young patients. T-cell lymphomas are very rare either as a primary or secondary testicular involvement.

Hence, we present a rare and unusual case of Non Hodgkin lymphoma of T cell phenotype of testis, in a young male.

2. Case Presentation

A 28 year young male, who is deaf and mute by birth with marfanoid facies, presented to the Oncology department, with a left testicular swelling of one month duration. The patient's general condition at presentation was fair. General physical and systemic examination were normal. On local examination, a non tender, unilateral testicular

* Corresponding author.

E-mail address: nisarga.rani91@gmail.com (N. Rani R).

mass of 10 X 7 X 4cm was noted, which was firm to hard in consistency. Clinically he was suspected to have a Non Seminomatous germ cell tumor(NSGCT) of left testis. Routine haematological and biochemical investigations were carried out. Of the biochemical parameters, serum LDH was significantly elevated, serum beta HCG and AFP were within normal limits. Peripheral smear examination was within normal limits. Chest X-ray was normal.

Ultrasonography showed hydrouretronephrosis with multiple abdominal lymphnodes.

After routine pre-operative work-up, the patient underwent left high inguinal orchidectomy and the specimen was sent for histopathological evaluation.

On gross examination, testis was enlarged (10x7x4cm) with an intact tunica vaginalis and spermatic cord (6cm in length) was thickened. Cut surface of testis showed a solid, homogenous, grey white, lobulated tumour with bulging surface, with a small adjacent area of normal testicular parenchyma measuring 2x2cm. No hemorrhagic / necrotic areas were seen. (Figure 1a,b) Representative areas were sampled and processed for microscopic evaluation.

Microscopy showed a cellular neoplasm with cells arranged in lobules, sheets and vague alveolar pattern. These cells were medium sized, round with scant cytoplasm. Occasional large cells were noted (Figures 2, 3 and 4). Numerous thin walled proliferating vessels were noted. Focal areas of necrosis seen. These tumour cells were seen infiltrating through the adjacent reminiscent seminiferous tubules and sparing them. Epididymis and spermatic cord were involved by the tumour cells. Focally, the tumour cells were seen involving the tunica vaginalis.

Based on these morphological features and considering the clinical presentation a provisional diagnosis of Malignant round cell tumour was provided. Malignant lymphoma, Rhabdomyosarcoma and Seminoma were the differentials and panel of immunohistochemistry (IHC) markers were considered to arrive at definitive diagnosis. Immunohistochemistry(IHC) was performed as per standard protocols. IHC showed unexpected results.

The tumour cells were diffusely immunoreactive for LCA and CD3 with focal positivity for EMA and CD30. The latter showed golgi staining pattern. CD20, PanCK, SMA, Desmin, CD117 were all negative in the tumour cells (Figures 5, 6, 7, 8 and 9).

Correlating Immunomorphological with the clinical and radiological findings, we arrived at a diagnosis of primary Testicular T-cell Non Hodgkin Lymphoma, probably anaplastic large cell lymphoma (ALCL). However further immunohistochemistry with ALK was not performed. This was required due to the absence of embryoid cells and the medium sized, almost monomorphic predominant cell population, unusual to a classical ALCL. Other variants of T cell lymphomas were ruled out due to tumour cell positivity for EMA and Cd30 (golgi zone) combination along with

raised LDH levels.

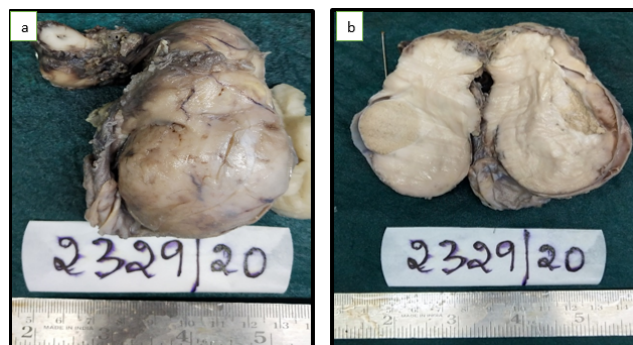


Fig. 1: a-b : Gross specimen showing enlarged testis. Cut open diffuse grey white solid tumour with adjacent area of normal testis.

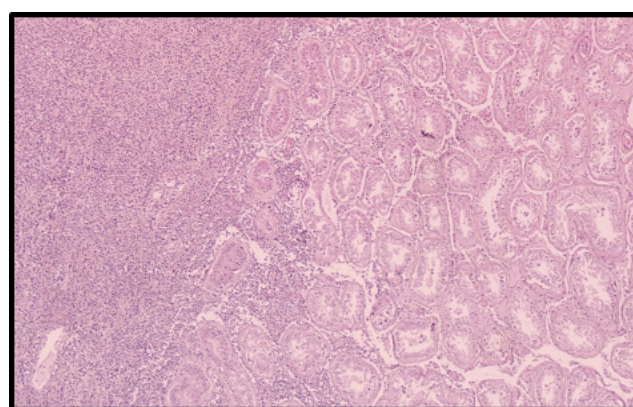


Fig. 2: H&E, 100x: Showing sheets of tumour cells with adjacent normal seminiferous tubules.

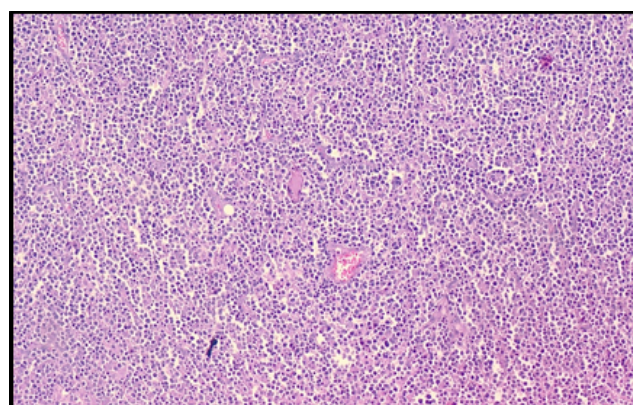


Fig. 3: H&E, 100x: Tumour cells arranged in diffuse sheets with interspersed congested vessels.

3. Discussion

Testicular lymphomas comprise 5% of all testicular malignancies and these account for about 1% of all

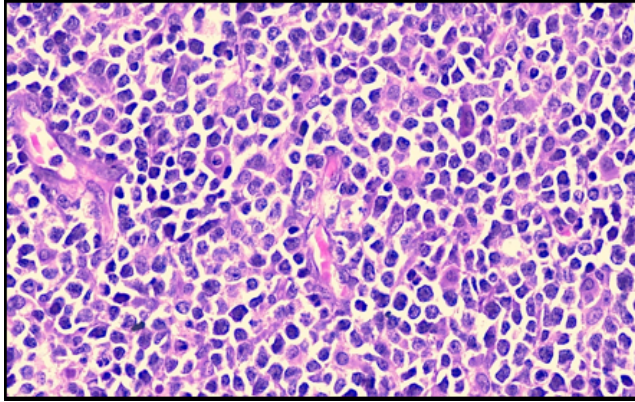


Fig. 4: H & E, 400x: Diffuse sheets of medium sized, monomorphic atypical lymphoid cells.

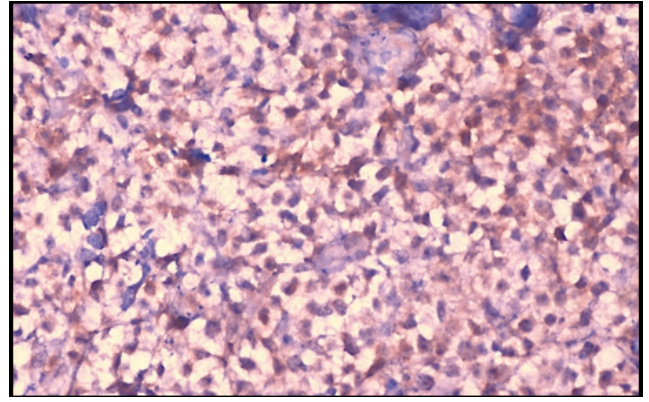


Fig. 7: IHC, 400x: Tumour cells show paranuclear positivity for CD30.

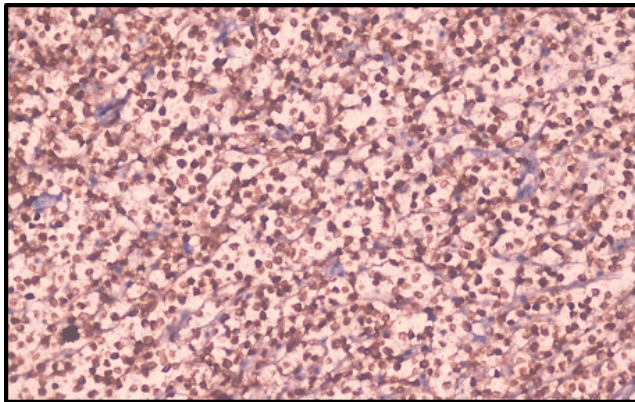


Fig. 5: IHC, 400x: Tumour cells show diffuse positivity for CD3.

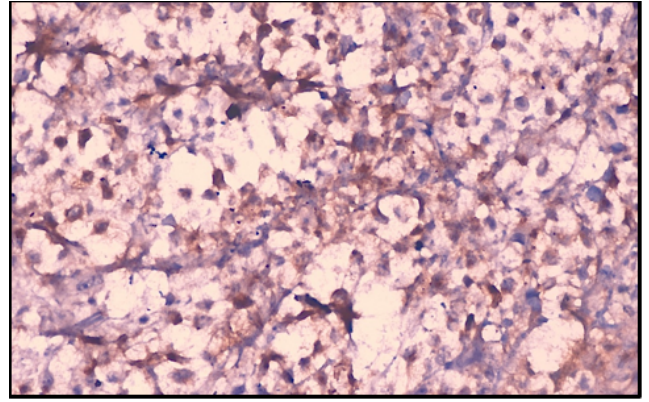


Fig. 8: IHC, 400x: Tumour cells are positive for EMA.

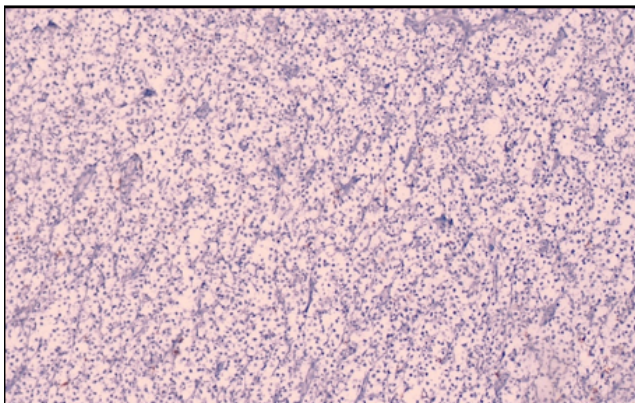


Fig. 6: IHC, 100x: Tumour cells are negative for CD20.

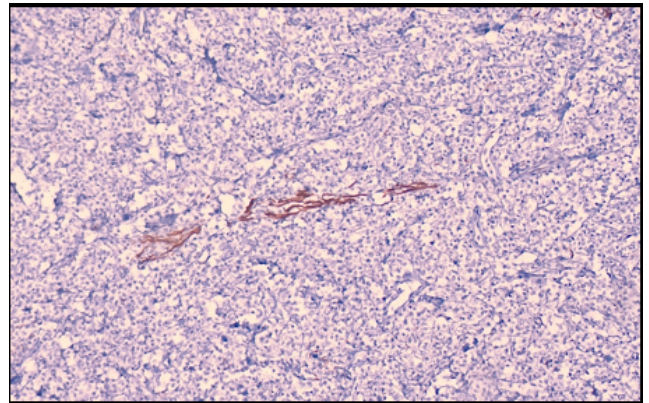


Fig. 9: IHC, 40x: Tumour cells are negative for Desmin.

lymphomas. T-cell lymphoma of the testis is rare whether as a primary or secondary tumor.²

In primary T-cell lymphomas, most case reports are of T-cell/Natural Killer (NK) cell lymphomas with very few cases of primary T-cell lymphoma (Not otherwise specified). Our case represents one of those few cases of primary T-cell lymphomas morphologically on H&E with CD30 and EMA positivity suggestive of ALCL.³

NHL is the most common testicular tumour in the age group of 60 to 80 years with mean age of presentation at 64 years. Testicular lymphomas are rare in young adults. Our patient had an unusual presentation at a young age of 28 years. Existing case reports are of adult patients.⁴

Clinical presentation is usually of a painless, unilateral testicular swelling, similar to our patient. Symptoms of occasional sharp pain have been documented, with cases of abdominal pain with ascites being reported due to large retroperitoneal lymph nodes. Our patient had mild left hydro-ureteronephrosis due to compression by multiple paraaortic and iliac lymph nodes. Associated B-symptoms (fever, night sweats, and weight loss) usually present only in advanced stages, accounting for 25% to 41% of patients at diagnosis, which were absent in our case.³

Patients have normal serum lactate dehydrogenase unlike our case, LDH was elevated, which favours ALCL over TCL, NOS.

Typical sonographic features of PTL vary between an enlarged, diffusely hypoechoic and hypervascular testis; unilateral or bilateral focal hypoechoic nodules; or a striated testicular pattern.⁴

The tunica albuginea and epididymis can be involved and a hydrocele occurs in approximately 50% of cases. However, none of these features in isolation is specific to PTL, meaning diagnostic biopsy is required.^{4,5} In our case testis was enlarged with intact capsule (tunica vaginalis), spermatic cord was thickened. However it was free of tumour.

The histopathological features, varies according to the subtype. The present case showed morphological and immunohistochemical overlap of features of TCL-NOS & ALCL variant. ALCL like in our case, can show predominantly medium sized cells with occasional large cells and interspersed prominent vasculature. Characteristic immunohistochemistry for confirmation are paranuclear dot positivity with CD30 EMA positivity with further subtyping by ALK staining. Both ALK positive and negative ALCL have been documented. In our case CD30 was performed, however ALK staining was not performed. CD30 positive primary T cell lymphoma is a category in WHO classification. It shows morphology of small/ medium sized cells and occasional large cells. However all PTCL-NOS are known to be EMA negative. Our case was unusual as morphology was like PTCL-NOS on H&E and like ALCL on IHC.

Testicular T-cell lymphoma deserves to be distinguished from the other testicular lymphomas for example, diffuse large B-cell lymphoma and Hodgkin's lymphoma, because of the different treatment options. Response to multi-agent chemotherapy (such as CHOP, bleomycin, adriamycin, cyclophosphamide, vincristine, and prednisone (BACOP), or ProMACE-CytaBOM is often poor, even if complete remission is obtained, relapse may develop soon after. Our patient received chemotherapy the conventional cyclophosphamide, adriamycin, vincristine, and prednisolone (CHOP) regimen.⁶⁻⁸

Testicular lymphoma is a lethal disease with a median survival of approximately 12 to 24 months. Till date with 12 months follow up our patient is alive, without residual/recurrent disease or metastasis.

More aggressive treatment should be sought for this particular malignancy. A common protocol has still not been developed for refractory or relapsed peripheral T-cell lymphoma. Hence more studies are needed to panelise the treatment.

4. Conclusion

Testicular primary T cell lymphomas are rare and highly aggressive malignant neoplasms. Unusual cases can show considerable overlap morphologically between PTCL-NOS and ALCL. The important clinical and histological differentials being Seminoma, nodal Hodgkin's lymphoma infiltrating testis & Lymphoblastic leukemias involving testis as relapse especially in children and young adults.³ Knowledge about possibility of such rare entity and appropriate diagnosis with Immunohistochemical technique is mandatory for the proper treatment and management. A regular long term follow up is further essential in ascertaining the behaviour of such an entity.

5. Conflict of Interest

The authors declare that there is no conflict of interest.

6. Source of Funding

None.

References

1. Ferry JA. Haematolymphoid tumours. In: Moch H, Humphrey PA, Ulbright TM, Reuter V, editors. WHO Classification of Tumours of the Urinary System and Male Genital Organs, 4th Edn. IARC, Lyon; 240. p. 240.
2. Haroon S, Ahmed A. Peripheral T-cell lymphoma presenting as testicular mass; a diagnostic challenge. *World J Surg Onc.* 2013;11:68. doi:10.1186/1477-7819-11-68.
3. Pal MS, Kaur M, Gupta N, Bodal VK. Primary Testicular T-Cell Non-Hodgkin's Lymphoma. Research and Reviews. *J Med Sci Health.* 2014;3:47-50.
4. Romero AJ, Alegret AR, Serrano P, Mayayo E. Primary anaplastic large cell lymphoma of the testes. *Int Urol Nephrol.* 2004;36(3):393-6. doi:10.1007/s11255-004-0750-3.

5. Ellatif M, Kumar R, Weller A, Katz D, Vrentzou E. Two Cases of Primary Testicular Lymphoma presenting with direct Spread along the Spermatic Cord and Gonadal Vessels. *Hindawi*. 2019;1:6. doi:10.1155/2019/5953618.
6. Ferry JA, Ulbright TM, Young RH. Anaplastic large cell lymphoma of the testis: a lesion that may be confused with embryonal carcinoma. *J Urol Pathol*. 1996;5:139–47.
7. Matsuda M, Iwanaga T, Hashimoto S, Uesugi T, Itagaki N. Primary Epstein- Barr virus-negative nasal-type natural killer/T cell lymphoma of the testis. *Leuk Res*. 2009;33:119–20.
8. Kawasaki H, Shigeno K, Ohnishi K, Tsuchida T, Miura K. A case of primary cutaneous natural killer/T-cell lymphoma, nasal type, directly invading to the heart. *Leuk Lymphoma*. 2008;49(5):1008–11. doi:10.1080/10428190801947518.

Author biography

Madan K, Assistant Professor

Nisarga Rani R, Fellow

Siddhartha Biswas, Professor and HOD

Anuradha C K Rao, Professor

Cite this article: Madan K, Rani R N, Biswas S, Rao ACK. Primary testicular T cell Non Hodgkin Lymphoma with unusual histomorphology: A rare case. *IP J Diagn Pathol Oncol* 2022;7(1):55-59.