

Content available at: <https://www.ipinnovative.com/open-access-journals>

IP Journal of Diagnostic Pathology and Oncology

Journal homepage: <https://www.jdpo.org/>

Case Report

Colonic ganglioneuromatous polyposis in a 6-year-old girl – A case report and review of literature

G. Sathibai Panicker¹, Reshma M^{1,*}, Reeba Mary Issac¹

¹Dept. of Pathology, Pushpagiri Institute of Medical Sciences and Research Centre, Thiruvalla, Kerala, India



ARTICLE INFO

Article history:

Received 26-08-2021

Accepted 09-10-2021

Available online 26-11-2021

Keywords:

Abdominal pain

Childhood

Colonic

Ganglioneuromatous polyposis

ABSTRACT

Ganglioneuroma of the gastrointestinal tract is a rare mesenchymal tumor of neural origin, especially in childhood. They are categorized into three different morphological subtypes, namely, polypoid ganglioneuroma, ganglioneuromatous polyposis (GP), and diffuse ganglioneuromatosis. Patients with ganglioneuromas have different presentations depending on the location, extent, and size of the lesion. We report here a case of colonic ganglioneuromatous polyposis, presenting as abdominal pain and chronic constipation in a 6-year-old girl. Although GP cases are reported in adult age group, cases in pediatric age group are rare. Only a few cases are reported in the literature of GP in the pediatric age group. Although rare, this disorder must be taken into consideration in the differential diagnosis in every patient with symptoms such as abdominal pain, constipation, and lower intestinal bleeding, to avoid a delayed diagnosis.

This is an Open Access (OA) journal, and articles are distributed under the terms of the [Creative Commons Attribution-NonCommercial-ShareAlike 4.0 License](https://creativecommons.org/licenses/by-nc-sa/4.0/), which allows others to remix, tweak, and build upon the work non-commercially, as long as appropriate credit is given and the new creations are licensed under the identical terms.

For reprints contact: reprint@ipinnovative.com

1. Introduction

Ganglioneuromas are rare benign Schwann cell and ganglion cell proliferative lesions that occur in various anatomical sites. Rare cases of ganglioneuromas occurring as polypoid lesions in GI tract, more in the colon has been reported. These lesions may manifest as mucosa-based polyps that arise as sporadic solitary polypoid ganglioneuromas, as ganglioneuromatous polyposis with multiple polyps involving the lower and upper GI tract, or as diffuse ganglioneuromatosis that may involve the deeper aspects of the bowel wall. Ganglioneuromatous polyposis (GP) is often associated with Cowden syndrome¹ whereas diffuse ganglioneuromatosis is associated with multiple endocrine neoplasia (MEN) type 2b and neurofibromatosis type 1 (NF1).²

2. Case History

A 6-year-old girl presented to the OPD with complaints of periumbilical abdominal pain, intermittent difficulty in defecation, bleeding per rectum, vomiting, loss of weight, and loss of appetite for the past three to four years. The patient had a history of rectal polyp excision four years back and sigmoidoscopy two years back. No previous reports were available.

Her vitals and other lab investigation parameters were within normal limits. She was admitted for colonoscopic evaluation.

Colonoscopy showed multiple polyps throughout the colon, with the largest polyps in the caecum and hepatic flexure measuring 2 x 1 cm each. A pedunculated polyp was also noted in the sigmoid. Biopsy was taken from polyps in the caecum, hepatic flexure, and sigmoid colon and was received as multiple fragments.

Microscopic examination of all the fragments showed colonic mucosa with expansion of lamina propria by bland

* Corresponding author.

E-mail address: teelu123@gmail.com (Reshma M).

spindle-shaped cells admixed with scattered ganglion cells and numerous eosinophils (Figure 1). Individual ganglion cells were large with abundant eosinophilic cytoplasm, eccentric large round nucleus with prominent nucleoli (Figure 2). Immunohistochemistry showed strong positive staining in the neoplastic cells for S100 (Figures 3 and 4).

A diagnosis of colonic ganglioneuromatous polyposis was made. Detailed history taking and physical examination revealed no evidence of any preexisting symptoms of Cowden syndrome, MEN2B, or NF1.

The family members were counseled, the patient treated symptomatically, and discharged uneventfully. She was symptom-free on repeat examination after a week and was lost to further follow-up.

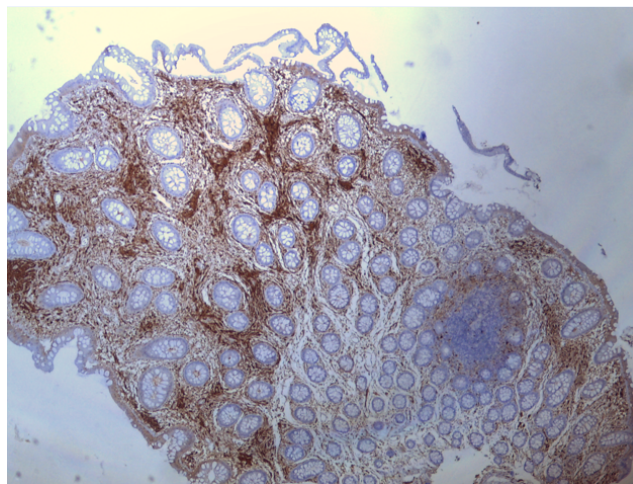


Fig. 3: IHC for S100 – positive in Schwann cells (40x)

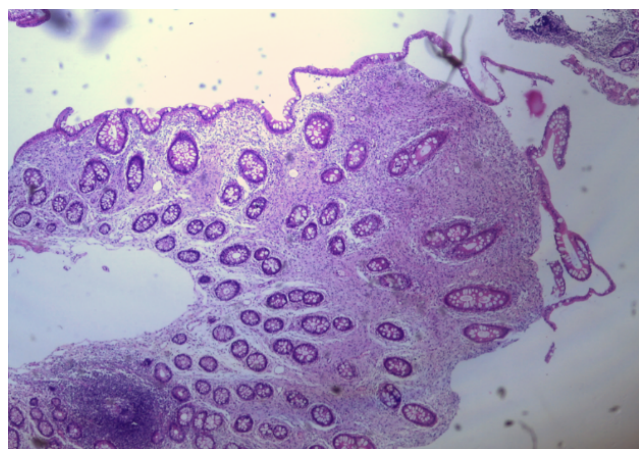


Fig. 1: Colonic mucosal fragments showing expansion of lamina propria (H&E, 40x)

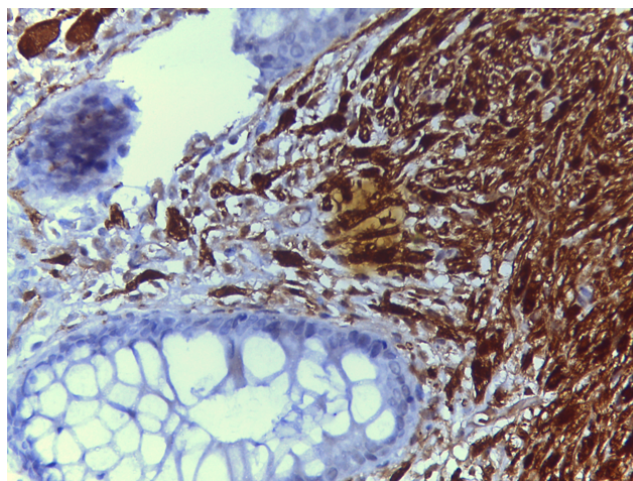


Fig. 4: IHC for S100 – positive in Schwann cells (400x)

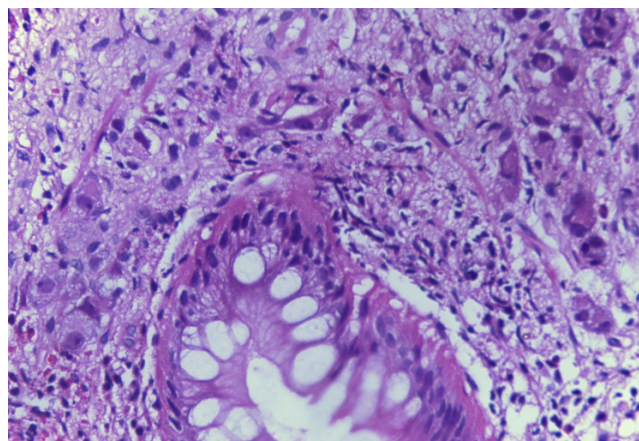


Fig. 2: Proliferation of spindle shaped cells admixed with scattered ganglion cells (H&E, 400x)

3. Discussion

Ganglioneuroma is a rare benign neoplasm of neural origin composed of mature ganglion cells, satellite cells, and Schwann cells. They are found at various anatomical sites in the body including mediastinum, retroperitoneum, adrenal glands, as well as GI tract.

Shekitka et al. proposed to divide intestinal ganglioneuroma formations into three groups: polypoid ganglioneuromas, diffuse ganglioneuromatosis and ganglioneuromatous polyposis.²

Most ganglioneuromas of the GI tract occur in the colon, with a predilection for the left side and the rectum. Solitary polypoid ganglioneuromas are most common and are usually identified incidentally at the time of colonoscopy in middle-aged to older adults.^{3–5} Ganglioneuromatous polyposis usually presents as multiple sessile or pedunculated polyps with a varied extent of involvement in the GI tract. It is often associated with Cowden syndrome

where multiple polypoid ganglioneuromas are seen in addition to several other types of polyps, including hyperplastic polyps, adenomas, inflammatory polyps, and hamartomatous polyps.¹ Diffuse ganglioneuromatosis may manifest as bowel wall thickening or a more discrete mass.⁶ It has an association with MEN type 2B and less commonly with NF1 with germline mutations identified in RET, and NF1 respectively.

The clinical presentation of ganglioneuroma is quite variable depending on the location and size of the lesion. GI ganglioneuroma may present with abdominal pain, rectal bleeding, constipation, diarrhea, intestinal motility disorders, and megacolon with intestinal obstruction.^{3,5,7,8} Colonic ganglioneuromas are confirmed by colonoscopy followed by polypectomy or biopsy.

Histologically polypoid ganglioneuromas show hypercellular lamina propria composed of cytologically bland, spindle-shaped cells with schwannian features, ganglion cells, and eosinophils. The glandular epithelium is often splayed apart by the expanded lamina propria, resulting in a distorted appearance. Immunohistochemical markers of neural differentiation (neuron-specific enolase, neurofilament) highlight ganglion cells, and S100 diffusely stains the Schwannian component.

These lesions are benign and usually seen in adult population. Rarely it has been reported in pediatric population. Mitra S et al.⁶ reported a case of diffuse intestinal ganglioneuromatosis, presenting as intestinal obstruction and chronic constipation in an 11-year-old boy. No other systemic manifestations or syndromic association were identified in that case. Soccorso et al.⁹ described a case of a 5-year-old girl who presented with intermittent colocolic intussusception. A ganglioneuroma centered in the muscularis propria of the sigmoid colon was identified.

When presenting as polypoid ganglioneuromas, cystic glands may be present in the lesion, reminiscent of juvenile polyps in some cases and this can create a diagnostic dilemma. Multiple colonic polyps occurring in childhood are more suggestive of syndromic diseases like Juvenile polyposis syndrome, Cowden's syndrome and Familial adenomatous polyposis, typically associated with positive family history. However in this case there were no pathognomonic clinical evidence of syndromic association or family history of GI tract disorders and the patient had been advised regular surveillance.

Management is ultimately determined based on the initial presentation of the patient and whether a germline mutation is identified. Clinical recognition and diagnosis of individuals who are at risk of harboring germline mutations

are critical for the prevention and management of potentially life-threatening neoplasms.

4. Source of funding

No financial support was received for the work within this manuscript.

5. Conflicts of interest

There are no conflicts of interest

References

1. Pistorius S, Klink B, Pablik J, Rump A, Aust D, Garzarolli M. An unusual case of Cowden syndrome associated with ganglioneuromatous polyposis. *Hered Cancer Clin Pract.* 2016;14. doi:10.1186/s13053-016-0051-8.
2. Shekitka KM, Sobin LH. Ganglioneuromas of the gastrointestinal tract. Relation to Von Recklinghausen disease and other multiple tumor syndromes. *Am J Surg Pathol.* 1994;18(3):250–7.
3. Abraham G, Prakash SR. Case Report Solitary Colonic Ganglioneuroma : A Rare Incidental Finding of Hematochezia. *Case Rep Gastrointest Med.* 2015;doi:10.1155/2015/794985.
4. Ofori E, Ona M, Ramai D, Xiao P, Reddy M, Huang T, et al. Colonic Ganglioneuroma : A Rare Finding during Colorectal Cancer Screening. *Case Rep Gastroenterol.* 2017;11:434–9. doi:10.1159/000477716.
5. Herman M, Abed J, Shi W, Buyuk A, Mankal PK, Kotler D, et al. A case of ganglioneuroma of the colon during routine colonoscopy. *Int J Case Rep Images.* 2015;6(9):560–3.
6. Mitra S, Mukherjee S, Chakraborty H. Isolated ileal ganglioneuromatosis in an 11-year-old boy: Case report and review of literature. *Indian J Pathol Microbiol.* 2016;59(3):365–7. doi:10.4103/0377-4929.188109.
7. Baiomi A, Abbas H, Niazi M, Remotti H. Colonic Ganglioneuroma : A Rare Lesion With Extremely Different Presentations and Outcomes in Two Patients. *Gastroenterology Res.* 2021;14(3):194–202. doi:10.14740/gr1379.
8. Nehme C, Ghazaleh S, Patel D, Hasan S, Nawras A. Incidental Ascending Colon Ganglioneuroma in the Setting of Hematochezia. *Cureus.* 2020;12(7):e9447. doi:10.7759/cureus.9447.
9. Soccorso G, Puls F, Richards C, Pringle H, Nour S. A ganglioneuroma of the sigmoid colon presenting as leading point of intussusception in a child : a case report. *J Pediatr Surg.* 2009;44(1):17–20.

Author biography

G. Sathibai Panicker, Professor

Reshma M, Junior Resident

Reeba Mary Issac, Senior Resident

Cite this article: Panicker GS, Reshma M, Issac RM. Colonic ganglioneuromatous polyposis in a 6-year-old girl – A case report and review of literature. *IP J Diagn Pathol Oncol* 2021;6(4):325-327.