



Case Report

Ectodermal dysplasia with classical clinical presentation: A rare case report

Nitesh Mohan^{1,*}, P. K. Rathore²

¹Dept. of Pathology, Rohilkhand Medical College & Hospital, Bareilly, Uttar Pradesh, India

²Dept. of Dermatology, Rohilkhand Medical College & Hospital, Bareilly, Uttar Pradesh, India



ARTICLE INFO

Article history:

Received 01-12-2020

Accepted 10-12-2020

Available online 18-12-2020

Keywords:

Ectodermal dysplasia

Hereditary disorders

Anamolies

ABSTRACT

Background: Ectodermal dysplasia is a syndrome consisting of heterogeneous group of hereditary malformations which have similar findings and are inherited genetically. These disorders affect the ectodermal derived tissues (hair, nails, teeth, skin and sweat glands) and lead to development of two or more tissue anomalies with heterogeneous characteristics.

Case History: We report a rare case of 16 year old male presenting to us with complaints of decreased sweating, itching all over skin when exposed to sun, hypodontia, madarosis and sparse scalp hair. Thorough examination revealed classical syndromic anomalies. Skin biopsy revealed dyskeratosis and acantholysis with reduced skin adnexae.

Conclusion: Ectodermal dysplasia is a heterogeneous group of hereditary malformations and irregularities which have similar findings. Ectodermal dysplasia not only creates tissue malformations but, the quality of life of patients is also affected.

© This is an open access article distributed under the terms of the Creative Commons Attribution License (<https://creativecommons.org/licenses/by/4.0/>) which permits unrestricted use, distribution, and reproduction in any medium, provided the original author and source are credited.

1. Introduction

Ectodermal dysplasias (EDs) comprises of large, heterogeneous group of inherited disorders that are defined as primary defects in the development of two or more tissues derived from ectodermal layer.¹

Despite some of the syndromes have different genetic causes, the symptoms may be very similar. Diagnosis is usually based on clinical observation often with the assistance of family medical history so that it can be understood whether transmission is autosomal dominant or recessive. Current classification of ectodermal dysplasias is based on clinical features. Pure ectodermal dysplasias are manifested by defects in ectodermal structures alone, while other ectodermal dysplasia syndromes are defined by the combination of ectodermal defects in association with different anomalies.^{2,3}

The commonest ectodermal dysplasias are X-linked recessive hypohidrotic ectodermal dysplasia. Although few

ectodermal dysplasia syndromes have a known genetic etiology, the number of ectodermal dysplasia syndromes with an identifiable genetic basis is increasing. In 2009, 64 genes and 3 chromosomal loci were associated with 62 ectodermal dysplasias. To date, more than 192 distinct disorders have been documented in literature.⁴

Ectodermal dysplasias are described as "heritable conditions in which there are abnormalities of two or more ectodermal structures such as the hair, teeth, nails, sweat glands, salivary glands, cranio-facial structure, digits and other parts of the body. These results are from the abnormal morphogenesis of cutaneous or mucosal ectoderm (hair, nails, teeth, eccrine glands). In some types, mesodermal abnormalities are also present.⁵

Ectodermal dysplasias can occur in any race but are much more prevalent in caucasians than any other group and especially in fair caucasians.¹ Ectodermal dysplasia rarely occurs in this region. We hereby present a case of 16-year boy who was normal at birth but subsequently developed features suggestive of this rare syndrome.

* Corresponding author.

E-mail address: drnitesh@gmail.com (N. Mohan).

2. Case History

A 16 year old male child presented to us with complaints of decreased sweating and itching all over skin specially when exposed to sun. When examined, the patient had sparse hair over the scalp [Figure 1], hypodontia [Figure 2] and loss of hair over eyelashes and eyebrows, i.e. madarosis. [Figure 3] Hair loss was progressive but skin itching remained almost constant and increased slightly during dry hot weather. He had history of decreased sweating. Cutaneous examination showed lusterless, short and sparse scalp hair along with madarosis. There was frontal bossing, nasal tip sweating and a hypopigmented patch near his right eye brow [Figure 4]. Palms and soles presented hyperhidrosis and mild palmo-plantar keratoderma [Figure 5]. Dental examination revealed hypodontia of lower incisors, abnormal canines and delayed persistence of deciduas teeth. Nails were slightly spooning (koilonychia) with anonychia and dystrophy seen in some of his nails.

His routine investigations, cardiac monitoring and skiagram chest were normal. Skin biopsy was done and histopathology showed epidermal hyperplasia, dyskeratosis, along with reduction in the number of sweat glands, hair follicles and sebaceous glands [Figures 6 and 7]. Due to economic constraints genetic studies were not carried out. Based on the spectrum of clinical features, a diagnosis of ectodermal dysplasia was made. Parents were counselled about the benign nature of the disease, proper skin care and regular follow up was also advised.

Child was result of a non-consanguineous marriage with uneventful antenatal history. His developmental milestones were normal. In child's family, his other two siblings had similar symptoms, one of which expired in her teenage.

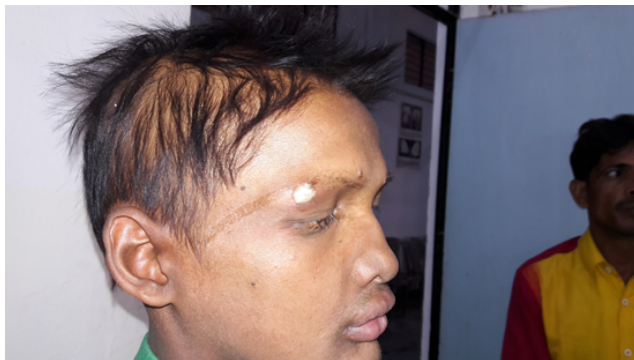

Fig. 1: Picture showing sparse hair over the scalp

3. Discussion

Ectodermal dysplasia is a group of signs and symptoms all derived from abnormalities of the ectodermal layer. More than 150 different types have been identified till date.²

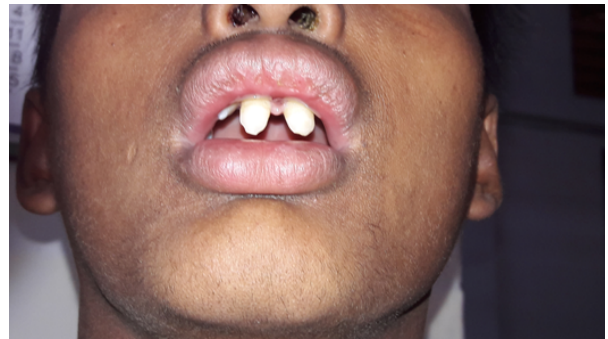

Fig. 2: Picture showing hypodontia

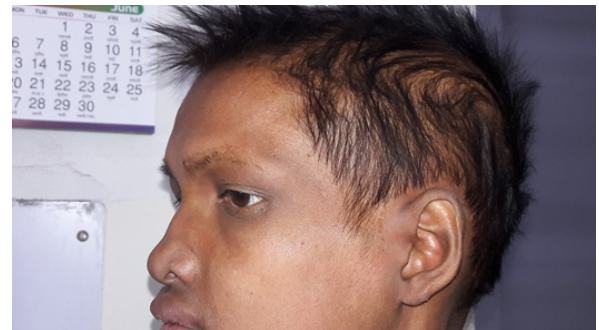

Fig. 3: Picture showing loss of eyelashes & eyebrows, i.e. madarosis

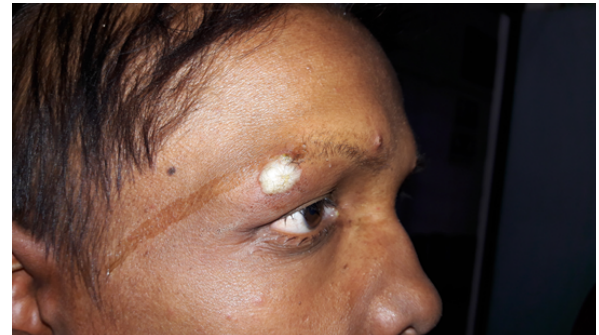

Fig. 4: Picture showing frontal bossing and hypopigmented patch

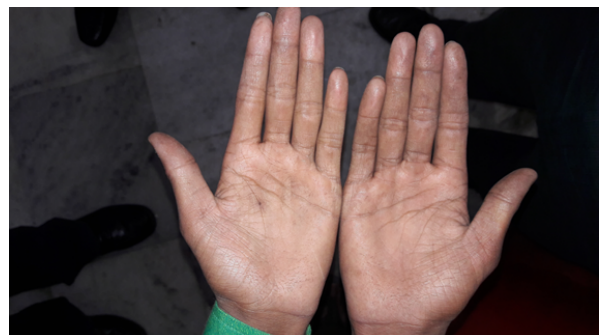

Fig. 5: Palms showing hyperhidrosis and mild keratoderma

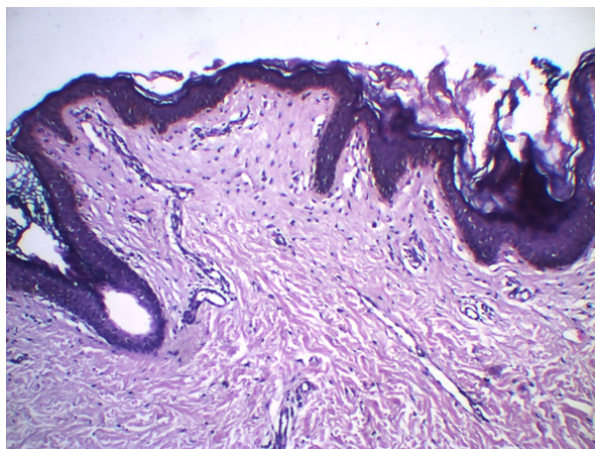


Fig. 6: Section of skin showing dyskeratosis (H&E Stain x400)

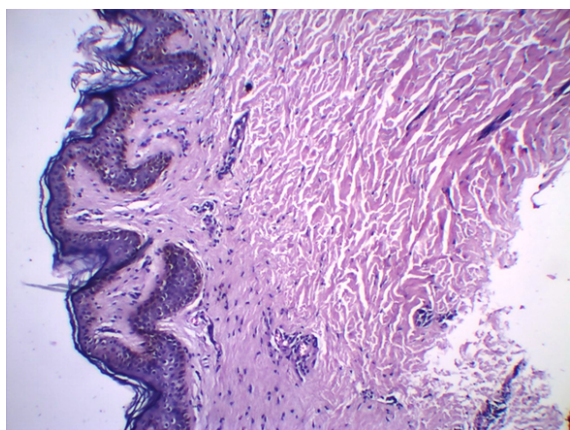


Fig. 7: Section showing reduced hair follicles and sebaceous glands (H&E Stain x400)

Despite some of the syndromes having different genetic causes the clinical presentation and symptoms are sometimes very similar. Diagnosis is usually clinical with assistance of family medical history to determine whether transmission is autosomal dominant or recessive. Ectodermal dysplasia is often defined in three major groups of anhydrotic (Christ-Siemens-Touraine syndrome), hypohydrotic and hydrotic (Clouston syndrome). Anhydrotic ectodermal dysplasia is characterized by autosomal recessive transfer and absence of sweat and adipose tissue. These findings are partially seen in milder form in the hypohydrotic type. In the hydrotic type, which is transferred as autosomal dominant, the sweat and adipose glands are normally formed.⁵⁻⁸

Although Thurnam published the first report of a patient with ectodermal dysplasia in 1848, the term ectodermal dysplasia was coined by Weech in 1929.⁹

Freire-Maia and Pinheiro proposed the first classification system of ectodermal dysplasias in 1982,¹⁰ with additional updates in 1994 and 2001. Their original classification

system classified the ectodermal dysplasias into different subgroups according to the presence or absence of (1) hair anomalies or trichodysplasias, (2) dental abnormalities, (3) nail abnormalities or onychodysplasias, and (4) eccrine gland dysfunction or dyshidrosis.^{2,3,10}

Worldwide around 7,000 people have been diagnosed with an ectodermal dysplasia condition. In United states, the frequency in general population is highly variable. The prevalence of hypohydrotic ectodermal dysplasia, commonest variant, is estimated to be 1 case per 100,000 births, while the prevalence of ectodermal dysplasia is estimated at 7 cases per 10,000 births globally.

Some ED conditions are only present in single family units and derive from very recent mutations. Ectodermal dysplasias can occur in any race but are much more prevalent in fair caucasians. Clinical identification varies from birth to childhood depending on the severity of symptoms and the recognition of associated complications. Many patients are not diagnosed until infancy or childhood, when dental anomalies, nail abnormalities, or alopecia become apparent.⁵

Abnormalities of two or more ectodermal structures such as the hair, teeth, nails, sweat glands, salivary glands, cranio-facial structure, digits and other parts of the body are seen.¹¹ Characteristic features include the following:

1. Hair defects: A reduction in the number of hair follicles in conjunction with structural hair shaft abnormalities may be seen. Structural hair shaft abnormalities may result from aberrations in hair bulb formation and include longitudinal grooving, hair shaft torsion, and cuticle ruffling. Hair bulbs may be distorted, bifid or small.¹¹
2. Eccrine defects: Eccrine sweat glands may be absent or sparse and rudimentary, particularly in patients with hypohydrotic ectodermal dysplasia.¹¹
3. Other secretory gland defects: Hypoplasia of the salivary, sebaceous, and lacrimal glands may occur. In some patients, mucous glands may be absent in the upper respiratory tract and in the bronchi, esophagus, and duodenum.
4. Dental defects: Abnormal morphogenesis or absence of teeth as well as enamel defects may occur.⁵
5. Nail dystrophy: Abnormal nail plate formation may result in brittle, thin, ridged, or grossly deformed nails.

There are now several recognised, different types with distinct genetic causes^{2,4} like TP63 associated EEC syndrome, Rapp-Hodgkin syndrome and Hay-Wells syndrome, EDA, EDAR, and EDARADD associated Hypohydrotic ectodermal dysplasia, PVRL1 associated Margarita Island ectodermal dysplasia, PKP1 associated Ectodermal dysplasia with skin fragility, GJB6 associated Clouston's hydrotic ectodermal dysplasia, KRT14 associated Naegeli syndrome/Dermatopathia pigmentosa reticularis,

multiple keratins causing Pachyonychia congenita, PORCN associated Focal dermal hypoplasia, EVC associated Ellis–van Creveld syndrome and conditions involving selectively hands & feet are seen in Palmoplantar ectodermal dysplasia.

Diagnosis is usually based on clinical features. Doctors assess all the ectodermal structures and then try to match the set of abnormalities to those previously identified in other individuals. Sometimes this is very difficult and a precise diagnosis is not always made.

In general, laboratory studies are not useful in the diagnosis or management of the ectodermal dysplasias. Patients with ectodermal dysplasia associated with immunodeficiency may have hypogammaglobulinemia with impaired lymphocyte proliferation and cell-mediated immunity. An appropriate evaluation, including determination of quantitative immunoglobulin levels and T-cell subset populations, may be performed in such cases to reach the diagnosis.¹²

Orthopantomography is done if hypodontia or dental abnormalities are present. X-ray films of hands, feet, or both may be done to demonstrate specific skeletal deformities. Renal ultrasonography, voiding cystourethrography, and intravenous pyelography may be helpful in evaluating children with ectodermal dysplasia in association with cleft lip or palate for underlying genitourinary tract anomalies.¹³

Skin biopsy is useful in majority of cases. Histopathological findings include epidermal hyperplasia with cell-cell separation that varies from widening of intercellular spaces to severe acantholysis in the stratum spinosum. Aggregation of keratin filaments (e.g. dyskeratosis) is also reported. A reduction in the number of sweat glands, hair follicles, and sebaceous glands is associated with the different ectodermal dysplasias. In EDA, the epidermis is thin and flattened. Eccrine sweat glands are few and poorly developed or are rudimentary. Beyond the skin, mucous glands in the upper respiratory tract and bronchi are often decreased in number. Salivary glands may show ectasia of ducts and inflammatory changes.¹⁴

For the specific subtyping of ectodermal dysplasia in which the abnormal gene is known, it is possible to screen DNA to find the specific genetic mutation in affected individuals.

3.1. Medical care

The care of affected patients depends on which ectodermal structures are involved. For patients with anhidrosis/hypohidrosis, advise air conditioning for home, school, and work. Encourage frequent consumption of cool liquids to maintain adequate hydration and thermoregulation. Also, advise patients to wear loose cotton clothing.

For patients with dental defects, advise early dental evaluation and intervention and encourage regular dental hygiene. An international consensus meeting of experts in pediatric dentistry, orthodontics, and prosthodontics has published recommendations for the diagnosis, evaluation, and treatment of patients with ectodermal dysplasia, including use of dental implants. Advise orthodontic treatment for cosmetic reasons and to ensure adequate nutritional intake.¹⁵

Patients with xerosis or eczematous dermatitis may benefit from the use of topical emollients. Patients with severe alopecia can wear wigs to improve their appearance. Use of topical minoxidil with or without a topical tretinoin has been shown to improve hair growth in some patients. Patients with scalp erosions are treated with topical and systemic antibiotics. General scalp care may involve the use of weekly dilute bleach or acetic acid soaks to minimize bacterial colonization in scalp. Application of special scalp dressings may be helpful.

Use of artificial tears to prevent damage to the cornea in patients with reduced lacrimation is advisable.

Nasal mucosa is protected with saline drops followed by the application of petrolatum jelly.

Patients with ectodermal dysplasia with compromised immune status are monitored for infection and treated with therapeutic and prophylactic antibiotics when required.¹⁶

Allogeneic stem cell transplantation has been performed in a small number of patients with autosomal dominant ectodermal dysplasia with immunodeficiency (EDA-ID); poor engraftment and post-transplant complications.

3.2. Surgical care

Early repair of cleft lip or palate may lessen facial deformities and improve speech. Other midfacial defects or hand/foot deformities may be surgically corrected in order to improve function and reduce physical disfigurement.^{16,17}

4. Conclusion

Ectodermal dysplasia is a heterogeneous group of hereditary malformations and irregularities which have similar findings. Congenital malformations are commonly seen in teeth, hair, nails and sweat glands.

This syndrome not only creates tissue malformations but the quality of life of patients is also affected. Ectodermal dysplasia may present with delayed onset and cheilitis, can be absent in skin fragility syndrome. As there are only few cases reported with varied clinical profile, further genetic studies are needed to establish exact pathogenesis in this rare syndrome.

5. Source of Funding

No financial support was received for the work within this manuscript.

6. Conflict of Interest

The authors declare they have no conflict of interest.

References

1. J W, B T, D E. Andrews' Diseases of the Skin: Clinical Dermatology. In: 10th Edn. Saunders; 2005.
2. Pinheiro M, Freire-Maia N. Ectodermal dysplasias: a clinical classification and a causal review. *Am J Med Genet*. 1994;53(2):153–62. doi:10.1002/ajmg.1320530207.
3. Freire-Maia N, Lisboa-Costa T, Pagnan N. Ectodermal dysplasias: How many? *Am J Med Genet*. 2001;104(1):84. doi:10.1002/ajmg.1586.
4. Visinoni A, Lisboa-Costa T, Pagnan NAB, Chautard-Freire-Maia EA. Ectodermal dysplasias: Clinical and molecular review. *Am J Med Genet Part A*. 2009;149A(9):1980–2002. doi:10.1002/ajmg.a.32864.
5. Doğan MS, Callea M, Yavuz İ. An evaluation of clinical, radiological and three-dimensional dental tomography findings in ectodermal dysplasia cases. *Med Oral, Patol Oral Cirugía Bucal*. 2015;20:340–6.
6. Yavuz I, Baskan Z, Ulku R, Dulgergil TC, Dari O, Ece A, et al. Ectodermal Dysplasia: Retrospective Study of Fifteen Cases. *Arch Med Res*. 2006;37(3):403–9. doi:10.1016/j.arcmed.2005.06.016.
7. Callea M, Teggi R, Yavuz I, Tadini G, Priolo M, Crovella S, et al. Ear nose throat manifestations in hypoidrotic ectodermal dysplasia. *Int J Pediatr Otorhinolaryngol*. 2013;77(11):1801–4. doi:10.1016/j.ijporl.2013.09.004.
8. Yoshioka T, Nishikomori R, Hara J, Okada K, Hashii Y, Okafuji I, et al. Autosomal Dominant Anhidrotic Ectodermal Dysplasia with Immunodeficiency Caused by a Novel NFKBIA Mutation, p.Ser36Tyr, Presents with Mild Ectodermal Dysplasia and Non-Infectious Systemic Inflammation. *J Clin Immunol*. 2013;33(7):1165–74. doi:10.1007/s10875-013-9924-z.
9. Weech AA. HEREDITARY ECTODERMAL DYSPLASIA (CONGENITAL ECTODERMAL DEFECT). *Am J Dis Child*. 1929;37(4):766–90. doi:10.1001/archpedi.1929.01930040075005.
10. Pinheiro M. The ectodermal dysplasias. *Arch Dermatol*. 1982;118:215–6. doi:10.1001/archderm.118.4.215.
11. Miyake T, Kiniwa Y, Kosho T, Nakano H, Okuyama R. Hypohidrotic ectodermal dysplasia: A report of two cases. *Dermatol*. 2016;doi:10.1111/1346-8138.13479.
12. Giampietro PF, Baker MW, Basehore MJ, Jones JR, Seroogy CM. Novel mutation in TP63 associated with ectrodactyly ectodermal dysplasia and clefting syndrome and T cell lymphopenia. *Am J Med Genet Part A*. 2013;161(6):1432–5. doi:10.1002/ajmg.a.35885.
13. Motil KJ. Growth Characteristics of Children With Ectodermal Dysplasia Syndromes. *Pediatr*. 2005;116(2):e229–34. doi:10.1542/peds.2004-2830.
14. Fosko SW, Stenn KS, Bologna JL. Ectodermal dysplasias associated with clefting: significance of scalp dermatitis. *J Am Acad Dermatol*. 1927;(2):249–56.
15. Klineberg I, Cameron A, Hobkirk J, Bergendal B, Maniere MC, King N, et al. Rehabilitation of Children with Ectodermal Dysplasia. Part 2: An International Consensus Meeting. *Int J Oral Maxillofac Implants*. 2013;28(4):1101–9. doi:10.11607/jomi.2981.
16. Lee HE, Chang IK, Im M, Seo YJ, Lee JH, Lee Y, et al. Topical minoxidil treatment for congenital alopecia in hypohidrotic ectodermal dysplasia. *J Am Acad Dermatol*. 2013;68(4):139–40.
17. Kashyap S, Shanker V, Sharma N. Ectodermal dysplasia-skin fragility syndrome: A rare case report. *Indian J Dermatol*. 2015;60(4):421. doi:10.4103/0019-5154.160525.

Author biography

Nitesh Mohan, Professor

P. K. Rathore, Professor & Head

Cite this article: Mohan N, Rathore PK. Ectodermal dysplasia with classical clinical presentation: A rare case report. *IP J Diagn Pathol Oncol* 2020;5(4):441-445.