



Case Report

A rare case report of mucinous adenocarcinoma arising in sacrococcygeal teratoma in an adult patient and brief review

Jyoti Parag Dekate^{1,*}, Manjula Vijayanand Kelkeri¹

¹Dept. of Histopathology, Gleneagles Global hospital, Hyderabad, Telangana, India



ARTICLE INFO

Article history:

Received 09-07-2020

Accepted 23-07-2020

Available online 03-09-2020

Keywords:

Teratoma

Sarcococcygeal

Mucinous adenocarcinoma

Adult

ABSTRACT

Sarcococcygeal teratoma is the most common congenital tumor with relatively uncommon incidence in adult population. Somatic malignancy arising in sacrococcygeal teratoma is a rare phenomena arising in long standing cases. Association with mucinous adenocarcinoma is extremely rare with only few case reports in the published literature. We herein report a case of mucinous adenocarcinoma arising in a background of sacrococcygeal teratoma with emphasis on the clinico pathological profile and post operative management of such cases.

Key Messages: Somatic malignancy such as Mucinous adenocarcinoma are rarely associated with Sarcococcygeal teratoma. Adequate histopathologic sampling and microscopy is essential to clinch the diagnosis for post operative management of these patients which subsequently have a tremendous impact on patient outcome.

© 2020 Published by Innovative Publication. This is an open access article under the CC BY-NC license (<https://creativecommons.org/licenses/by-nc/4.0/>)

1. Introduction

Teratomas are common neoplasm derived from 2 or more germ cell derivatives. Commonly involved sites are ovaries, followed by testis, anterior mediastinum, retroperitoneum and sacrococcygeal area.¹ Sacrococcygeal teratoma comprises the most common congenital tumor in the neonatal group with female predilection; male to female ratio being 4:1. Its incidence in adult population is relatively uncommon. Malignant transformation is a rare phenomena noted in just 1-3% of cases. Somatic malignancies usually arises in long standing cases. Mucinous neoplasm in sacrococcygeal teratoma are rarely reported with a handful of cases described in the literature.

2. Case History

A 62 years male, a known case of CMML status post six cycles of chemotherapy presented with lower back pain radiating to the abdomen. Physical examination revealed

10x12cm swelling in the sacral region with ill-defined margins and was soft in consistency. The overlying skin was red and tender. Radiologic investigations were carried out. CT abdomen revealed a large well defined multiloculated cystic Space occupying lesion in the presacral area shwing separte and calcific foci.

Surgical exploration and excision of tumor was planned. Per-operatively, the presacral tumor was found extending into subcutaneous plane. The tumor was cystic lying close to the posterior wall of rectum and coccyx. The resected specimen was sent for histopathological examination.

Gross examination showed excision specimen covered by elliptical skin cover. Beneath the sub-cutis, collapsed cyst wall was identified grossly measuring 5.8cm with abundant mucinous jelly like material in the container. Representative sections examined from the cyst wall shows haphazardly arranged fibro-osseous tissue admixed with adipose tissue and fibroconnective elements. Foci of well-formed marrow spaces with hematopoietic elements were also noted amidst the fibroconnective tissue. (Figure 2) Neuroglial tissue or immature cells were not identified. Additionally, in few of the section, a mucinous neoplasm was seen composed

* Corresponding author.

E-mail address: dekatejyoti84@gmail.com (J. P. Dekate).

of neoplastic glands arranged in villo-glandular pattern with areas of infiltration in the underlying stroma. Pools of extracellular mucin were also noted. Serum tumor markers in cases of sacrococcygeal teratoma can help in differentiating mature, immature and malignant teratomas. Somatic malignancies especially mucinous adenocarcinoma pre-operatively may be suspected by elevated serum levels of CEA and CA19.9.

In our case, due to radiological suspicion of infected dermoid cyst, the pre-operative serum tumor levels were not done and surgical excision was planned. The patient received adjuvant therapy and is disease free at postoperative interval of one year.

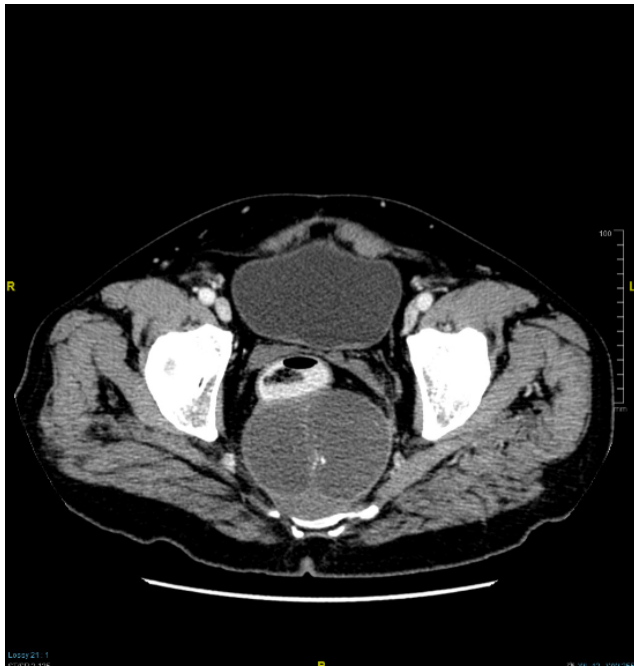


Fig. 1: CT ABDOMEN.mucin,enhancing soft tissue post.Se107.Img1

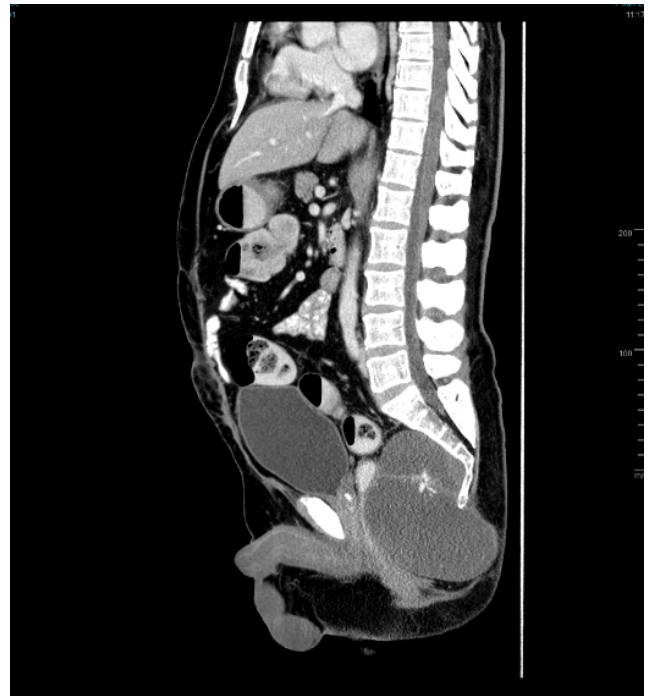

Fig. 2: CT ABDOMEN. presacral mass.Se106.Img1

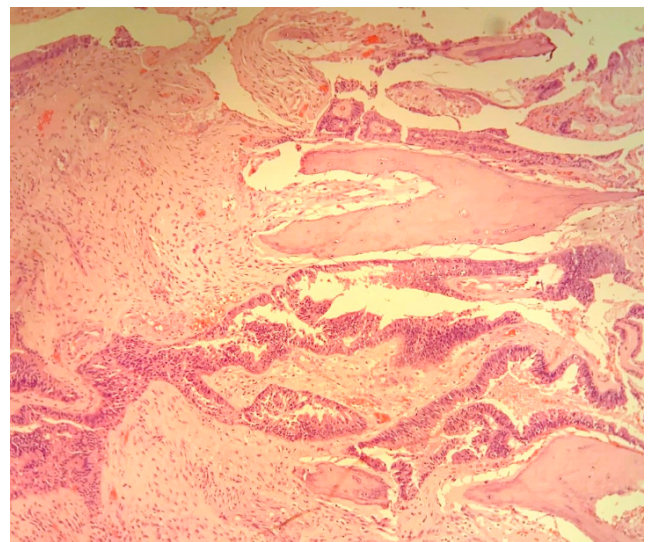


Fig. 3:

3. Discussion

Teratoma are common neoplasm seen in almost all age groups both at gonadal and extragonadal sites, the common sites being involved are ovaries, testes, mediastinum, retroperitoneum and sacrococcygeal area.1) These tumors are composed of at least two primordial germ cell derivatives - ectoderm, mesoderm and endoderm. Malignancies in teratoma may involve the embryonic or somatic components with a low incidence rate of 1-3% both in gonadal and extragonadal sites.²

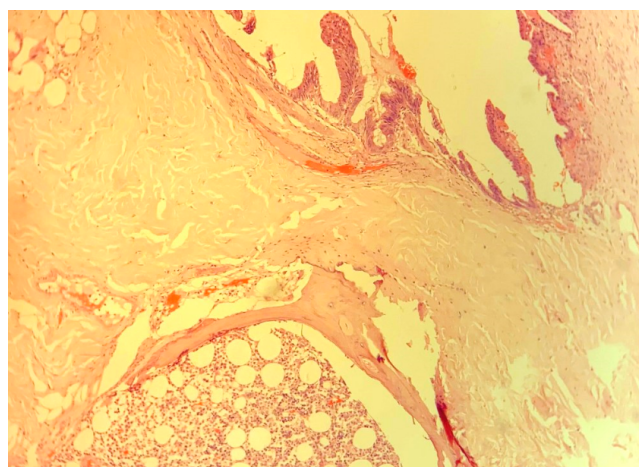
Sacrococcygeal teratoma though represents the most common congenital tumor in neonatal group, Its occurrence in adult age group is uncommon with low incidence of about 10% with predilection for male sex male to female ratio being 4:1.³ Almost 90% of these tumors are detected in

neonatal period due to visible mass, in adults they are mostly radiological evaluation for clinical symptoms like pelvic pain, low back pain, or symptoms related to compression of the adjacent organs like frequent urination, tenesmus, constipation etc. The case presented here was detected while being evaluated for lower back and abdominal pain.

Depending on the tumor extension the sacrococcygeal tumors are divided into three types. Type I SCT have minimal presacral component with predominant external

Table 1: Clinicopathologic profile of reported cases

Author	Age	Sex	Clinical symptoms	Size	Tumor markers	Histologic type	Follow-up period	Outcome
Ozgur et al. 2015	76y	M	Low back pain, pelvic pain	7cm	Normal levels	Mucinous adenoca	10 months	Alive, adjuvant therapy
Zhang et al. 2017	39y	F	Difficult micturition, defecation, tumor since birth	15.6cmx12.2x30cm	Normal levels	Mucinous tumor	33days	Discharge No adjuvant therapy
Zhou et al. 2019	26y	F	Abdomen distension, difficult micturition	96x114x89mm	High CEA and CA724	Signet ring cell carcinoma	-	Chemotherapy
Dokmei et al. 2020	44y	F	Backache, constipation, weight loss	15cm	-	Mucinous adenoca	-	-
Present study	62y	M	Low back pain and pelvic pain	13.5x9.5x8.3cm	-	Mucinous adenoca	-	Alive, on adjuvant therapy

**Fig. 4:**

component; Type II tumors are also predominantly external with definitive intra-abdominal extensions; Type III tumors are located mostly in abdomen or comprises of a dominant pelvic mass extending into abdomen with a small external component; and type IV are entirely in presacral region with no external component.^{3–5} This classification helps in planning the surgical procedure. In our case, the mass was entirely located in presacral component with extension into subcutaneous plane, hence wide excision with overlying skin was performed.

Malignant transformation in sacrococcygeal teratoma is rarely reported with only a few case reports described in the literature^{6–8} Table 1. In all these cases, malignancy was not suspected clinically and was only detected by thorough histopathological examination similar to our case. Various age groups are involved from second to seventh decade with slight female predominance.

4. Source of Funding

None.

5. Conflict of Interest

None.

References

- Sasi W, Ricchetti GA, Parvanta L, Carpenter R. Giant Mature Primary Retroperitoneal Teratoma in a Young Adult: Report of a Rare Case and Literature Review. *Case Rep Surg*. 2014;2014:1–5.
- Genadry R, Parmley T, Woodruff JD. Secondary malignancies in benign cystic teratomas. *Gynecol Oncol*. 1979;8(2):246–51.
- Ghosh J, Eglinton T, Frizelle FA, Watson AJM. Presacral tumours in adults. *Surg*. 2007;5(1):31–8.
- Altman RP, Randolph JG, Lilly JR. Sacrococcygeal teratoma: American Academy of Pediatrics Surgical Section survey—1973. *J Pediatr Surg*. 1974;9(3):389–98.
- Schropp KP, Lobe TE, Rao B, Mutabagani K, Kay GA, Gilchrist BF, et al. Sacrococcygeal teratoma: The experience of four decades. *J Pediatr Surg*. 1992;27(8):1075–8.
- Zhang F, Yu X, Zeng J, Dai M. Mucinous tumor arising in a giant sacrococcygeal teratoma. *Med*. 2017;96(47):e8759.
- Dokmei AM, Dilley J, Singh N, Jeyarajah A. Sacrococcygeal teratoma in an adult containing a mucinous adenocarcinoma. *BMJ Case Rep*. 2020;13(2):e233308.
- Zhou P, Liu S, Yang H, Jiang Y, Liu X, Liu D, et al. Signet ring cell carcinoma arising from sacrococcygeal teratoma: a case report and review of the literature. *J Int Med Res*. 2019;47(5):2234–9.

Author biography

Jyoti Parag Dekate Consultant

Manjula Vijayanand Kelkeri Consultant

Cite this article: Dekate JP, Kelkeri MV. A rare case report of mucinous adenocarcinoma arising in sacrococcygeal teratoma in an adult patient and brief review. *IP J Diagn Pathol Oncol* 2020;5(3):330–332.