



## Original Research Article

# Utility of Immunohistochemical Expression of Ki-67 in Liver Cirrhosis and Hepatocellular Carcinoma

Shivani Iyyappan<sup>1</sup>, Barathi G<sup>2,\*</sup><sup>1</sup>Sri Ramachandra Institute of Higher Education and Research, Chennai, Tamil Nadu, India<sup>2</sup>Dept. of Pathology, Sri Ramachandra Institute of Higher Education and Research, Chennai, Tamil Nadu, India

## ARTICLE INFO

## Article history:

Received 01-08-2020

Accepted 11-08-2020

Available online 03-09-2020

## Keywords:

Ki-67

Liver cirrhosis

Hepatocellular carcinoma

## ABSTRACT

**Background:** Hepatocellular carcinoma is a primary malignancy of the liver and occurs predominantly in patients with underlying chronic liver disease and cirrhosis. The incidence of hepatocellular carcinoma is highest in Asia and Africa, where there is higher predisposition to chronic liver disease and subsequent development of hepatocellular carcinoma. The most widely used proliferation-associated marker is Ki-67, which is a nuclear antigen present only in proliferating cells.

**Aim:** To study the immunohistochemical expression of Ki-67 in liver cirrhosis and hepatocellular carcinoma and its association to the progression of cirrhosis to hepatocellular carcinoma.

**Materials and Methods:** This is a retrospective study conducted on estimated sample size of 26 formalin fixed paraffin embedded tissue blocks of histopathology proven liver cirrhosis/ hepatocellular carcinoma specimens received in the Department of Pathology at a tertiary care center. The immunohistochemical markers are used to evaluate Ki-67 levels in these specimens.

**Results:** Ki-67 expression was positive in 20% of cirrhotic specimens and 66% of hepatocellular carcinoma patients.

**Conclusion:** There may be a possible relationship between Ki-67 expression and changes of the liver from cirrhosis to hepatocellular carcinoma. The Ki-67 antigen expression was relatively low in cirrhosis and high in hepatocellular carcinoma, the increased expression indicating the neoplastic growth. Further studies are required for quantification of such association to be used for diagnostic and prognostic significance.

© 2020 Published by Innovative Publication. This is an open access article under the CC BY-NC license (<https://creativecommons.org/licenses/by-nc/4.0/>)

## 1. Introduction

Hepatocellular carcinoma (HCC) is a primary malignancy of the liver and occurs predominantly in patients with underlying chronic liver disease and cirrhosis. Hepatocellular carcinoma is now the fourth leading cause of cancer deaths worldwide.<sup>1</sup> The incidence of hepatocellular carcinoma is highest in Asia and Africa, where there is higher predisposition to the development of chronic liver disease and possibility of subsequent progression to hepatocellular carcinoma. The highest incidence of hepatocellular carcinoma in these regions is attributed to cirrhosis.<sup>2</sup> Cirrhosis is a morphological change associated

with chronic liver diseases characterized by fibrous bands containing regenerative nodules of hepatocytes. It usually forms the background of hepatocellular carcinoma.

Ki-67 is a proliferation marker used in general to determine the aggressiveness of various malignancies and used in tumor grading especially in sarcomas. In carcinomas Ki-67 Immunohistochemistry (IHC) is used widely in breast carcinomas for molecular subtyping and central nervous system tumors for grading. Ki-67 is present exclusively in the nucleus of proliferating cells during interphase of the cell cycle.<sup>3</sup> In HCC, Ki-67 expression was found to be in close relation to tumor growth rate and was an independent prognostic indicator of patient disease-free and overall survival rates.<sup>4,5</sup> Aim of this study is to determine the usefulness of the immunohistochemical expression of

\* Corresponding author.

E-mail address: [gbarathi@gmail.com](mailto:gbarathi@gmail.com) (Barathi G).

Ki-67 in liver cirrhosis and hepatocellular carcinoma and analyze the correlation of ki-67 with the progression from cirrhosis to hepatocellular carcinoma.

## 2. Materials and Methods

This is a retrospective study conducted on sample size of 26 formalin fixed paraffin embedded tissue blocks of histopathology proven liver cirrhosis/ hepatocellular carcinoma specimens received in the Department of Pathology at a tertiary care centre from January 2017 to June 2019. The immunohistochemical markers are used to evaluate Ki-67 levels in these specimens. Ki-67 labelling index was defined as the proportion (%) of the immunohistochemically positive-stained nuclei of the 500 measured nuclei.

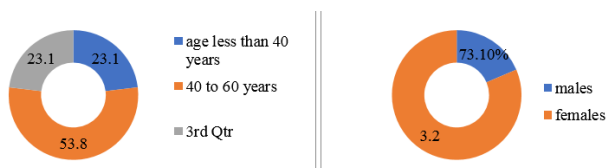
Thin paraffin sections of 5  $\mu$ m thickness is prepared in poly-l-lysine coated slide and dried at 60 °C for 1 hour (or) incubated at 37°C for overnight. The sections were dewaxed in xylene and treated with buffers. It is then treated with peroxide for 5 mins and incubated with power block for 10 mins at room temperature. Monoclonal antibody to Ki-67 was applied for 60 mins at 30 degree Celsius. All the fields of the biopsy specimen was analyzed and the expression of Ki-67 is indicated by strong immunoreactive 3+ intense positivity of the nuclei.

Statistical Analysis was performed using the SPSS 16 software. Quantitative data was expressed by mean and the standard deviation. Difference between means was determined by non-parametric tests including Kruskal-Willis Test and t test or Mann whitney 'U'test. Qualitative data was expressed in percentage with appropriate confidence interval. Difference between proportions was assessed by chi square test. P value < 0.05 was considered significant.

## 3. Results

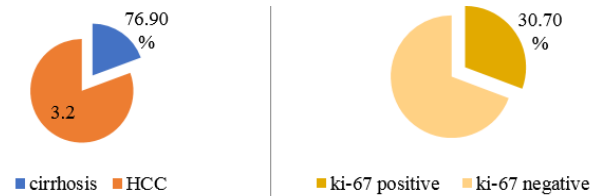
### 3.1. Demographic profile

The data collected showed a great diversity. The age of the patients ranging from 5 to 69 years. There was one case of cirrhosis at the age of 5 with a condition of congenital cholestasis. 23.1% of the patients fall under the age group of less than 40, 53.8% patients are in the age group of 40 to 60 and 23.1% of the patients fall under the age group of greater than 60. There were 19 (73.1%) males and 7 (26.9%) females as a part of this study.



### 3.2. Pathological profile

Out of the 26 specimens, 20 specimens were histologically proven cirrhosis cases and 6 specimens were histological proven hepatocellular carcinoma cases. Only 3 of the cases had positivity for viral markers, 2 (7.7%) for HBV and 1(3.8%) for HCV. The 2 cases positive for HBV were of hepatocellular carcinoma. The HCV was positive in case of cirrhosis.



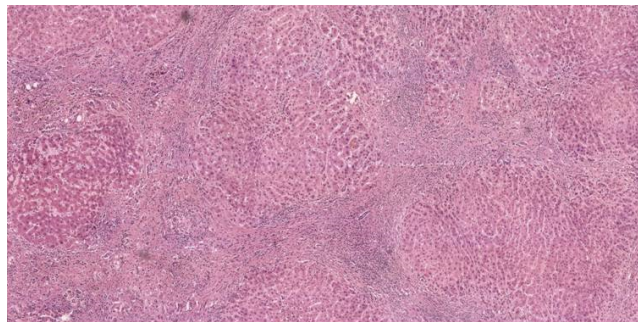
### 3.3. Ki-67 expression profile

The proliferation marker Ki-67 was expressed in 8 specimens. Ki-67 labeling index (LI) was in range 2-30. Ki-67 was positive in 4(20%) cases of cirrhosis and 4(66.7%) cases of hepatocellular carcinoma. (Figure:1) The ki-67 LI was around 2-4 in cirrhotic specimens whereas the same was in the range of 2-30 in cases of hepatocellular carcinoma. Majority (50%) of the cases which showed Ki-67 positivity were in the age group of less than 40 years. While 28.6% and 16.7% of the Ki-67 positive cases belong to the age group of 40-60 years and greater than 60 years respectively. While 57.1% of the Ki-67 positive cases were females only 21.1% of the Ki-67 positive cases were males.

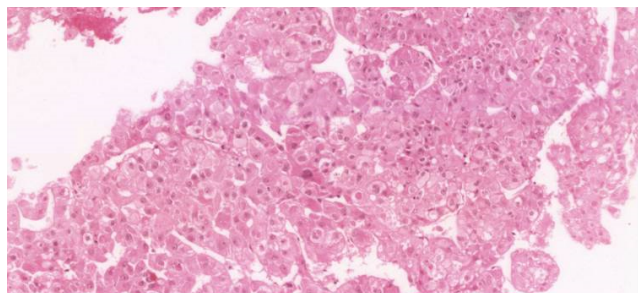
The Ki-67 LI was also interpreted in the non-cirrhotic normal liver tissue included in the bits given adjacent to but away from the tumor. Mean and standard deviation of the Ki-67 LI was calculated in the similar way as done for the cirrhosis and HCC areas. We observed that Ki-67 which was negative in the cases of both cirrhosis and HCC, were also totally negative for ki-67 in the normal hepatic parenchyma adjacent to the lesion of interest. Also we noted that when comparing the ki-67 expression of normal tissue, cirrhosis and HCC there was an increase in expression by percentage of cells positive for Ki-67 in tumor obviously than the cirrhosis and normal tissue. But statistically the p value is > 0.05 in all.

## 4. Discussion

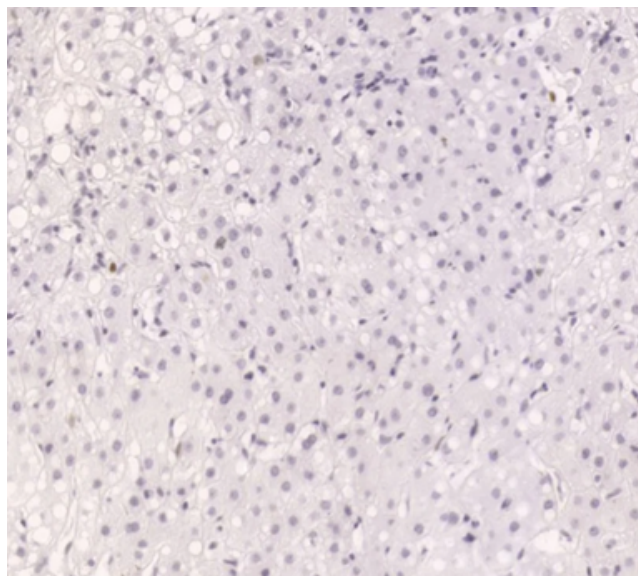
Cirrhosis of the liver causes architectural distortion though the bridging fibrous septae and hepatic necrosis with simultaneous formation of regenerative nodules. There are various etiological factors for development of chronic liver disease having cirrhotic histology. They can be due to alcohol, viral infections, autoimmune conditions, drug or toxin, inherited metabolic disorders or cholestatic syndromes. Under the event of injury due to the above



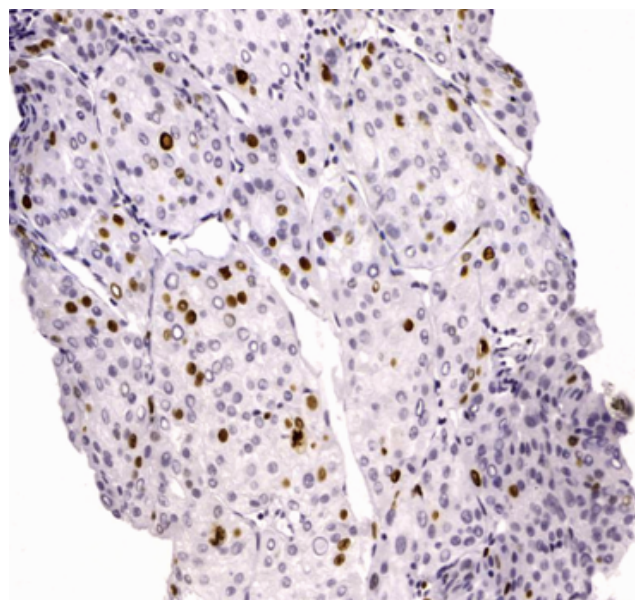
**Fig. 1:** Cirrhotic nodules of varying sizes H&E X 100



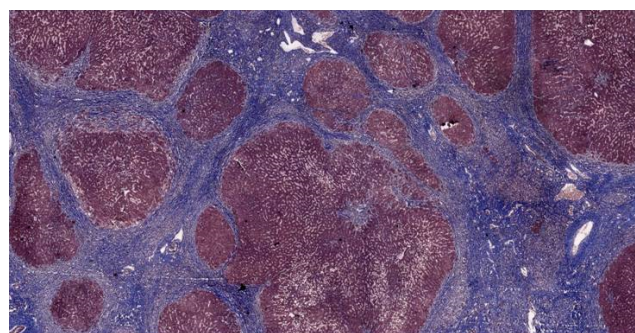
**Fig. 2:** Core biopsy from the hepatocellular carcinoma X 400



**Fig. 3:** IHC for Ki-67 negative in HCC X 400



**Fig. 4:** IHC for Ki-67 positive in HCC X 400



**Fig. 5:** MassonTrichrome stain highlighting the nodules X 40

mentioned causes, collagen deposition leading to loss of sinusoidal endothelial fenestrations hampering with the homeostasis and causes hepatocyte death.<sup>6</sup> Stem cell activation and differentiation giving rise to ductular reactions are prominent in cirrhosis. Errors in this rapid cell turnover could induce genetic alterations that in future may give rise to neoplastic growth. Regression of fibrosis may follow with remission or cure. Elements of progression and regression are dictated by the severity and persistence of the underlying disease.

Hepatocellular carcinoma shares its risk factors with that of cirrhosis. Dysplastic nodules associated with cirrhosis serve as potential precursors of hepatocellular carcinoma. Low grade dysplastic nodules indicates higher risk of hepatocellular carcinoma but high grade dysplastic nodules are perhaps the most important precursor of hepatocellular carcinoma.<sup>7</sup> Gain of function mutations in beta-catenin and loss of function mutations in p53 are the most common mutations involved as these makes the tumor insensitive to



growth inhibitory signals.<sup>8</sup> This form of sustained growth favors accumulation of more mutation.

Ki-67 is a proliferation marker, which is a nuclear antigen present only in proliferating cells during the G1, S, and G1–M phases but not during the G0 phase of the cell cycle. Its expression helps in assessing the hepatocytes ability to rapidly divide. As its usefulness is well established in many sarcomas and carcinomas in grading and prognostication the same has been tried in HCC to determine the utility of Ki-67 expression by IHC in explant/resected specimen of liver with cirrhosis background. It was observed in our study that low Ki-67 was expressed in cirrhosis as well as HCC with no significant statistical correlation was obtained with a p value of > 0.5 and hence a correlation of Ki-67 LI with disease progression from cirrhosis to HCC was not established. When compared to other studies we consider that nonperformance of panel of IHC markers P53 and Beta-catenin as a drawback of our study.

On evaluation of ki-67 expression with other parameters, there wasn't statistically significant correlation of ki-67 positivity with age, sex or viral hepatitis by HBV or HCV.<sup>9–14</sup> This was in concordance with the other studies reviewed. However there was increased expression among female patients although there were more males involved in this study than females. In this study it has been observed that only certain cases of cirrhosis and hepatocellular carcinoma have expressed this marker. This could be due to regression of cirrhosis or some undiscovered mutations responsible for hepatocellular carcinoma development.

Other markers like alpha fetoprotein, p53, PCNA have been used for similar interests. Perhaps an interpretation with multiple parameters for evaluation would yield more definitive results by compensating for the lack of expression of the other. Studies done have shown that cirrhosis with large cell dysplastic changes were negative for Ki-67 which could also be the case in our study. Further studies on the genetic mechanism and immunohistochemical studies on a larger population might provide a broader insight on the efficiency of use of Ki-67. Overall, there is substantial increase in Ki-67 labelling index from cirrhosis to hepatocellular carcinoma.<sup>15</sup> This proposes the potential of Ki-67 being used as a marker for quantification of risk of progression of cirrhosis to hepatocellular carcinoma. Studies have been done on usage of Ki-67 to predict recurrence in liver transplant which reinforces the idea that Ki-67 has a budding capacity to help analyze the prognosis and hence serve as both diagnostic and prognostic factor. However additional studies are required to validate the proposal.

## 5. Conclusion

To conclude there may be a possible relationship between Ki-67 expression and dysplastic changes of the liver from cirrhosis to hepatocellular carcinoma. The Ki-67

antigen expression is relatively low in cirrhosis and high in hepatocellular carcinoma, the increased expression indicating the neoplastic growth. Further studies on large sample size is required for exploring into the possibility of developing a quantification scale that could be used in predicting the risk of evolution of cirrhosis to hepatocellular carcinoma. This could be used as potential means to monitor the patients and look into early detection and treatment options for hepatocellular carcinoma.

## 6. Source of Funding

None.

## 7. Conflict of Interest

None.

## References

1. Rawla P, Sunkara T, Muralidharan P, Jeffrey Pradeep Raj. Update in global trends and aetiology of hepatocellular carcinoma. *Contemp Oncol (Pozn)*. 2018;22(3):141–50.
2. Zhu RX, Seto WK, Lai CL, Yuen MF. Epidemiology of Hepatocellular Carcinoma in the Asia-Pacific Region. *Gut Liver*. 2016;10(3):332–9.
3. Miller I, Min M, Yang C. Ki67 is a Graded Rather than a Binary Marker of Proliferation versus Quiescence. *Cell Rep*. 2018;24(5):1105–12.
4. Bai K, Cao Y, Huang Q, Jiang Y, Lv L. Prognostic Value of Ki67 Expression for Patients with Surgically Resected Hepatocellular Carcinoma: Perspectives from a High Incidence Area. *Clin Lab*. 2017;63(02):355–64.
5. King KL, Hwang JJ, Chau GY. Ki-67 expression as a prognostic marker in patients with hepatocellular carcinoma. *J Gastroenterol Hepatol*. 1998;13:273–9.
6. Natarajan V, Harris EN, Kidambi S. SECs (Sinusoidal Endothelial Cells), Liver Microenvironment, and Fibrosis. *Bio Med Res Int*. 2017;2017:1–9.
7. Choi JY, Lee JM, Sirlin CB. CT and MR Imaging Diagnosis and Staging of Hepatocellular Carcinoma: Part I. Development, Growth, and Spread: Key Pathologic and Imaging Aspects. *Radiol*. 2014;272(3):635–54.
8. Guzman G, Alagiozian-Angelova V, Layden-Almer JE, Layden TJ, Testa G, Benedetti E, et al. p53, Ki-67, and serum alpha feto-protein as predictors of hepatocellular carcinoma recurrence in liver transplant patients. *Mod Pathol*. 2005;18(11):1498–1503.
9. Koskinas J, Petraki K, Kavantzias N, Rapti I, Kountouras D, Hadziyannis S, et al. Hepatic expression of the proliferative marker Ki-67 and p53 protein in HBV or HCV cirrhosis in relation to dysplastic liver cell changes and hepatocellular carcinoma. *J Viral Hepat*. 2005;12(6):635–41.
10. Hegazy A, Nashwa A, Zaki, Seif NS, Abd-Wahab. Hepatic Expression of the Proliferative Marker Ki-67 and cell cycle p53 Protein in chronic hepatitis C (A histopathological and immunohistochemical study). *Egypt J Hosp Med*. 2011;42:1–11.
11. Mohamed WS, Omar MM, Khayri TM, Fakhri IM. Assessment of the Proliferative Marker Ki-67 and p53 Protein Expression in HBV- and HCV-related Hepatocellular Carcinoma Cases in Egypt. *Int J Health Sci*. 2008;2(1):27–34.
12. Luo Y, Ren F, Liu Y. Clinicopathological and prognostic significance of high Ki-67 labeling index in hepatocellular carcinoma patients: a meta-analysis. *Int J Clin Exp Med*. 2015;8(7):10235–47.
13. Makino Y, Shiraki K, Sugimoto K. Histological features of cirrhosis with hepatitis C virus for prediction of hepatocellular carcinoma development: a prospective study. *Anticancer Res*. 2000;20:3709–16.

14. Nakamura T, Hayama M, Sakai T, Hotchi M, Tanaka E. Proliferative activity of hepatocytes in chronic viral hepatitis as revealed by immunohistochemistry for proliferating cell nuclear antigen. *Human Pathol.* 1993;24(7):750–3.
15. Mocanu E, Broască V, Severin B. Ki-67 Expression In Hepatocellular Carcinoma Developed On A Liver Cirrhosis. *ARS Med Tomitana.* 2012;18(1):33–7.

### Author biography

**Shivani Iyyappan** Student

**Cite this article:** Iyyappan S, Barathi G . **Utility of Immunohistochemical Expression of Ki-67 in Liver Cirrhosis and Hepatocellular Carcinoma.** *IP J Diagn Pathol Oncol* 2020;5(3):318-322.