



## Original Research Article

## Efficacy of AGNOR staining on FNAC smears in non-neoplastic and neoplastic thyroid lesions with special emphasis on distinguishing benign from the malignant

Avinash Singh<sup>1,\*</sup>, V B Prakash<sup>2</sup>, Amita K<sup>2</sup>, Abhishek MG<sup>2</sup>, Vijay Shankar S<sup>2</sup>

<sup>1</sup>Dept. of Pathology, All India Institute of Medical Sciences, Patna, Bihar, India

<sup>2</sup>Dept. of Pathology, Adichunchanagiri Institute of Medical Sciences, Adichunchanagiri University, Mandya, Karnataka, India



## ARTICLE INFO

## Article history:

Received 06-08-2020

Accepted 13-08-2020

Available online 03-09-2020

## Keywords:

FNAC- Fine Needle Aspiration

Cytology

AgNOR

Thyroid

Cytodiagnosis

Adenoma

Thyroid epithelial cells

## ABSTRACT

**Background:** Eventhough FNAC is the most routinely performed, safe and cost effective diagnostic procedure for an initial diagnosis of thyroid lesions, we often come across difficulties in diagnosis, especially the grey zone lesions of the thyroid. In such cases AgNOR staining can be used as an adjunct to FNAC for establishing a more definitive cytopathological diagnosis. Hence this study was conducted to evaluate the role of AgNOR staining in diagnosis of benign and malignant thyroid lesions.

**Materials and Methods:** This prospective study included 150 cases of Fine needle aspirates of thyroid lesions done at the Department of Pathology, Adichunchanagiri Institute of Medical sciences, B.G Nagara during November 2016 to April 2018. AgNOR stained smears were evaluated. Silver stained NORs appeared as black dots were counted two different times by a single observer at a magnification of 100X oil immersion lens. 100 representative nuclei of thyroid follicular cells were selected. A mean was calculated which represented mean AgNOR count.

**Results:** In this study maximum number of cases were seen in 31-40yrs of life (35.3%). Male: female ratio in our study was 1:15.6 The mean values of AgNOR count are significantly higher in malignant group ( $4.92 \pm 1.71$ ) comparing benign group ( $2.20 \pm 1.06$ ). In the present study mean AgNOR count was highest in metastatic deposits of squamous cell carcinoma (10.2) and lowest in Hashimoto's thyroiditis, Hyperplastic goiter, and colloid goiter (1.8). Mean AgNOR count of follicular thyroid carcinoma (4.64) was higher than follicular adenoma ( $3.05 \pm 0.49$ ).

**Interpretation and Conclusion:** AgNOR staining can be used as an objective tool for correct diagnosis. It can also be used as an adjunct to FNAC for diagnosis of benign and malignant thyroid lesions.

© 2020 Published by Innovative Publication. This is an open access article under the CC BY-NC license (<https://creativecommons.org/licenses/by-nc/4.0/>)

### 1. Introduction

Thyroid gland is affected by a vast array of developmental, inflammatory, hyperplastic and neoplastic disorders. The prevalence of palpable thyroid nodule is 4 to 7% in the adult population and 0.2 to 2% in children.<sup>1</sup> Approximately 2-4 / 1,00,000 people per year are identified with a malignant thyroid lesion, accounting for 1% of all cancers and 0.5% of all cancer deaths.<sup>2</sup> It is important to rule out neoplasms in an enlarged thyroid gland as it necessitates surgical intervention. As for most lesions, distinction between benign from a malignant thyroid nodule is vital

in preventing misdiagnosis with early diagnosis and prompt treatment definitely leading to a better outcome.

It has already been proven that FNAC of the thyroid gland is safe, minimally invasive, sensitive, specific, accurate, economically viable and an easily performed OPD procedure<sup>3</sup> and along with molecular biomarkers have shown great promise in detecting malignancy.<sup>4</sup> But FNAC has certain limitations which include false negative and false positive results and results which fall into the indeterminate or grey zone category where the lesions are not obviously benign or malignant.<sup>5</sup>

Usefulness of silver staining technique for nucleolar organizing region (AgNOR) is well known and has been

\* Corresponding author.

E-mail address: [avinashsingh02186@gmail.com](mailto:avinashsingh02186@gmail.com) (A. Singh).

applied to a variety of neoplastic lesions or pathological material in order to distinguish benign from malignant.<sup>6</sup> In this study, AgNOR staining is used along with cytomorphological features in FNAC of the thyroid lesion to differentiate benign from malignant neoplasm and thus improving its diagnostic accuracy

## 2. Materials and Methods

This was a prospective time bound study done in the department of pathology, Adichunchanagiri Institute of medical Sciences, BG Nagara, Karnataka over a duration of one and half years from November 2016 to April 2018. Ethical committee approval was obtained from the institutional review board and institutional ethical committee. All the cases presenting to cytology clinic with thyroid lesions for fine needle aspiration cytology (FNAC) were included in the study. Patients from whom inadequate material was aspirated from the thyroid lesion and non-cooperative cases in whom FNAC was not performed were excluded from the study. Demographic data and radiologic findings when available were recorded. Thorough local examination for the location, size, nodularity, and consistency was done and the findings were recorded. FNAC was done by the trained cytopathologist using 23 G needle. A maximum of two passes was performed. In case of large swellings aspiration was done from different areas to minimize sampling error. From aspirated material, 4–6 smears were made, out of them 2–4 smears were immediately fixed in 95% ethyl alcohol for haematoxylin & eosin (H & E) stain and Papanicolaou stain and rest of the 2 smears were air dried, one for Giemsa stain and other subsequently fixed in 95% alcohol for AgNOR stain. Cytological diagnosis was done from Pap-stained, H&E stained and Giemsa stained smears and analysis of AgNORs done from AgNOR-stained smear to differentiate benign from malignant lesions.

Silver stained NORs which appeared as black dots were counted two different times by a single observer at a magnification of 100X oil immersion lens. 100 representative nuclei of thyroid follicular cells were selected. A mean was calculated, which represented mean AgNOR count. Quantifications were always performed in well-preserved cells, excluding areas of staining artifacts or overlapped cells. In cases where only two smears were made. It was stained with H & E and Giemsa stain. After FNAC diagnosis was made. H&E stained slides were destained with solution of acid-alcohol and were stained with AgNOR stain which gave similar results.

### 2.1. Statistical analysis

In this Prospective study, cytological diagnosis was obtained by correlation of clinical history, clinical diagnosis, radiological findings, adequacy of smear,

predominant patterns and individual cell cytomorphology. Histopathological correlation was done wherever possible. AgNOR count was done in all the cases.

Tabulated data was analyzed systematically by the use of appropriate statistical methods and SSPS software and results were obtained. Data were expressed as mean values and percentage. Comparison between groups were done by unpaired t test and one way ANOVA test. Sensitivity, specificity, standard deviation and range were analyzed whenever required. A p value of less than 0.05 was considered to be statistically significant.

## 3. Results

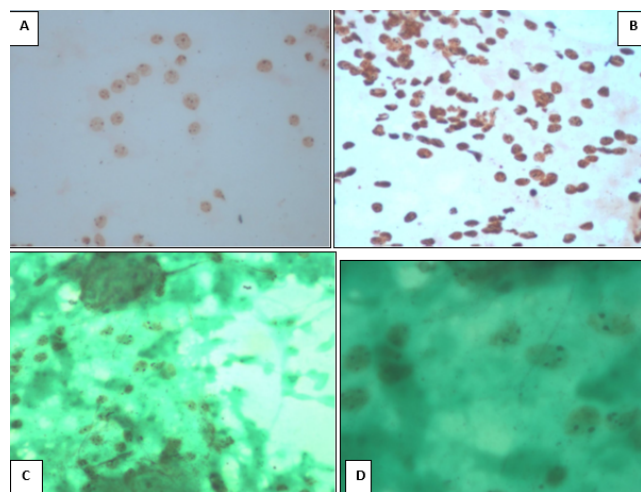
### 3.1. Demography

A total of 150 cases were who underwent thyroid gland FNAC were included in the study group. The mean age of patient was 39.6 years, the youngest patient was 8 years old and oldest was 70 years old. Females were more frequently affected with male to female ratio being 1:15.6.

Overall mean AgNOR of all the 150 cases of thyroid lesions was 2.55 (SD±1.47, CI 95%) and with range of 0-10.2. Hashimoto's thyroiditis has maximum of 56 cases followed by 40 cases of colloid goiter and 8 cases of adenomatous goiter. There were 2 cases of Dequervain's thyroiditis with mean AgNOR count of 2.70 (SD±0.42, CI 95%) and range of 2.4-3. There were two cases of hurtle cell neoplasm with mean AgNOR count of 3.5 (SD±0.14, CI 95%) in the range of 3.4-3.6. Only one case of Anaplastic carcinoma was there with AgNOR count of 4.80. Single case of metastatic deposits of squamous cell carcinoma was there with AgNOR count of 10.2. There was statistically significant difference in the mean AgNOR score among various thyroid lesions (p=0.000). The distribution of total 150 cases along with their mean AgNOR score is shown in Table 1.

Total number of benign thyroid cases were 131. Overall mean AgNOR count of benign thyroid lesions was found to be 2.20 (SD±1.06, CI 95%) with a range of 0-3.8. Total number of malignant thyroid cases were 19. Overall mean AgNOR count of malignant thyroid lesions was found to be 4.92 (SD±1.71, CI 95%) with a range of 2.6-10.2. Out of 150 cases, histopathological diagnosis was available in 18 cases. There were 9 cases of papillary carcinoma thyroid, three cases of Non Invasive Follicular Thyroid Neoplasm with Papillary like nuclear features (NIFTP), one case of hurtle cell adenoma, two cases of follicular adenoma, one case of follicular carcinoma, and one case of multinodular goiter and one case of Sclerosing variant of HT. Overall mean AgNOR count of histopathological diagnosis was 2.55 (SD±1.47, CI 95%) and range was from 0-10.2. Follicular adenoma had mean AgNOR count of 3.05 (SD±0.49, CI 95%) and range was 2.7-3.4. Single case of follicular carcinoma had mean AgNOR count of 4.6.

Single case of Hurthle cell adenoma had mean AgNOR count of 3.6. There were three cases of NIFTP, which had mean AgNOR count of 3.63 (SD±0.32, CI 95%) and range was 3.4-4. Correlation between AgNOR count and histopathological diagnosis is shown in Table 2.



**Fig. 1:** **A:**FNAC showing benign thyroid follicular cells with AgNOR dots in colloid goitre. Without counter stain(Methyl Green) (AgNOR, x400), **B:** FNAC showing cluster of benign thyroid follicular cells with AgNOR dots in Hashimoto's Thyroiditis. Without counter stain(Methyl green)(AgNOR, x400), **C:** FNAC showing clusters of benign thyroid follicular cells in Hyperplastic Goitre.(AgNOR, x400), **D:** FNAC showing clusters of benign thyroid follicular cells in Hyperplastic Goitre with AgNOR dots.(AgNOR, x1000)

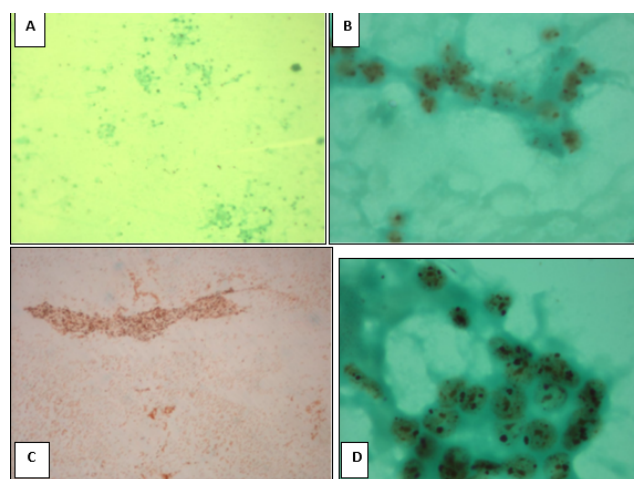
#### 4. Discussion/Conclusion

Thyroid disease is a common clinical problem. It is important to distinguish non-neoplastic and neoplastic thyroid lesions. FNAC is safest and cost effective method of preoperative diagnosis of thyroid lesions. The majority of thyroid nodules have a characteristic cytological pattern, allowing specific diagnosis.<sup>12</sup> But, FNAC has certain limitations, especially in case of thyroid neoplasm.

AgNOR analysis is a method for routine assessments of cell proliferation rapidly.<sup>13–15</sup>

However, AgNOR measurement is affected by several factors such as temperature and method of counting. Other ancillary techniques such as enzyme techniques, DNA measurements, immunocytochemistry and morphometric studies have been used with varying degree of success in differentiating benign and malignant thyroid neoplasm. AgNOR is one of such marker which seems highly sensitive and specific to distinguish between benign and malignant thyroid lesions in smears because more accuracy is ensured after whole nuclei have been assessed.<sup>6</sup>

The study was undertaken with aim of evaluating diagnostic efficacy of AgNOR staining in FNAC of thyroid



**Fig. 2:** **A:** FNAC showing thyroid follicular cells arranged in microfollicles in Follicular Neoplasm. (AgNOR, x40), **B:** FNAC showing thyroid follicular cells in Follicular Neoplasm with AgNOR dots. (AgNOR, x1000), **C:** FNAC showing thyroid follicular cells arranged in sheets in Papillary carcinoma thyroid. Without counterstain (Methyl green)(AgNOR, x40), **D:** FNAC showing cluster of thyroid follicular cells in Papillary carcinoma thyroid with AgNOR dots (AgNOR,x1000)

lesions along with cytomorphological features. Thyroid cytology comprised 8.4% of total FNACs conducted at our institution in the study period. This is in accordance with the study by Chalise et al(2013), where 8.79% of cases were of thyroid.<sup>11</sup>

In this study ,number of benign cases was 131 which is closest to the benign cases of the study done by Hossian Et al (2012).<sup>8</sup>The overall mean AgNOR count of benign thyroid lesions was  $2.20 \pm 1.06$ , which is in accordance with all the studies. The study done by Mehrotra et al (1998)<sup>10</sup>had mean AgNOR count of benign lesions (2.28), which was closest to our study. Comparison of Mean AgNOR Scores and Standard Deviation (SD) in Benign Thyroid lesions is shown in Table 3.

Number of malignant cases was 19 which is closest to the malignant cases of the study done by Hossian Et al (2012).<sup>8</sup> The overall mean AgNOR count of malignant thyroid lesions was  $4.92 \pm 1.71$  which is in accordance with all the studies. The study done by Eroo et al (2011)<sup>9</sup>had mean AgNOR count of malignant lesions (4.6), which was closest to our study. Comparison of Mean AgNOR Scores and Standard Deviation (SD) in Malignant Thyroid lesions is shown in Table 4 .

In this study, overall mean AgNOR score of malignant thyroid lesions(4.92) was found to be considerably higher than overall mean AgNOR score (2.20) of benign thyroid lesions. This was in accordance with other studies which also showed higher mean AgNOR score of malignant thyroid lesions. In the study done by Eroo et al(2013),<sup>16</sup> they found a cut-off value for differentiating normal thyroid

**Table 1:** Mean value of AgNOR count with SD for different thyroid lesion with P value between them

	N	Mean	Std. Deviation	Std. Error	95% Confidence Interval for Mean		Minimum	Maximum
					Lower Bound	Upper Bound		
Acute Thyroiditis	1	2.800					2.8	2.8
Adenomatous Goitre	8	2.875	.2375	.0840	2.676	3.074	2.4	3.2
Anaplastic Carcinoma	1	4.800					4.8	4.8
Colloid Goitre	40	1.500	1.2961	.2049	1.085	1.915	0.0	3.4
Dequervain's thyroiditis	2	2.700	.4243	.3000	-1.112	6.512	2.4	3.0
Follicular Neoplasm	3	3.567	.9609	.5548	1.180	5.954	2.7	4.6
HT	56	2.416	.8746	.1169	2.182	2.650	0.0	3.8
Hurtle Cell Neoplasm	2	3.500	.1414	.1000	2.229	4.771	3.4	3.6
Hyperplastic goitre	20	2.500	.5487	.1227	2.243	2.757	1.8	3.8
Lymphocytic thyroiditis	1	2.000					2.0	2.0
Metastatic deposits of SCC	1	10.200					10.2	10.2
papillary carcinoma thyroid.	15	4.733	1.1800	.3047	4.080	5.387	3.2	7.1
<b>Total</b>	<b>150</b>	<b>2.548</b>	<b>1.4693</b>	<b>.1200</b>	<b>2.311</b>	<b>2.785</b>	<b>0.0</b>	<b>10.2</b>

**Table 2:** Correlation between AgNOR count and histopathological diagnosis

Histopathological diagnosis	N	Mean	Std. Deviation	Std. Error	95% Confidence Interval for Mean		Minimum	Maximum
					Lower Bound	Upper Bound		
Follicular Adenoma	2	3.050	.4950	.3500	-1.397	7.497	2.7	3.4
Follicular carcinoma	1	4.600					4.6	4.6
Hurtle cell Adenoma	1	3.600					3.6	3.6
MNG	1	2.400					2.4	2.4
NIFTP	3	3.633	.3215	.1856	2.835	4.432	3.4	4.0
Not done	132	2.298	1.3069	.1138	2.073	2.523	0.0	10.2
PTC	8	5.275	1.1119	.3931	4.345	6.205	4.2	7.1
PTC- mixed follicular and papillary variant	1	5.900					5.9	5.9
Sclerosing variant of HT	1	3.200					3.2	3.2
<b>Total</b>	<b>150</b>	<b>2.548</b>	<b>1.4693</b>	<b>.1200</b>	<b>2.311</b>	<b>2.785</b>	<b>0.0</b>	<b>10.2</b>

**Table 3:** Comparison of Mean AgNOR Scores and Standard Deviation (SD) in Benign Thyroid lesions

Author(s)	Year	Total number of Thyroid cases	Number of benign thyroid cases	Mean AgNOR score	SD
Varghese et al <sup>7</sup>	2017	50	28	2.04	1.157
Hossain et al <sup>8</sup>	2012	157	148	1.91	0.36
Eroz et al <sup>9</sup>	2011	56	30	2.0	0.5
Asotra et al <sup>6</sup>	2008	140	100	2.94	0.085
Mehrotra et al <sup>10</sup>	1998	140	62	2.28	0.88
Present study	2018	150	131	2.20	1.06

**Table 4:** Comparison of Mean AgNOR Scores and Standard Deviation (SD) in Malignant Thyroid lesions.

Author(s)	Year	Total number of thyroid cases	Number of malignant thyroid cases	Mean AgNOR score	SD
Varghese et al <sup>7</sup>	2017	50	22	7.46	3.329
Hossain et al <sup>8</sup>	2012	157	9	2.84	0.32
Eroz et al <sup>9</sup>	2011	56	26	4.6	1.2
Asotra et al <sup>6</sup>	2008	140	40	4.27	0.41
Mehrotra et al <sup>10</sup>	1998	140	78	3.49	0.62
Present study	2018	150	19	4.92	1.71

**Table 5:** Comparison of Mean AgNOR Scores and Standard Deviation (SD) in different thyroid lesions.

Authors	Year	Colloid Goitre	Hashimoto's Thyroiditis	Hyperplastic Goitre	Follicular Neoplasm	PTC
Varghese et al <sup>7</sup>	2017	1.16±0.167	1.194±0.407	1.52±0.46	5.03±0.251	7.65±3.18
Chalsie et al <sup>11</sup>	2013	2.64 ± 0.63	2.10±0.36	3.04±0.8	4.10±1.13	5.40±0.86
Asotra et al <sup>6</sup>	2008	2.94±0.85	2.76±0.082	2.82±0.088	3.15±0.80	5.08±1.11
Present Study	2018	1.73±1.29	2.42±0.874	2.50±0.548	3.567±0.96	4.73±1.18

tissue from benign nodules. AgNOR count was <1.5 in thyrocytes obtained from normal thyroid tissue, AgNOR count was between 1.5 and 2.9 for benign thyroid lesions. In this study, the mean AgNOR score of benign thyroid lesions (2.20) was found to be in the range of benign thyroid lesions given by Eroz et al(2013)<sup>16</sup>

Derenzini et al (2000) has stated in their study that a rapidly dividing cell must concentrate its ribosomal biogenesis in a shorter time than a slowly dividing cell. This can be achieved by activating a greater number of rDNA sequences for transcription. For this reason, a greater quantity of AgNOR proteins must be synthesised, which will increase the number of interphase AgNORs, the structural–functional units for rRNA synthesis.<sup>17</sup>

Hence, malignant cells should have higher AgNOR count. Eroz et al (2013)<sup>16</sup> have found that cutoff AgNOR count for cancer group which was >2.9. which supports the mean AgNOR count for malignant thyroid lesions (4.92) found in this study.

Analysis of the present study has shown statistically significant differences in AgNOR scores between benign and malignant lesions (P value = 0.00).

In the present study mean AgNOR count was highest in metastatic deposits of squamous cell carcinoma (10.2) and lowest in Hashimoto's thyroiditis, Hyperplastic goiter, and colloid goitre (1.8). Asotra et al (2008)<sup>6</sup> found highest mean AgNOR count in papillary carcinoma (5.08) and lowest in Hashimoto's thyroiditis (2.76). Mehrotra et al (1998)<sup>10</sup> found highest mean AgNOR count in follicular carcinoma (5.04) and lowest in case of thyroiditis (1.37). Khan et al (1996).<sup>18</sup> found highest mean AgNOR count in follicular carcinoma (2.85) and lowest in adenomatous goitre (1.92). Comparison of Mean AgNOR Scores and Standard Deviation (SD) in different thyroid lesions is shown in Table 5.

In the present study, only 18 cases underwent surgery for which histopathological correlation was available. The mean AgNOR count of various thyroid lesions were similar to the study done by Chalsie et al (2013).<sup>11</sup>

The present study had 6 cases in which diagnosis of suspicious of papillary carcinoma was made. Out of these 6 cases, histopathological correlation was available in 5 cases. Concordant diagnosis of PTC was made in 4 cases and discordant diagnosis was made in 1 case. Single case of suspicious of PTC on FNAC was Sclerosing variant of HT on histopathology. Mean AgNOR count (3.2) for this case

was within the range of AgNOR count of HT.

The Mean AgNOR count of all suspicious cases was 4.81 which was in accordance with the study done by Hossain et al (2012),<sup>8</sup> who found that in all suspicious cases mean AgNOR count was greater than 3.

This study had included the newer entity of Bethesda system of reporting thyroid cytopathology (2017) which was NIFTP.<sup>15</sup> The mean AgNOR count for NIFTP was 3.63±0.32. In this study mean AgNOR count of NIFTP was compared with PTC by Student t test, which was statistically significant. Mean AgNOR count of NIFTP (3.63±0.32) was less as compared to PTC (5.27±1.11).

In the present study, mean AgNOR count of FTC was higher than FA, which is in accordance with other studies. Mean AgNOR count of FTC was closest to the mean AgNOR in Study by Chalsie et al (2013).<sup>11</sup> Mean AgNOR count of FA was closest to the mean AgNOR count by Augustynowicz et al (2004).<sup>19</sup> However, no significance was found (P value=0.237) when both FTC and FA were compared by student t test.

Limitations: One of the limitations of our study was lower biopsy sample for histopathological confirmation and also of unavailability of cases from every series, specially neoplastic cases.

## 5. Conclusion

Fine needle aspiration cytology is a very efficient, cost-effective and safe procedure for the diagnosis of thyroid lesions, but it is largely subjective and in a minority of cases a correct diagnosis cannot be made due to the existence of grey zone lesions. AgNOR staining can be used as an adjunct to FNAC for diagnosis of benign and malignant thyroid lesions. The grey zone lesions such as follicular adenoma and follicular carcinoma, which could not be differentiated only on the basis of FNAC, AgNOR count can be utilized as an additional tool in the cytological evaluation of follicular neoplasms.

## 6. Acknowledgement

Dr. MG Shivaramu, Principal Adichunchanagiri Institute of Medical Sciences, BG Nagara for the help and support provided.

## 7. Sources of Funding

None.

## 8. Conflict of Interest

None.

## References

- Gupta M, Gupta S, Gupta V. Correlation of Fine Needle Aspiration Cytology with Histopathology in the Diagnosis of Solitary Thyroid Nodule. *J Thyroid Res*. 2010;p. 1–5.
- Muratli A, Erdogan N, Sevim S, Unal I, Akyuz S. Diagnostic efficacy and importance of fine-needle aspiration cytology of thyroid nodules. *J Cytol*. 2014;31(2):73.
- Bagga PK, Mahajan NC. Fine needle aspiration cytology of thyroid swellings: How useful and accurate is it? *Indian J Cancer*. 2010;47(4):437.
- Editorial Board. *Endocrinology*. 2015;156(5):2C.
- Sinna EA, Ezzat N. Diagnostic accuracy of fine needle aspiration cytology in thyroid lesions. *J Egypt National Cancer Inst*. 2012;24(2):63–70.
- Asotra S, Sharma J. Role of AgNORs in thyroid lesions on fine needle aspiration cytology smears. *J Cytol*. 2008;25(1):18.
- Varghese S, Vilasinamma L. Nucleolar Organiser Regions In Thyroid Lesions- A Study At A Tertiary Care Hospital In South India. *J Evol Med Dent Sci*. 2017;6(72):5137–41.
- Hossain MI, Hassan MQ, Bhattacharjee P, Ahamad MSU, Rahman Z. Role of Multiparameter Analysis of AgNORs in FNA Smears of Thyroid Swellings in Differentiating Benign and Malignant Lesions. *Pathol Res Int*. 2012;2012:1–7.
- Eroz R, Cucer N, Karaca Z, Unluhizarci K, Ozturk F. The Evaluation of Argyrophilic Nucleolar Organizing Region Proteins in Fine-Needle Aspiration Samples of Thyroid. *Endocr Pathol*. 2011;22(2):74–8.
- Mehrotra A, Agarwal PK, Chandra T. Cytopathology and AgNOR counts in fine-needle aspiration cytology smears of thyroid lesions. *Diagn Cytopathol*. 1998;19(4):238–43.
- Chalise S, Thapa S, Sayami G, Shrestha A. Argyrophilic nucleolar organizer regions of thyroid lesions on fine needle aspiration smears. *J Pathol Nepal*. 2013;3(5):361–6.
- Hashemi F, Nasseroleislamic. Comparison of argyrophilic nucleolar organizer regions in normal thyroid, nodular thyroid, nodular goiter and thyroid neoplasms. *J Iran Univ Med Sci*. 1999;6:246–52.
- Öfner D, Hittmair A, Marth C, Öfner C, Totsch M, Daxenbichler G, et al. Relationship Between Quantity of Silver Stained Nucleolar Organizer Regions Associated Proteins (Ag-NORs) and Population Doubling Time in Ten Breast Cancer Cell Lines. *Pathol Res Pract*. 1992;188(6):742–6.
- Trere D. AgNOR staining and quantification. *Micron*. 2000;31:127–31.
- Canet V, Montmasson MP, Usson Y, Giroud F, Brugal G. Correlation between silver-stained nucleolar organizer region area and cell cycle time. *Cytometry*. 2001;43(2):110–6.
- Eroz R, Cucer N, Unluhizarci K, Ozturk F. Detection and comparison of cut-off values for total AgNOR area/nuclear area and AgNOR number/nucleus in benign thyroid nodules and normal thyroid tissue. *Cell Biol Int*. 2013;37(3):257–61.
- Derenzini M, Trer D, Pession A, Govoni M, Sirri V, Chieco P. Nucleolar size indicates the rapidity of cell proliferation in cancer tissues. *J Pathol*. 2000;191(2):181–6.
- Khan EM, Pandey R. Differential Diagnosis of Fine Needle Aspiration Smears of Thyroid Nodules. *Acta Cytol*. 1996;40(5):959–62.
- Augustynowicz A, Dziecioł J, Machała BM. Assessment of proliferative activity of thyroid Hürthle cell tumors using PCNA, Ki-67 and AgNOR methods. *Folia Histochem Cytobiol*. 2004;42(3):165–8.

## Author biography

**Avinash Singh** Senior Resident

**V B Prakash** Assistant Professor

**Amita K** Professor

**Abhishek MG** Professor

**Vijay Shankar S** Professor and HOD

**Cite this article:** Singh A, Prakash VB, Amita K, Abhishek MG, Shankar S V. Efficacy of AGNOR staining on FNAC smears in non-neoplastic and neoplastic thyroid lesions with special emphasis on distinguishing benign from the malignant. *IP J Diagn Pathol Oncol* 2020;5(3):267-272.