



## Original Research Article

## Histopathological spectrum of tumor and tumor like lesions of oral cavity and oropharynx in tertiary care hospital

Shruthi Gowthami M R<sup>1,\*</sup>, Mahanthachar Veerabasappa<sup>2</sup>, Sharmila P Surhonne<sup>2</sup>

<sup>1</sup>Dept. of Pathology, Bangalore Medical College and Research Institute, Karnataka, India

<sup>2</sup>Dept. of Pathology, Rajarajeswari Medical College and Hospital, Karnataka, India



## ARTICLE INFO

## Article history:

Received 23-04-2020

Accepted 13-05-2020

Available online 04-06-2020

## Keywords:

Histopathology

Oral cavity

Oropharynx

Tumor

Tumorlike

## ABSTRACT

**Background:** Oropharyngeal cancers are most commonly observed cancers in Indian population. Oropharyngeal cancers have a poor prognosis. A histopathological study of lesions will give the exact cause and helps in initiation of optimal therapy at the earliest.

**Settings and design:** Prospective study

**Aims:** To study the histopathological changes in tumour and tumour like lesions of oral cavity and oropharynx

**Material and Methods:** A prospective study was carried out in patients of oral cavity and oropharynx lesions. Total 100 biopsies and resected specimens were studied. Data included sociodemographic data, clinical features and histopathological diagnosis of the specimen.

**Statistical analysis used:** Appropriate statistical tests

**Results and Conclusion:** In our study we observed 10% tumor like lesions, 4% benign lesions, 4% premalignant lesions and 63% malignant lesions. Mucocele was the commonest tumor like lesion. Squamous cell carcinoma was the most common malignant lesion in our study seen in 95.2% cases. Out of 60 Squamous cell carcinoma cases, 11.6% had lymph node metastases and 3.3% showed lymphovascular invasion. In TNM staging of 14 cases who underwent resection with modified radical neck dissection, maximum number of cases belonged to Stage II (35.71%) and Stage IV (35.71%).

© 2020 Published by Innovative Publication. This is an open access article under the CC BY-NC license (<https://creativecommons.org/licenses/by-nc/4.0/>)

### 1. Introduction

According to World Health Organization, carcinoma of oral cavity in males in developing countries, is the sixth commonest cancer, while in females, it is the tenth commonest site of cancer.<sup>1</sup> It typically occurs in elderly men during the fifth through eighth decade of life and is rarely seen in young people.

In India, head and neck cancers (HNCA) account for 30–40% cancers at all sites, out of which 9.4% being oral cancers. Oral cancers are the most common among head and neck malignancies.<sup>2,3</sup> It is the sixth most common cause of death in males and seventh in females.<sup>3</sup>

Although globally oral cancer represents an incidence of 3% males and 2% females of all malignant neoplasms, it has one of the lowest survival rates – 50% within a 5 year period.<sup>4</sup>

Many studies have shown that several factors lead to increase in the relative incidence of oral cancer. These include<sup>5,6</sup> Age and gender, Habits (Tobacco and alcohol) – dose response relations were observed for the frequency and duration of smoking and alcohol.<sup>7</sup> Orofacial factors (Poor oral hygiene, improperly fitting dental prostheses, defective dental restorations and mal-aligned or sharp teeth) and Viruses like Human Papilloma Virus, Herpes Simplex Virus, Epstein-Barr Virus.

WHO classification of tumours of oral cavity and oropharynx<sup>8</sup> (2005) includes major tumours like, Surface epithelial tumours (Squamous cell carcinoma Lymo-

\* Corresponding author.

E-mail address: Shruthigowthami.giselle@gmail.com (S. Gowthami M R).

hoepithelioma like carcinoma), salivary gland tumours (Salivary gland carcinomas and adenomas), Soft tissue tumours, Haematolymphoid tumours And Mucosal malignant melanoma.

The gold standard for the assessment of oral potentially malignant lesions is microscopic evaluation of haematoxylin and eosin stained sections for the presence of architectural and cytological changes, which are generally referred to as epithelial dysplasia.<sup>9</sup>

This study was conducted to study the histopathological changes in tumour and tumour like lesions of oral cavity and oropharynx.

## 2. Aim and Objective

To study the histopathological changes in tumor and tumor like lesions of oral cavity and oropharynx

## 3. Material and Methods

Present study is a prospective study carried out in department of pathology of a tertiary health care centre. Patients with oral cavity and oropharynx lesions were included in the study. Total 100 biopsies and resected specimens were received during study period of 2 years.

### 3.1. Inclusion criteria

Patients with lesion in oral cavity and oropharynx, undergoing biopsy or surgical treatment at tertiary health care center.

### 3.2. Exclusion criteria

1. All lesions involving teeth
- 2 The patients not willing to participate in the study

Study was approved by ethical committee of the institute. A valid written consent was taken from patients after explaining study to them.

Data was collected with pre tested questionnaire. Data included sociodemographic data of the patient, clinical history. A through clinical examination was done. All biopsies and resected specimens were received in 10% formalin. Gross findings were noted. Tissue processed and stained with Haematoxylin and Eosin.

### 3.3. Haematoxylin and Eosin staining method

1. Sections deparaffinised by putting in xylene
2. Hydrated by using descending grades of alcohol (100%, 90%, 70% for 1 minute each
3. Washed with distilled water Stained 4-8 minutes in Harris hematoxylin solution
4. Washed in running tap water for 1 hour until the blue colour developed
5. Stained in eosin for 25 to 45 seconds

6. Dehydrated using ascending grades of alcohol (70%, 90%, 100% for 1 minute each
7. Cleared with xylene Sections then mounted in DPX

Histopathological diagnosis was made. Patients with tumor and tumor like lesions were studied. Data was analyzed with appropriate statistical tests.

## 4. Results

Present study includes 100 cases of oral cavity and oropharyngeal lesions out of which 19% were inflammatory lesions, 10% tumor like lesions, 4% benign lesions, 4% premalignant lesions and 63% malignant lesions.

The patients' age in our study ranged from 6 to 80 years with a mean age of 45.6 years. Male preponderance was seen in malignant lesions with a male to female ratio of 1.7:1.

Among malignant lesions in our study, 60.3% had history of tobacco consumption, 17.5% consumed both alcohol and tobacco, 9.5% were alcoholics and 12.7% patients did not have any habits. So, most common risk factors were tobacco consumption and alcohol. They carried a definite risk for the development of malignant lesions. Buccal mucosa was the most common site of malignant lesions. Even benign and premalignant lesions had buccal mucosa as the most common site. Tonsil was the most common site among inflammatory lesions and lip among tumour like lesions.

Out of 63 cases of malignant lesions in our study, 41 cases underwent incisional biopsy, 6 cases underwent excisional biopsy and 16 cases underwent resections with or without modified radical neck dissections.

The predominant tumour-like lesion in our study was mucocele seen in 6 cases (60%) out of 10 cases (Figure 2). The other cases encountered were pyogenic granuloma in 2 cases (20%) and hamartoma in 2 cases (20%). Different types of mucoceles in our study were 4 cases (40%) were retention mucoceles, 1 case was extravasation mucocele (10%) and 1 case was ranula (10%).(Table 1)

Among 4 premalignant lesions 1 case was each of keratosis with mild atypia, keratosis with moderate atypia, submucous fibrosis and verrucous hyperplasia comprising of 25% each. (Table 3)

Out of 63 cases of malignant lesions in our study squamous cell carcinoma (Fig 4) was the most common histological type accounting for 60 cases (95.2%). The other 3 cases were, one case each of mucoepidermoid carcinoma, basal cell carcinoma and carcinosarcoma constituting 1.6% each. (Figure 1)

Out of 60 cases of Squamous cell carcinoma, majority were well differentiated type seen in 31 cases (51.67%) followed by moderately differentiated in 23 cases (38.33%) and 6 cases (10%) were poorly differentiated. (Table 4 )

In our study 14 cases of Squamous cell carcinoma underwent resections with modified radical neck dissections. Out

of these the extent of involvement is shown in Table 5

Out of 14 resected cases of Squamous cell carcinoma, 1 case (7.14%) belonged to T<sub>1</sub>N<sub>0</sub>M<sub>0</sub> (Stage I), 5 cases (35.71%) to T<sub>2</sub>N<sub>0</sub>M<sub>0</sub> (Stage II). 3 cases (21.43%) were of Stage III 1 case of T<sub>2</sub>N<sub>1</sub>M<sub>0</sub>, 1 case of T<sub>3</sub>N<sub>1</sub>M<sub>0</sub> and 1 case of T<sub>1</sub>N<sub>1</sub>M<sub>0</sub>. The rest 5 cases (35.71%) belonged to Stage IV wherein there were 2 cases of T<sub>2</sub>N<sub>2b</sub>M<sub>0</sub>, 1 case of T<sub>4a</sub>N<sub>2a</sub>M<sub>0</sub>, 1 case of T<sub>4a</sub>N<sub>1</sub>M<sub>0</sub> and 1 case of T<sub>4a</sub>N<sub>1</sub>M<sub>0</sub>. (Table 6 )

**Table 1:** Histopathology oftumour-like lesions of oral cavity and oropharynx

Histopathological type	No.	%
Mucocele	6	60
Hamartoma	2	20
Pyogenic granuloma	2	20
Total	10	100

**Table 2:** Histopathology of benign lesions of oral cavity andoropharynx

Histopathological type	No.	%
Cavernous hemangioma	1	25
Fibroma	3	75
Total	4	100

**Table 3:** Histopathology of premalignant lesions of oralcavity and oropharynx

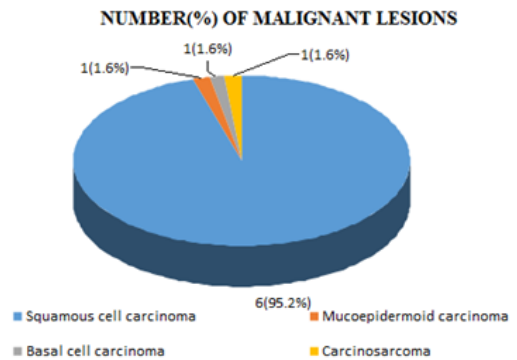
Histopathological type	No.	%
Keratosi with mild dysplasia	1	25
Keratosi with moderate dysplasia	1	25
Submucous fibrosis	1	25
Verrucous hyperplasia	1	25
Total	4	100

**Table 4:** Grading of Squamous cell carcinoma

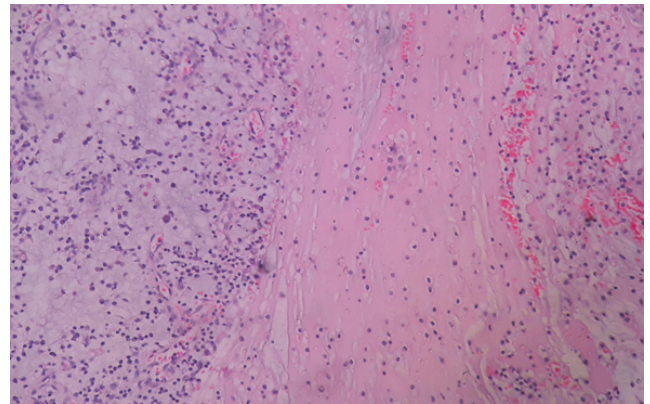
Grade	Squamous Cell Carcinoma	Percentage
Well differentiated (Grade 1)	31	51.67
Moderately differentiated (Grade 2)	23	38.33
Poorly differentiated (Grade 3)	6	10
Total	60	100

**5. Discussion**

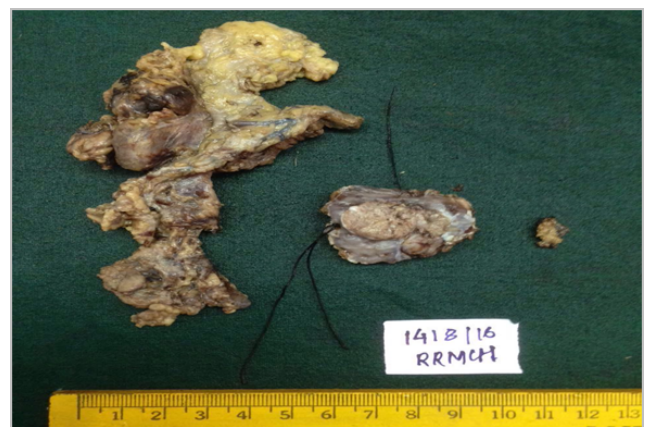In our study the premalignant lesions were seen predominantly in the age group 61-70 years.similar findings were seen in a study by Khan Y et al<sup>10</sup> and Atram MA<sup>11</sup> et al where they found the maximum incidence of premalignant lesions in the age group 40-60 years.



**Fig. 1:** Histopathology of malignant lesions of oral cavity and oropharynx



**Fig. 2:** Photomicrograph (20x, H&E) of Mucocele of lip shows extravasated mucin pool along with mixed inflammatory cell infiltrate. H & E- Hematoxylin & Eosin



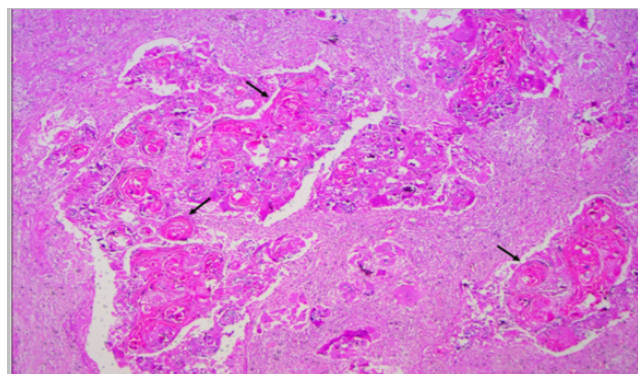
**Fig. 3:** Specimen of resection of tumour of right buccal mucosa with modified radical neck dissection.

**Table 5:** Resections with modified radical neck dissection and the extent of involvement

Involvement by tumour	Number of cases
Lymph node metastases	3
Lymphovascular invasion + Lymph node metastases	1
Lymph node metastases + Soft tissue invasion	1
Lymphovascular invasion + Minor salivary gland + skeletal muscle invasion	1
Lymph node metastases + Overlying skin+ soft tissue invasion	2
No involvement of regional lymph nodes and surrounding structures	6
Total	14

**Table 6:** Staging of resected tumors

Staging	Squamous Cell Carcinoma		
	Number	Percentage	
I	1	7.14	
II	5	35.71	
III	3	21.43	
IV	A	5	35.71
	B	0	0
	C	0	0
Total	14	100	

**Fig. 4:** Photomicrograph (10x, H & E) shows an infiltrating well differentiated SCC of left buccal mucosa composed of nests of tumour cells along with well formed keratin pearls scattered throughout the tumor. H & E- Hematoxylin & Eosin; SCC- Squamous Cell Carcinoma

Present study is in concordance with studies by Misra V et al,<sup>12</sup> Khandekar SP et al<sup>13</sup> and Gupta M et al<sup>14</sup> where peak incidence of malignant lesions was seen in the age group 51-60 years.

These studies found the maximum incidence of oral malignancies in people over 50 years of age in concordance with the present study. Hence, screening programs targeting men over 50 years, would help in early diagnosis of oral malignancy.

### 5.1. Histopathological spectrum of tumor like lesions

The predominant tumor-like lesion in our study was mucocele seen in 60% cases. Our study is comparable with the study by Atram MA et al<sup>11</sup> where mucocele was the most common tumour like lesion found in 50% cases. In a study by Khan Y et al,<sup>10</sup> Pyogenic granuloma was the most common lesion found in 53.6% cases.

### 5.2. Histopathological spectrum of benign lesions

The most common benign lesion in our study is fibroma seen in 75% cases. In studies by Khan Y et al<sup>10</sup> and Atram MA et al<sup>11</sup> the most common benign tumor was hemangioma.

### 5.3. Histopathological spectrum of premalignant lesions

75% cases were leukoplakia in our study and formed the predominant premalignant lesions which is comparable with study by Nayak P et al<sup>15</sup> where 80% cases were leukoplakia.

### 5.4. Histopathological spectrum of malignant lesions

The most common malignant lesion was Squamous cell carcinoma in our study seen in 95.2% cases. Our study is in concordance with studies by Gupta M et al<sup>14</sup> and Nayak P et al<sup>15</sup> which showed Squamous cell carcinoma as the commonest histological type among malignant lesions in 98.18% and 98% respectively.

### 5.5. Grading of oral SCC

Well differentiated SCC was the most common type in our study seen in 51.67% of SCC. The present study is in concordance with studies done by Khan Y et al<sup>10</sup> and Rai HC et al<sup>16</sup> where majority of cases were well differentiated SCC seen in 47.61% and 51% of SCCs respectively.

### 5.6. Tumor clearance

Out of 16 resected specimens, the tumor involved resected margins in 7 cases (43.7%) in our study with a tumor clearance of 56.3%. Our study has lower tumor clearance as compared to the study by Jerjes et al<sup>17</sup> where tumour clearance was seen in 93% cases.

### 5.7. Resections with modified radical neck dissection

In our study 14 cases (23.3%) out of 60 cases of Squamous cell carcinoma underwent resections with modified radical neck dissections. 7 cases (11.6%) out of 60 Squamous cell carcinomas had lymph node metastases and 2 cases (3.3%) showed lymphovascular invasion.

Our study showed a lower incidence of lymph node metastases (11.6%) and lymphovascular invasion (3.3%)

compared to a study by Beggan C et al<sup>18</sup> which showed nodal metastases in 17 cases (29.3%) and lymphovascular invasion in 11 cases (19%).

### 5.8. Staging of tumours

In our study 35.71% of patients belonged to Stage II and 35.71% to Stage IV. In a study by Suresh TN et al<sup>19</sup> 43.8% of patients belonged to Stage IV which is slightly more than that in our study and 21% of patients belonged to Stage II. Whereas Stage I (5.7%) and Stage III (29.5%) in our study was comparable with Stage I (7.14%) and Stage III (21.43%) of their study.

### 6. Conclusion

Histopathological examination of lesions of oral cavity and oropharynx is gold standard. The present study on 100 oral cavity and oropharyngeal lesions showed predominance of malignant lesions seen in 63% cases. The most common malignant lesion in our study was Squamous cell carcinoma.

### 7. Source of Funding

None.

### 8. Conflict of Interest

None.

### References

- Mehrotra R, Yadav S. Oral squamous cell carcinoma: Etiology, pathogenesis and prognostic value of genomic alterations. *Indian J Can.* 2006;43:60–6.
- Ahluwalia H. Spectrum of head and neck cancers. *Indian J Otorhinolaryngol Head Neck Surg.* 2001;53(1):16–21.
- Bhattacharjee A, Chakraborty A, Purkaystha P. Prevalence of head and neck cancers in North East - An institutional study. *Indian J Otolaryngol Head Neck Surg.* 2006;58(1):15–19.
- Kujan O, Glenny AM, Duxbury J, Thakker N, Sloan P. Evaluation of screening strategies for improving oral cancer mortality: A Cochrane Systematic Review. *J Dent Educ.* 2005;69(2):255–65.
- Osterkamp RW, Whitten JB. The Etiology and Pathogenesis of Oral Cancer. *CA: A Cancer J Clin.* 1973;23(1):28–32.
- Feller L, Lemmer J. Oral Squamous Cell Carcinoma: Epidemiology, Clinical Presentation and Treatment. *J Cancer Ther.* 2012;03(04):263–8.
- Muwonge R, Ramadas K, Sankila R, Thara S, Thomas G, Vinoda J, et al. Role of tobacco smoking, chewing and alcohol drinking in the risk of oral cancer in Trivandrum, India: A nested case-control design

using incident cancer cases. *Oral Oncol.* 2008;44(5):446–54.

- Gale N, Pilch BZ, Sidransky D, Naggar AE, Westra W, Califano J, et al. World Health Organization classification of tumours Pathology and Genetics Head and Neck Tumours. Lyon: IARC press; 2005. p. 163–208.
- Waal IVD. Potentially malignant disorders of the oral and oropharyngeal mucosa: present concepts of management. *Oral Oncol.* 2010;46:423–5.
- Khan Y, Birare SD. Study of Histopathology of the Tumour like Lesions and Tumours of the Oral Cavity. *IJSR.* 2016;5(4):915–20.
- Atram MA, Bhalavi V, Dantkale S. A Clinicopathological study of tumors and tumor like lesions of oral cavity. *IJBAMR.* 2016;5(3):146–53.
- Misra V, Singh P, Lal N, Agarwal P, Singh M. Changing pattern of oral cavity lesions and personal habits over a decade: Hospital based record analysis from Allahabad. *Indian J Community Med.* 2009;34(4):321.
- Khandekar SP, Bagdey PS, Tiwari RR. Oral cancer and some epidemiological factors: A hospital based study. *Indian J Comm Med.* 2006;31(3):157–9.
- Gupta M, Choudhary H, Gupta N, Gupta A. Histopathological study of neoplastic lesions of oral cavity and oropharynx. *Int J Res Med Sci.* 2016;4:1506–10.
- Nayak P, Behera SK. Clinicopathological Study of Premalignant And Malignant Lesions of Oral Cavity. *IOSR-JDMS.* 2017;16(8):20–23.
- Rai HC, Ahmed J. Clinicopathological Correlation Study of Oral Squamous Cell Carcinoma in a Local Indian Population. *Asian Pacific J Cancer Prev.* 2016;17(3):1251–1254.
- Jerjes W. Clinicopathological parameters, recurrence, locoregional and distant metastasis in 115 T1-T2 oral squamous cell carcinoma patients. *Head Neck Oncol.* 2010;2(9):1–11.
- Beggan C, Fives C, O'Leary G, Sheahan P, Heffron CC, Feeley L. Pattern of invasion and lymphovascular invasion in squamous cell carcinoma of the floor of the mouth: an interobserver variability study. *Histopathol.* 2016;69(6):914–20.
- Suresh TN, Hemalatha A, Kumar MH, Mohiyuddin SA. Evaluation of histomorphological and immunohistochemical parameters as biomarkers of cervical lymph node metastasis in squamous cell carcinoma of oral cavity: A retrospective study. *J Oral Maxillofac Pathol.* 2015;19(1):18–24.

### Author biography

**Shruthi Gowthami M R** Senior Resident

**Mahanthachar Veerabasappa** Professor

**Sharmila P Surhonne** Professor and HOD

**Cite this article:** Gowthami M R S, Veerabasappa M, Surhonne SP. **Histopathological spectrum of tumor and tumor like lesions of oral cavity and oropharynx in tertiary care hospital.** *IP J Diagn Pathol Oncol* 2020;5(2):174–178.