



## Case Report

# A rare case of bilateral mucinous cystadenocarcinoma of ovary mimicking endometriotic ovarian cyst on radiology

Suman Saurabh Gupta<sup>1</sup>, Sunita B Patil<sup>1,\*</sup>, Suchita V Deshmukh<sup>1</sup>, Seema. S More<sup>1</sup>

<sup>1</sup>Dept. of Pathology, D.Y. Patil Medical College, Kolhapur, Maharashtra, India



### ARTICLE INFO

#### Article history:

Received 25-01-2020

Accepted 31-01-2020

Available online 29-02-2020

#### Keywords:

Mucinous ovarian tumor  
bilateral mucinous  
cystadenocarcinoma  
histopathology  
ovarian epithelial tumour

### ABSTRACT

Epithelial carcinoma accounts for more than 95% of ovarian malignancy. Approximately 15% of all ovarian tumours are mucinous. Approximately 80% of the mucinous tumour are benign, 10% are borderline and 10% are invasive carcinomas. Hence bilateral invasive mucinous carcinoma is a rare type of tumour with low incidence. In our case, a 37 years old woman presented with irregular menses, oligomenorrhea, pain in abdomen and abdominal distension. Radiological studies suggested endometriotic cysts however on histopathological examination, it revealed mucinous cystadenocarcinoma in both ovary. Thus histopathology is gold standard for definitive diagnosis.

© 2020 Published by Innovative Publication. This is an open access article under the CC BY-NC-ND license (<https://creativecommons.org/licenses/by/4.0/>)

## 1. Introduction

Epithelial carcinoma accounts for more than 95% of ovarian malignancy. The incidence of ovarian epithelial tumors varies globally with highest rates being observed in Scandinavia, Israel and North America and lowest rates found in developing countries and Japan.<sup>1</sup> 90-95% are sporadic cases however genetic factors are most important risk factor for ovarian epithelial carcinoma. Factors that decrease the risk of ovarian carcinomas are use of oral contraceptives, breast feeding and multiparity.<sup>2</sup> Epithelial carcinomas are mostly found in postmenopausal women. In this article we present a case of bilateral mucinous papillary cystadenocarcinoma in a nulliparous woman with ankylosing spondylitis which radiologically presented as endometriotic cyst.

## 2. Case Report

A 37years old, nulliparous, unmarried, woman presented with irregular menses, oligomenorrhea, pain in abdomen and abdominal distension. She is known case of ankylosing

spondylitis and hypertension since 6 yrs. There was a past history of hip replacement surgery 2.5 years ago. Family history was not contributory.

Per abdominal examination showed large abdominal mass arising from pelvis. Clinically, it was suspected to be ovarian cyst. The other systemic examinations revealed no significant pathology.

Laboratory routine investigations revealed microcytic hypochromic anemia with relative neutrophilia. Other haematological parameters were within normal range. Coagulation profile was within normal limits.

Urine on culture showed heavy growth (large mucoid beta haemolytic colonies on blood agar) of *Klebsiella oxytoca*.

Thyroid function tests were within normal limits.

Tumour marker studies revealed, Serum Alpha fetoprotein was 2.50ng/ml, CA-125 was 270 U/ml elevated (normal range 0.0 – 32.0), CEA was 6.51ng/ml is (normal range in non-smoker- 0.0- 5.0) and raised INHIBIN A levels 69.7pg/ml.

Serological tests for Anti-HCV, HBsAg and HIV I & II were negative, Blood PCR was negative for *Mycobacterium tuberculosis* complex.

\* Corresponding author.

E-mail address: [drsunitapatil09@gmail.com](mailto:drsunitapatil09@gmail.com) (S. B. Patil).

Ultrasonography of abdomen and pelvis, showed surface nodularity, with multiple internal thick septate hetero echoic cystic lesions in both ovaries. Right ovary measures 8.1 x 5.6 x 5.2 cms, and on left side it measures 8.9 x 8.4 x 7.9cms. No ascites seen. Left kidney showed hydronephrosis with proximal hydroureter secondary to compression by left ovarian lesion. Other organs were normal. No obvious lymphadenopathy was noted. Radiological findings of bilateral ovaries suggested most likely diagnosis of endometriomas of ovary. (Figure 1)

Anterior-Posterior and lateral view of chest X-ray revealed normal study.

Plain and Contrast Enhanced Computed Tomography study findings revealed Cystic morphology lesions in the bilateral adnexa not seen separate from the ovaries with haemorrhagic contents- possibility of endometriotic cysts.

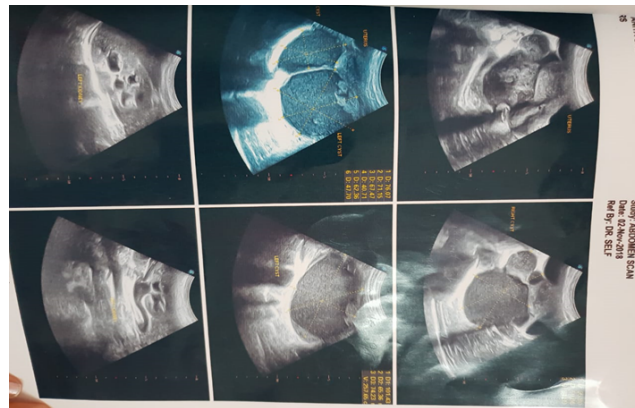
On intravenous urography study, there was left proximal hydroureter and hydronephrosis with effacement and smooth narrowing of distal ureter, likely due to extrinsic compression due to ovarian cystic lesion. Normal functioning both kidneys.

Patient underwent exploratory laparotomy with total hysterectomy and ureteric stent surgery. Intraoperatively,, there was no evidence of any peritoneal nodular lesions. The specimen was sent to the department of pathology for histopathological examination.

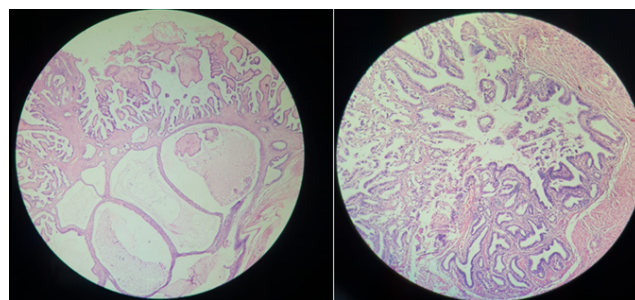
We received hysterectomy specimen with detached bilateral adnexa. The specimen was fixed in 10% formalin overnight. On gross examination, Uterus, cervix, both fallopian tubes were unremarkable on external and cut section. Specimen labelled as right ovary, measured 9x7x6cms and left ovary measures 7.5x6.5x4 cms. Both the ovaries showed nodular external surface. On cut section multiloculated cyst filled with thick mucoid gelatinous material. Foci of solid areas and papillary excrescences were noted on the inner surface of the cysts. No areas of grossly evident haemorrhage or necrosis. On microscopic examination of multiple sections from both the ovarian masses revealed similar findings i.e cystic structures lined by mucin secreting epithelium showing stratifications and atypical nuclei , numerous papillary fronds, distorted arrangement of mucinous glands with increase gland complexities infiltrating the stroma. Stroma shows mononuclear inflammatory infiltrate with focal accumulation of mucin. No capsular invasion noted. No tumour seen on the ovarian surface. (Figure 2) Histopathological diagnosis was bilateral mucinous cystadenocarcinoma ovary.

### 3. Discussion

Primary Mucinous cystadenocarcinoma is the second most common tumour of the ovary, which involve surface epithelium. Approximately 15% of all ovarian tumours are mucinous.<sup>3</sup> There are three types of mucinous tumours i.e. benign, borderline and malignant type. Approximately 80%



**Fig. 1:** Ultrasonography studies shows ovarian cyst and hydronephrosis



**Fig. 2:** Photomicrograph shows mucinous tumour exhibiting papillary architecture and invasion into stroma

of the mucinous tumour are benign, 10% are borderline and 10% are invasive carcinomas<sup>4</sup> The mucinous carcinomas of ovary are usually large; having mean diameter of 16 to 19 cms.<sup>5</sup>

It is a very rare type of tumor.<sup>6</sup> The incidence of primary mucinous adenocarcinoma is low. Mostly they present as huge unilateral ovarian mass measuring more than 15cms in diameter, with a smooth external surface. In our case, the mass was bilateral and not more than 10cms in diameter on both the sides and there was nodular external surface. In spite of not so large tumors and bilaterality our case was of primary mucinous cystadenocarcinoma. The young age, expansile growth pattern, necrotic luminal debris and histologic areas of destructive stromal invasion with malignant cellular, are the features favouring ovarian carcinoma.

In our case there were elevated levels of CA125, CEA and INHIBIN A. As per various other studies there is no uniform or consistent elevation and co relation with clinical stage of specific ovarian tumor markers like CA125, CA19-9.

Metastases to the other organ is rare. In stage 1 survival rate is 95% and for stage 2 it is 32% or greater. According to the international federation of gynecology and

obstetrics, lymphnode dissection is necessary in early stage of ovarian cancer to make an accurate staging and to select the adequate adjuvant therapy. But it is still unknown, the effect of lymph node dissection on overall survival in patients with advanced ovarian cancer. In our case there were no enlarged lymphnode detected on radiology or intraoperatively. Infiltrative invasion, high nuclear grade, tumor rupture are the prognostic factors for the stage 1 tumor. Advance mucinous ovarian cancer has a worse outcome as compared to non-mucinous type, living is 3 times more in advance non-mucinous ovarian cancer as compare to mucinous pathology.<sup>7</sup>

In our case mucinous cystadenocarcinoma was seen in patient with ankylosing spondylitis however we could not attribute association of these two conditions.

Clinical and radiological findings of ovarian cancer and as well as tumor heterogeneity are the major concerns and pose diagnostic challenges. Histopathology is gold standard in such cases, and will be helpful for better management of patient.

#### 4. Source of funding

None.

#### 5. Conflict of interest

None.

#### References

- Desai A. Epithelial Ovarian Cancer – An Overview ; 2014,. doi:10.5528/wjtm.v3.i1.1.
- Lee-Jones L, Ovary. Epithelial tumours. *Atlas Genet Cytogenet Oncol Haematol* . 2004;8:115–133.
- Pecorelli S, Odicino F, Maisonneuve P, Creasman W, Shepard J, et al. Carcinoma of the ovary: annual report on the results of treatment of gynaecological cancer. *J Epidemiol Biostat*. 1998;3:75–102.
- Seidman JD, Kurman RJ, Ronnet BM. Primary and metastatic mucinous adenocarcinomas in the ovaries: incidence in routine practice with a new approach to improve intraoperative diagnosis. *Am J Surg Pathol*. 2003;27:985–993.
- Hoerl HD, Hart WR. Primary ovarian mucinous cystadenocarcinoma: A clinicopathological study of 49 cases with long term follow-up. *Am J Surg Pathol*. 1998;22:1449–1462.
- Kuşcu NK, Çağlar H, İshakoğlu M, Kandiloğlu AR, Keleş GT. Giant mucinous cystadenocarcinoma: a case report. *Arch Gynecol Obstet*. 2003;267(3):158–159. doi:10.1007/s00404-002-0297-4.
- Lee KR, Young RH. The Distinction Between Primary and Metastatic Mucinous Carcinomas of the Ovary: gross and histologic findings in 50 cases. *Am J Surg Pathol*. 2003;27(3):281–292. doi:10.1097/0000478-200303000-00001.

#### Author biography

**Suman Saurabh Gupta** IInd Year Post Graduate

**Sunita B Patil** Associate Professor

**Suchita V Deshmukh** Assistant Professor

**Seema. S More** Professor and HOD

**Cite this article:** Gupta SS, Patil SB, Deshmukh SV, More SS. A rare case of bilateral mucinous cystadenocarcinoma of ovary mimicking endometriotic ovarian cyst on radiology. *IP J Diagn Pathol Oncol* 2020;5(1):118-120.