



## Case Report

# An unusual presentation of *De-novo* Histoid leprosy clinically mimicking as neurofibromatosis

Savreet Pal Singh<sup>1</sup>, Anchal Bhola<sup>1</sup>, Neelam Gupta<sup>1,\*</sup>, Avnika Jasuja<sup>1</sup>, Mehak Kashyap<sup>1</sup>

<sup>1</sup>Dept. of Pathology, Maharishi Markandeshwar Medical College and Hospita, Solan, Himachal Pradesh, India



### ARTICLE INFO

#### Article history:

Received 09-01-2020

Accepted 30-01-2020

Available online 29-02-2020

#### Keywords:

Denovo

Histoid leprosy

Lepra bacilli

### ABSTRACT

Histoid leprosy is a rare and uncommon variant of lepromatous leprosy which generally occurs following resistance to dapsone therapy or relapse after dapsonemotherapy or multidrug therapy. Rarely, it can occur de novo without any history of treatment. We present one such rare case of *de-novo* histoid leprosy mimicking neurofibromatosis presented in a 43 year old male.

© 2020 Published by Innovative Publication. This is an open access article under the CC BY-NC-ND license (<https://creativecommons.org/licenses/by/4.0/>)

## 1. Introduction

Histoid leprosy is a well acknowledged entity in lepromatous patients presenting as characteristic cutaneous or subcutaneous nodules and plaques over the skin. The term "Histoid leprosy" was originally coined by Wade in 1963 as a histological concept of bacillary-rich leproma composed of spindle-shaped cells, along with the absence of globus formation (so conspicuous in ordinary leproma). In chronic form however it exhibits a fibromatoid tendency.<sup>1</sup>

Since then many cases have been reported in the literature.<sup>2</sup> We hereby present one such case of *de-novo* histoid leprosy mimicking neurofibromatosis in a 43 year old man.

## 2. Case Report

A 43 year old male presented with complaints of multiple skin coloured nodular painless, non-tender lesions measuring 0.5-1 cm over the right forearm, right shin, left ankle and dorsum of left foot (total 5 in number) since 6 months (Figure 1a). Many tender nodules were also noted on the gluteal region. There was no loss of sensation or

nerve thickening. There was no past history of similar lesions and a negative drug intake history for leprosy. General physical and systemic examinations turned out to be normal.

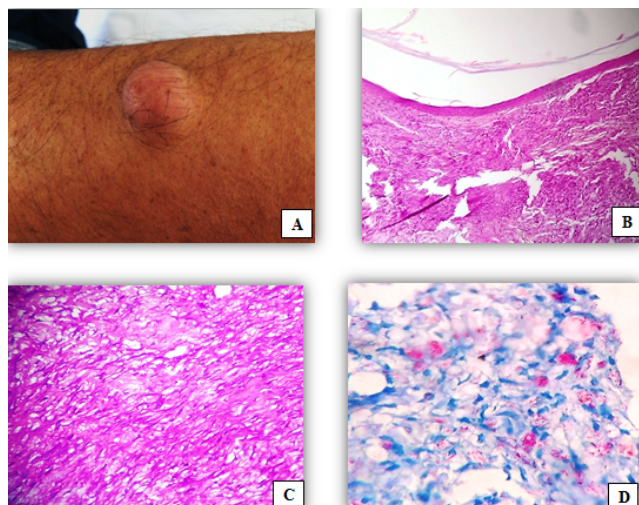
Clinically, differential diagnosis included neuromas, xanthomas, neurofibromas, dermatofibroma and histoid leprosy being last on the list. Biopsy from the forearm lesion was taken and sent for histopathological examination.

Microscopically, sections showed thinned out epidermis with underlying clear grenz zone (Figure 1 b). Dermis and subcutaneous tissue revealed round to spindle shaped histiocytes arranged haphazardly and admixed with foamy macrophages (Figure 1 c). Focally spindle cells were arranged in whorled and criss-cross/storiform pattern.

Modified Fite-Faraco Stain for lepra bacilli showed numerous acid-fast lepra bacilli arranged in globi and scattered singly (Figure 1 d). The bacilli appeared as uniform solid stained, long rods with tapering ends with a bacterial index of 6+ and morphological index of >70%. Keeping in view the above clinical & histopathological features along with positive staining for acid fast bacilli a final diagnosis of '*de-novo*' histoid leprosy was rendered. The patient was further put on multibacillary multidrug therapy (MBMDT) and on regular follow-up.

\* Corresponding author.

E-mail address: [savreet87@gmail.com](mailto:savreet87@gmail.com) (N. Gupta).



**Fig. 1:** A-Nodular lesion over the right forearm **Figure B:** 100 X ( H & E stain) – showing epidermal atrophy with grenz zone **Figure C:** 400 X ( H&E stain) – Dermis showing round to spindle shaped histiocytes arranged haphazardly and admixed with foamy macrophages. **Figure D** 1000 X ( Fite-faraco stain) – showing lepra bacilli arranged in globi and scattered singly appearing as uniform solid stained long rods with tapering ends.

### 3. Discussion

The incidence of histoid leprosy among leprosy patients is estimated to be 2.79-3.60%. It shows male preponderance and an average age of diagnosis is 21-40 years.<sup>3</sup>

It is clinically characterised by cutaneous or subcutaneous nodules and papules which are painless, firm, discrete, smooth, globular, skin coloured to yellowish brown in appearance located on arms, buttocks, thighs, dorsum of hands, lower back and bony prominences.<sup>1</sup>

The lesions show characteristic histopathological features most important being its well circumscribed nature, abundance of spindle shaped and/or polygonal cells and a large number of acid fast bacilli. These lesions are most often located in dermis and/or subcutis surrounded by a pseudocapsule as a result of compressed adjacent tissue.<sup>1</sup> It further shows epidermal atrophy and an acellular band located below the epidermis (Grenz zone). The dermis consists of fusiform histiocytes arranged in whorled, criss-cross and storiform pattern, containing acid fast bacilli.<sup>4</sup>

Histoid leprosy is so called because the microscopic appearance of the nodule shows spindle shaped cells resembling those in dermatofibromas.

It can clinically mimic neurofibromas, xanthomas, dermatofibromas, reticulohistiocytosis and cutaneous metastasis. Each of these can be differentiated on the basis of histopathology, mycobacterial absence on slit skin smear and nerve thickening.<sup>5</sup>

No nerve thickening or anaesthetic lesions were seen in our case, which was probably the reason that the clinical diagnosis of histoid leprosy was lower down on the list of differential diagnosis. However, histopathological

examination revealed plenty of acid fast bacilli with bacterial index of 6+ confirming the diagnosis of histoid leprosy.

Palit and Inamdar have suggested that the histoid form of leprosy could serve as a reservoir of leprosy and as a source of new cases.<sup>6</sup>

Hence, a high index of suspicion for histoid leprosy is important for early diagnosis and treatment of these cases and for control of spread of the disease.

### 4. Conclusion

In the post elimination era of leprosy, a high index of suspicion is of utmost importance to continue surveillance for new and relapse cases and for their early diagnosis and treatment.

### 5. Source of funding

None.

### 6. Conflict of interest

None.

### References

1. Sehgal VN, Srivastava G, Singh N, Prasad VS. Histoid leprosy: the impact of the entity on the postglobal leprosy elimination era. *Int J Dermatol.* 2009;48(6):603–610. doi:10.1111/j.1365-4632.2009.03992.x.
2. Annigeri SR, Metgud SC, Patil JR. Lepromatous leprosy of histoid type. *Indian J Med Microbiol.* 2007;25(1). doi:10.4103/0255-0857.31069.
3. Kalla G, Purohit S, Vyas MC. Histoid, a clinical variant of multibacillary leprosy: report from so-called nonendemic areas. *Int J Leprosy Mycobact Dis.* 2000;68(3):267–271.
4. Murthy SV, Rao SM, Thejaswini KM. De-novo histoid leprosy. *J Lab Physicians.* 2011;3(2). doi:10.4103/0974-2727.86844.
5. Monga P, Mehta V, Balachandran C, Mathew M. Wade Histoid Leprosy masquerading as eruptive xanthomas. *Dermatol Online J.* 2008;14(8).
6. Palit A, Inamdar AC. Histoid leprosy as reservoir of the disease; a challenge to leprosy elimination. *Leprosy Rev.* 2007;78(1).

### Author biography

**Savreet Pal Singh** Post Graduate

**Anchal Bhola** Assistant Professor

**Neelam Gupta** HOD

**Avnika Jasuja** Assistant Professor

**Mehak Kashyap** Post Graduate

**Cite this article:** Singh SP, Bhola A, Gupta N, Jasuja A, Kashyap M. An unusual presentation of *De-novo* Histoid leprosy clinically mimicking as neurofibromatosis. *IP J Diagn Pathol Oncol* 2020;5(1):112-113.