



## Case Report

# Primary osteosarcoma of breast: A rare case report

Nirmal Daniel<sup>1</sup>, Anandraj Vaithy<sup>1</sup>, Shanmugasamy<sup>1</sup>, S Sowmya<sup>1,\*</sup>

<sup>1</sup>Mahatma Gandhi Medical College & Research Institute, Sri Balaji Vidyapeeth (Deemed to be University), Puducherry, India



### ARTICLE INFO

#### Article history:

Received 24-01-2020

Accepted 27-01-2020

Available online 29-02-2020

#### Keywords:

Breast malignancy

Primary osteosarcoma of breast

Mastectomy

Histopathology

### ABSTRACT

**Introduction:** Malignant Primary osteosarcomas of the breast are rare mammary sarcomas with aggressive potential. Unlike skeletal osteosarcomas which occurs in young adults, these tumors predominantly occur in the older age group. It is essential to clearly distinguish primary osteosarcomas of the breast from the common breast carcinomas since the treatment model for the former follows a multidisciplinary approach as for sarcomas affecting other anatomical locations.

**Case History:** A seventy year old female presented with swelling in the right breast since three years with progressive increase in size and mammographic evidence showing a well circumscribed dense lesion with focal calcification favouring fibroadenoma. While cytomears showed atypical cells obscured by haemorrhage, trucut biopsy showed malignant features with a possible differential of Phyllodes tumour and metaplastic carcinoma with osseous elements. Subsequent mastectomy was done and histology revealed a primary osteosarcoma of the breast. Primary osteosarcoma of breast is an extra -osseous manifestation which is diagnosed after excluding the possibility of primary from the underlying bones of sternum and rib, malignant phyllodes and metaplastic carcinoma. Considering the rarity of this entity we believe that each case can contribute to the improvement in the diagnosis and management of this disease.

© 2020 Published by Innovative Publication. This is an open access article under the CC BY-NC-ND license (<https://creativecommons.org/licenses/by/4.0/>)

## 1. Introduction

Breast carcinoma is one of the leading cancers among females of all ages.<sup>1</sup> Breast cancer is classified into various types depending upon their histogenesis which includes epithelial, fibroepithelial, mesenchymal tumors and lymphoma.<sup>2</sup> Among non-epithelial neoplasms, sarcomas of the breast are relatively common tumors with an incidence of 1 to 2 percent.<sup>3</sup> However, researchers observed that tumor incidence has been marginally increasing especially in tropical countries due to various attributable factors like radiation exposure and genetic mutations.<sup>4</sup> In contrast to skeletal osteosarcomas, primary osteosarcoma of the breast predominantly occurring in older patients is infrequently reported with less defined clinical features and treatment plans in literature.<sup>5</sup> Considering the rarity of this entity we believe that each case can contribute to the improvement in

the diagnosis and management of this disease.

### 1.1. Case Presentation

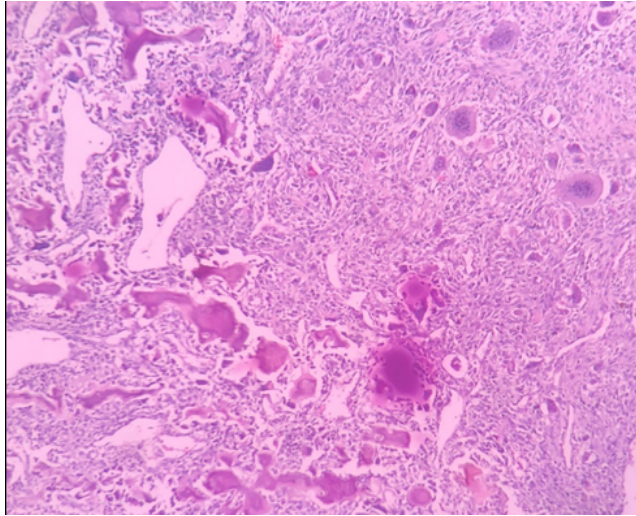
A 70year old female presented to Surgical OPD with a complaint of swelling in the right breast for a duration of 3 months. Clinical diagnosis was carcinoma of the breast and was referred for mammography which revealed a relatively well defined hyperdense mass with calcification warranting further evaluation. In view of clinical suspicion of malignancy, patient was subjected for trucut biopsy which revealed heterologous elements composed of atypical spindle cells, osteoid-matrix and occasional multinucleated giant cells suggesting the possibility of malignant phyllodes and metaplastic carcinoma (Figure 1).

Following the core needle biopsy report, the patient underwent Modified radical mastectomy. Grossly we received MRM specimen with attached axillary pad of fat measuring 22x18x8cm. Cut section revealed a single, solid grey-white,

\* Corresponding author.

E-mail address: [nirmaldaniel89@gmail.com](mailto:nirmaldaniel89@gmail.com) (S. Sowmya).

gritty, ill circumscribed tumor measuring 17x15x5cm with areas of cystic degeneration and calcification. The tumor was extending across the upper and lower quadrants and infiltrates the deep surgical resected margin (Figure 3).



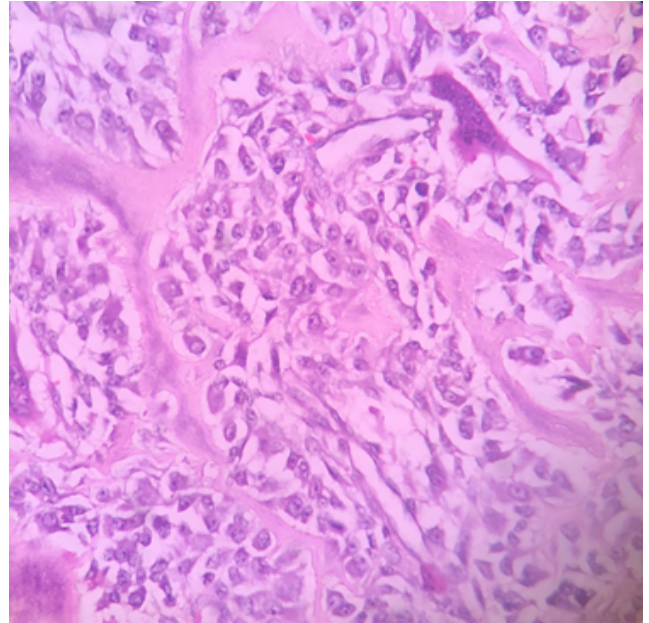
**Fig. 1:** Histology of trucut biopsy reveals admixture of sheets of spindle cells, osteoid matrix and occasional multinucleated giant cells (H&E, 10x)



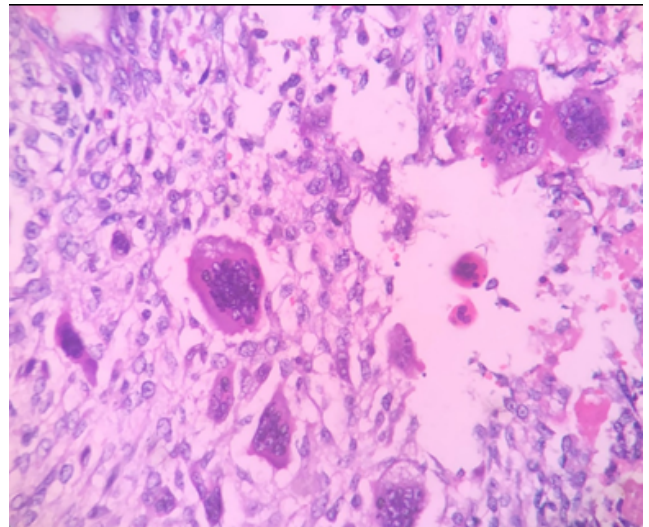
**Fig. 2:** MRM specimen- Cut section revealed a solid grey white mass with ill-defined margins and cystic degeneration

## 2. Discussion

Primary osteosarcoma of the breast accounts for <1% of all primary breast malignancies.<sup>1,2</sup> It is a highly aggressive tumor predominantly affecting elderly women.<sup>3</sup> The histogenesis of primary osteosarcomas of the breast is poorly understood.<sup>4,5</sup> Few notable risk factors include prior local irradiation, trauma and foreign body.<sup>6</sup> The present



**Fig. 3:** Tumour showing Atypical mesenchymal cells producing irregular lace-like osteoid matrix (H&E, 40x)



**Fig. 4:** Atypical mesenchymal cells with multiple osteoclast-like giant cells(H&E, 40x)

case had no risk factors in which case the carcinogenesis could be due to transformation of totipotent mesenchymal cells of the breast stroma.

To diagnose osteosarcoma of the breast based on clinical findings, mammogram and ultrasonography is a challenge. Mammographically it appears as well circumscribed dense lesions having regular or irregular borders with focal calcification sometimes mimicking a benign fibroadenoma.<sup>7</sup>

According to Allan and Soule<sup>8</sup> based on their clinicopathological study of 26 cases of Osteogenic sarcoma in somatic soft tissues, the basic requirement for the diagnosis of a primary osteosarcoma of the breast relies on :

1. The presence of neoplastic osteoid or bone
2. The exclusion of origin in the bone
3. The absence of epithelial component<sup>8</sup>

In addition to the above histomorphological features, immunohistochemical tests show positivity for the mesenchymal marker vimentin with absence of epithelial, neural, muscular and other markers.<sup>9</sup>

Due to the rarity of this entity and overlapping histological features, other malignant mimics such as Malignant phyllodes tumor and Metaplastic carcinoma should be ruled out. Malignant phyllodes tumor consists of admixture of a predominant malignant mesenchymal component and a benign epithelial component.<sup>10</sup> Multiple sections examined in the present case showed markedly pleomorphic spindle cells with lack of epithelial component. This ruled out the diagnosis of a malignant phyllodes tumor.

Metaplastic carcinoma is a rare heterogenous neoplasm characterized by admixture of variable proportion of malignant epithelial as well as mesenchymal component with apparent histologic and cytologic features on light microscopy and immunohistochemical testing.<sup>10</sup> Extensive sampling is the key to identify carcinomatous foci and distinguish from true sarcoma because of difference in the biological behavior and response to therapy.

A primary osteosarcoma of the bone arising from nearby ribs or sternum with direct extension is a possibility.<sup>11</sup> However, in the present case the tumor was not infiltrating through the chest wall musculature and no significant radiological evidence of a primary osteosarcoma of bone noted.

Osteosarcoma is classified into the subtypes namely, fibroblastic, osteoblastic and osteoclastic. Fibroblastic osteogenic osteosarcoma is the most common and is associated with better survival outcome which makes histological differentiation important. Early recurrence and propensity for hematogenous than lymphatic spread have been noted. The common sites for hematogenous metastasis are the lung (80%), bone (20%) and liver (7%).<sup>11</sup> Prognostic factors include tumor size, number of mitosis, histological subtype and the status of surgical resected margins.<sup>4</sup>

Limited data on osteosarcoma of the breast indicate an aggressive clinical course and high incidence of recurrence and metastasis. Surgical management is the mainstay of treatment. The role of adjuvant chemotherapy and radiotherapy is unclear at the moment in view of limited number of cases reported so far in the literature. But chemotherapy is the main treatment modality for metastatic disease.<sup>11</sup>

### 3. Conclusion

The prognosis of primary osteosarcoma of the breast is poor with increased incidence of recurrence and associated hematogenous spread to the lung. Histopathological diagnosis remains the cornerstone for treatment since a multidisciplinary approach entailing treatment strategies that follows the model of sarcomas affecting other locations and adjuvant chemotherapy necessary owing to the aggressive nature of the tumor.

### 4. Source of funding

None.

### 5. Source of funding

None.

### References

1. Bahrami A, Resetkova E, Ro JY, Ibañez JD, Ayala AG. Primary Osteosarcoma of the Breast: Report of 2 Cases. *Arch Pathol Lab Med.* 2007;131(5):792–795.
2. Going JJ, Lumsden AB, Anderson TJ. A classical osteogenic sarcoma of the breast: histology, immunohistochemistry and ultrastructure. *Histopathol.* 1986;10(6):631–641.
3. Lakhani SR. International Agency for Research on Cancer, eltggesundheitsorganisation, editors. WHO classification of tumours of the breast: views of a working group that convened for a consensus and editorial meeting at the International Agency for Research on Cancer (IARC), Lyon. vol. 10. Wiley ; 1986., p. 1–3. Lyon: Internat. Agency for Research on Cancer; 2012. 240 p. (World Health Organization Classification of tumours).
4. Silver SA. Primary osteogenic sarcoma of the breast: a clinicopathologic analysis of 50 cases. *Am J Surg Pathol.* 1998;22(8):925–933.
5. Yoon CS, Kang SS. Primary osteosarcoma of the breast: a case report. *Ann Surg Treat Res.* 2017;93(1):57–60.
6. Rizzi A, Soregaroli A, Zambelli C, Zorzi F, Mutti S, et al. Primary Osteosarcoma of the Breast: A Case Report. *World J Surg Oncol.* 2013;2013:1–3.
7. Harvey JA. Unusual breast cancers: useful clues to expanding the differential diagnosis. *Radiol.* 2007;42(3):683–694.
8. Allan CJ, Soule EH. Osteogenic sarcoma of the somatic soft tissues. Clinicopathologic study of 26 cases and review of literature. *Cancer.* 1971;27(5):1121–1133.
9. Ogundiran TO, Ademola SA, Oluwatosin OM, Akang EE, Adebamowo CA. Primary osteogenic sarcoma of the breast. *World J Surg Oncol.* 2006;11(4).
10. Altaf FJ, Mokhtar GA, Emam E, Bokhary RY, Mahfouz NB, et al. Metaplastic carcinoma of the breast: an immunohistochemical study. *Diagn Pathol.* 2014;9.
11. Nawarathna N, Kmarasinghe N, Ratnayake P, K SRJ. Primary osteosarcoma of the breast presenting as a large breast abscess. *Arch Med Health Sci.* 2016;4(1).

### Author biography

**Nirmal Daniel** Tutor

**Anandraj Vaithy** Associate Professor

**Shanmugasamy** Professor

**S Sowmya** Professor and HOD

**Cite this article:** Daniel N, Vaithy A, Shanmugasamy , Sowmya S. Primary osteosarcoma of breast: A rare case report. *IP J Diagn Pathol Oncol* 2020;5(1):104-107.