



## Case Report

# Warty dyskeratoma; A rare entity with involvement of multiple adjoining follicles

Neetu Bala<sup>1</sup>, Neelam Gupta<sup>1,\*</sup>, Neha Singh<sup>1</sup>, Girish Nandan<sup>1</sup>, Mandeep Sachdeva

<sup>1</sup>MM Medical College & Hospital, Kumarhatti-Solan, Himachal Pradesh, India



### ARTICLE INFO

#### Article history:

Received 15-12-2019

Accepted 27-12-2019

Available online 29-02-2020

#### Keywords:

Warty dyskeratoma

Cup shaped invagination

### ABSTRACT

Warty dyskeratoma is a rare epidermal tumor which occurs in middle aged or older persons, clinically manifests as papule or nodule and involves head and neck region in most of the cases. 65y F presented to the OPD with complaint of nodular swelling over the right cheek with itching for 15 years. On clinical examination patient had 3x1.8 cm nodule, firm in consistency, mobile, with ulceration over tumor. Routine investigations were within normal limits and Fine Needle Aspiration Cytology was reported as suspicious of malignancy. Histopathology of excised mass revealed hyperkeratotic, parakeratotic and acanthotic epidermis show large multiple invaginations comprising of lacunae along with villi formation. Stratum corneum and upper malpighi layer shows abundant dyskeratotic acantholytic cells. As per literature these changes are usually noticed in single hair follicle. Here we describe a rare case of warty dyskeratoma with multiple adjacent hair follicles involvement.

© 2020 Published by Innovative Publication. This is an open access article under the CC BY-NC-ND license (<https://creativecommons.org/licenses/by/4.0/>)

## 1. Introduction

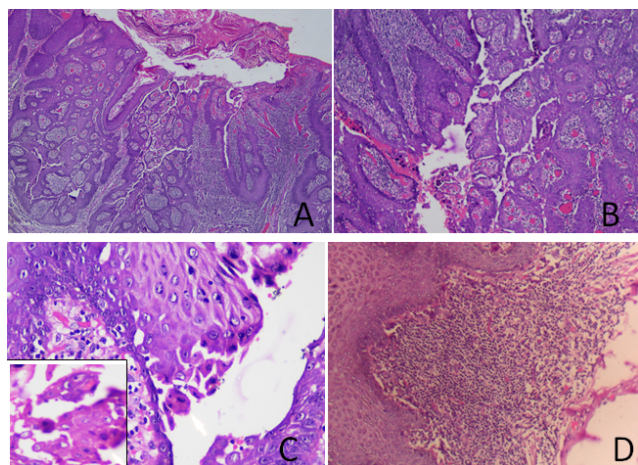
Warty dyskeratoma (WD) is an uncommon entity. It is an epidermal tumor which manifests as papule or nodule involving scalp, face and neck in most of cases.<sup>1</sup> In 1954 warty dyskeratoma was described as isolated darier's disease by Graham and Helwig.<sup>2</sup> Szymanski in 1957 explained this entity in a better way and described it as Warty Dyskeratoma.<sup>3</sup> WD shows a wider spectrum of morphologic features than previously recognized. Despite some histopathologic similarities to viral warts, WD is not a manifestation of HPV infection. Pathogenesis of this unusual lesion is still unknown.<sup>4</sup> Histologically characterized as acanthotic epidermis with large cup shaped invaginations comprising of lacunae along with villi formation. Stratum corneum and upper malpighi layer shows abundant dyskeratotic acantholytic cells.<sup>5</sup> These changes are almost always noticed in single hair follicle, but in our case multiple adjoining hair follicles were involved.

## 2. Case Report

65 y F presented with complaint of itching and swelling over right cheek for 10-12 years. Initially it was small in size and gradually increased. Overlying skin was showing focal ulceration. On examination she had firm to hard, mobile, well defined swelling over right cheek approximately 3x1.8 cm. Routine investigations were within normal limits and FNAC revealed few atypical cells and was reported as suspicious of malignancy. Histopathological examination of excised swelling revealed hyperkeratotic, parakeratotic and acanthotic epidermis with multiple adjoining hair follicles showing cup shaped invaginations filled with keratinous material. Each invagination show multiple lacunae along with villi formation. Stratum corneum and upper malpighi layer shows abundant dyskeratotic and acantholytic cells along with corps and ronds. Lower portion of epidermis exhibits multiple villi covered by single layer of basal epithelial cells. Papillary dermis is infiltrated by marked lymphoplasmacytic inflammatory cell infiltrate. On the basis of such clinical and histopathological findings diagnosis of Warty Dyskeratoma was made.

\* Corresponding author.

E-mail address: [neelamgupta353@gmail.com](mailto:neelamgupta353@gmail.com) (N. Gupta).



**Fig. 1:** **A.** Keratinized stratified squamous epithelium revealing hyperkeratosis, parakeratosis and acanthotic epidermis with large cup shaped invagination filled with keratinous material. **B** Lower portion of each invagination shows suprabasal clefts and villi. **C** Acantholytic and dyskeratotic cells in the lacunae. **D** Marked inflammatory cell infiltrate at dermo epidermal junction.

### 3. Discussion

Warty dyskeratoma is a unique entity, involves head and neck region most commonly and usually occurs in older age group. It is a benign epidermal proliferation and diagnosed most frequently by histopathological evaluation. Lesions are typically single, umbilicated or depressed with keratotic horn or plug and are slow growing. Oral involvement particularly the hard palate, eyelid and genital involvement have been reported.<sup>6,7</sup> Multiple lesions may occur in the same patient.<sup>8</sup>

On histopathological examination warty dyskeratoma is characterized by large cup shaped invagination filled with keratin plug, lower portion of each invagination shows suprabasal clefts and villi with acantholytic and dyskeratotic cells in the lacunae. Typical corps ronds are seen near the granular layer. Such features involve single hair follicles in almost all cases.<sup>1</sup>

Focal acantholytic dyskeratosis is not a histologic hallmark of WD. It is also observed in Darier's disease or transient acantholytic dermatosis;<sup>9</sup> some neoplasms such as acantholytic squamous cell carcinoma, actinic keratosis and basal cell carcinoma may present with similar histologic feature. In our case, the histopathological appearance of WD was so distinctive that Darier's disease and transient acantholytic dermatosis could be easily excluded. The lack of cellular atypia and specific morphological features did not support the diagnosis of squamous cell carcinoma, actinic keratosis or basal cell carcinoma.

Etiology of WD is not clear but certain factors such as viral infection, autoimmunity, UV light have been postulated to play a role. The treatment of choice of

WD is surgical excision, Curettage with electro-desiccation and irradiation with X-ray had been tried, but these were followed by recurrence. A case of successful treatment with tazarotenic acid gel has been reported.<sup>10</sup> In our patient, there was no evidence of recurrence after excisional biopsy.

In conclusion, we describe here a peculiar case of WD that involved multiple adjoining hair follicles within a solitary lesion.

### 4. Source of funding

None.

### 5. Conflict of interest

None.

### References

- Jang EJ, Lee JY, Kim MK, Yoon TY. Warty dyskeratoma involving two adjoining follicles. *Ann Dermatol.* 2011;23(1):98–100.
- Jh G, Eb H. Isolated dyskeratosis follicularis. *AMA Arch Dermatol.* 1958;77(4):377–389.
- Szymanski FJ. Warty dyskeratoma: a benign cutaneous tumor resembling Darier's disease microscopically. *AMA Arch Dermatol.* 1957;75(4):567–572.
- Kaddu S, Dong H, Mayer G, Kerl H, Cerroni L. Warty dyskeratoma-“follicular dyskeratoma”: analysis of clinicopathologic features of a distinctive follicular adnexal neoplasm. *J Am Acad Dermatol.* 2002;47(3):423–428.
- Rambhia KD, Makhecha MB. A case of warty dyskeratoma on an unusual location. *Indian Dermatol Online J.* 2019;10(3).
- Kaugars GE, Lieb RJ, Abbey LM. Focal oral warty dyskeratoma. *Int J Dermatol.* 1984;23(2):123–153.
- Duray PH, Merino MJ, Axiotis C. Warty dyskeratoma of the vulva. *Int J Gynecol Pathol Official J Int Soc of Gynecol Pathol.* 1983;2(3):286–293.
- Griffiths TW, Hashimoto K, Sharata HH, Ellis CN. Multiple warty dyskeratomas of the scalp. *Clin Exp Dermatol.* 1997;22(4):189–191.
- Giunta JL, Gomez LS, Greer RO. Oral focal acantholytic dyskeratosis (warty dyskeratoma): report of two cases. *Oral Surg, Oral Med. Oral Pathol.* 1975;39(3):474–478.
- Abramovits W, Abdelmalek N. Treatment of warty dyskeratoma with tazarotenic acid. *J Am Acad Dermatol.* 2002;46(2).

### Author biography

**Neetu Bala** Post Graduate Resident

**Neelam Gupta** Professor and HOD

**Neha Singh** Assistant Professor

**Girish Nandan** Post Graduate Resident

**Mandeep Sachdeva** Medical Officer

**Cite this article:** Bala N, Gupta N, Singh N, Nandan G, Sachdeva M. Warty dyskeratoma; A rare entity with involvement of multiple adjoining follicles. *IP J Diagn Pathol Oncol* 2020;5(1):102-103.