



Original Research Article

Surgical pathology of whipple pancreaticoduodenectomy: A 3-year experience at a tertiary cancer care center of marathwada region of India

Hemant R Kokandakar¹, Rakesh Kumar Ajmera^{1,*}, Syeda Muneza¹, Somesh Nilkanth¹, Ajay Boralkar¹, Anagha Varudkar¹

¹Dept. of Pathology, Government Cancer Hospital, Aurangabad, Maharashtra, India



ARTICLE INFO

Article history:

Received 30-01-2020

Accepted 04-02-2020

Available online 29-02-2020

Keywords:

Whipple's Resection

Pancreaticoduodenectomy (PD)

Circumferential resection margin (CRM)

Superior mesenteric artery (SMA) surface

Superior mesenteric vein (SMV) surface

Perineural invasion (PNI)

Lymphovascular invasion (LVI).

ABSTRACT

The aim was to study and analyze in detail various parameters of Whipple resection specimen.

Introduction: Whipple procedure is a radical surgery performed for operable tumors of ampullary-periampullary region, head of pancreas, common bile duct and duodenum. Pathologic assessment of Whipple's resection specimen needs special attention because of peculiar complex anatomy of head of pancreas and related structures, and also because of difference of opinion about grossing protocols of dissection of the specimen and confusion about terms like 'margins' and 'surfaces'

A histopathologist has to be aware of these intricacies so as to diagnose and accurately evaluate factors of prognostic importance.

This is the first major mono-center surgical pathology study of Whipple resections reported from Department of Oncopathology, Government Cancer Hospital, Aurangabad, a newly started state level cancer hospital serving patients from Marathwada region of Maharashtra, India.

Material and methods: This is surgical pathology study of total 31 (thirty one) cases of Whipple resections performed during 2017-19. All relevant histopathologic details pertaining to grossing, microscopic diagnosis, grading and staging, and histopathologic prognostic factors were comprehensively studied. Dissection and grossing was done as per the protocols followed at Tata Memorial Hospital Mumbai.

Results: Out of total 31 Whipple resections performed at this hospital, 01(one) was classical Whipple's PD, seventeen (17) were pylorus preserving pancreaticoduodenectomy(PPPD) and thirteen (13) were of extended pancreaticoduodenectomy resections.

The patients had age ranging from 38 to 76 years. There were 20 male patients and 11 female patients (M:F-2:1). As far as site of lesion is concerned 16(52%) cases had periampullary lesion. 06(19%) had lesion in head of pancreas, 07(22%) tumors were of common bile duct and there were 02(7%) cases of duodenal carcinoma. Histopathology revealed 29(94%) cases of malignant neoplasm and 02(6%) of benign lesion which included one(01) case of Brunner's gland hyperplasia with pancreatitis in adjacent pancreas, and the remaining 01 was of necrotizing pancreatitis (acute on chronic inflammation) with pseudocyst formation involving head of pancreas.

Pathological stage of most of the tumors (55%) was T3, followed by T1(25%) and T2(20%)

Amongst total 29 cases of malignant neoplasm, 08(28%) had well differentiated adenocarcinoma. 17 cases (58%) were of moderately differentiated adenocarcinoma and 02(7%) each were of mucinous carcinoma and neuroendocrine carcinoma.

Microscopic involvement of margin/surface (CRM) was noted in 05 (17%) cases. In three(03) cases SMA surface and in 02 posterior surface were involved. PNI was noted in 12(41%) cases and LVI in 05(17%) cases. Peripancreatic lymph node metastasis was seen in 05(17%) cases. Specimens of regional lymph nodes were received separately & were negative for deposits in all the cases. Retroperitoneal lymph nodes received along with specimen of Extended Whipple's were negative for metastasis in all the cases.

Comment: From this study we conclude that important prognostic factors were location, extension, pathologic stage, histologic grade, status of margins / surfaces, LVI, PNI, and lymph node status. Therefore pathologic assessment of surgical specimen of pancreaticoduodenectomy (Whipple resection) needs special attention to evaluate these factors. To fulfill this purpose there is need of evolving standardized grossing protocols as well as uniform terminology related to terms 'margin' & 'surface'.

© 2020 Published by Innovative Publication. This is an open access article under the CC BY-NC-ND license (<https://creativecommons.org/licenses/by/4.0/>)

1. Introduction

Pancreatic cancer ranks 12th most common cancer in the world. However compared to Western countries, relatively low incidence has been noted in India (rates ranging from 0.5-2.4/100000 person per year in females and 0.2-1.8/100000 persons per year in males). Symptoms related to pancreatic cancer are non specific leading to late detection and therefore poor outcome.¹ Due to relative rarity of this major radical operation usually there is less familiarity with the Whipple's specimen. In addition to that, complex anatomy of various structures related to head of pancreas and differing opinions about dissection and grossing protocols as well as lack of uniformity in identification of regions/landmarks as either "margin" or "surface" creates greater confusion. On this background surgical pathology study of pancreaticoduodenectomy requires understanding of complex anatomy of various structures related to head of pancreas. Proper grossing practices are essential for correct diagnosis as well as to assist staging, understand prognosis and plan for the management of the patient.

Therefore there is need of evolving consensus about standardization of the method of dissection of specimen of Whipple resection and grossing protocols as well as consistent approach towards deciding the use of terms like 'margin', 'circumferential margin(CRM)' and 'surface' so as to avoid confusion identifying them for proper tissue sampling.^{2,3}

We present surgical pathology findings of 31 cases of pancreaticoduodenectomy resections. We have adopted grossing protocols of Tata Memorial Hospital⁴ and discuss our findings.

2. Materials and Methods

This is a surgical pathology study of total 31 specimens of Whipple resection performed at Government Cancer Hospital Aurangabad during the period 2017 to 19. All the relevant histopathologic details related to dissection, grossing, microscopic diagnosis and grading -staging were comprehensively studied.

Three Types of pancreaticoduodenectomy (Whipple) resections were performed^{3,5}

Classical Whipple Pancreaticoduodenectomy in which specimen comprises of head of pancreas, duodenum, gall bladder and distal stomach. In a classic Whipple's resection, the pyloric antrum is transected. Therefore the specimen includes distal stomach and pylorus (along with whole of the duodenum). Jejunal segment may or may not be included en bloc.

Pylorus preserving Whipple resection is a modification of classical Whipple's in which duodenum is resected approximately 1-2 cm distal to the pylorus so as to preserve

the pylorus and therefore proximal 2-3 cm of duodenum, pylorus and stomach are not included in the specimen.

Extended Whipple resection: involves dissection of retroperitoneal and aorto-caval nodes.

Dissection and grossing of pancreaticoduodenal specimen was done as per guidelines of Tata Memorial Hospital Mumbai and Verbeke.^{2,4}

The specimen was oriented. The different components of specimen i.e. Stomach(in classical Whipple's), duodenum, pancreas, CBD, gallbladder, jejunum (if included) were identified and dimensions were noted. External surface was observed for any gross abnormality.

Transection margins (shave margins parallel to the resected ends) including proximal duodenal / stomach cut margin, distal duodenal/jejunal resection margin, pancreatic neck resection margin, CBD resection margin were submitted for microscopic examination. Sections from colectomy specimen (01 case) and right hepatectomy specimen (01case) were submitted. Before commencing grossing proper, external examination of head of pancreas for presence of any gross abnormality and important landmarks including those called as CRM (circumferential resectionmargins) or surfaces including anterior pancreatic surface, posterior pancreatic surface ,SMV surface, SMA surface were identified after proper orientation. Duodenum was cut along the outer curvature. If distal stomach was received (as in classical Whipple)it was opened along greater curvature continuing along the anterior wall of pylorus. Ampullary region was examined for presence of lesion and its dimensions and gross appearance were noted. After removing staples, multicolor inking was done.

2.1. Margins/ surfaces submitted were

Resected (transected margins) as mentioned earlier-CBD cut - margin, pancreatic neck cut margin, distal duodenal /jejunal cut margin, stomach/ duodenal proximal cut margin.

CRM (circumferential resection margin)/ surfaces- anterior pancreatic surface, Superior mesenteric artery (SMA) surface, Superior mesenteric vein(SMV)surface, posterior pancreatic surface.

The head of the pancreas was cut by serial axial slicing by cuts perpendicular to long axis of duodenum (bread loaf pattern). Site of tumor was noted- ampullary/ periampullary, head of pancreas, CBD or duodenum. Tumor size and status of adjacent tissues was noted. At least 4(four) sections from lesion with ampulla with CBD and with pancreatic head were submitted. Sections were also submitted from adjacent duodenum, adjacent pancreas and adjacent CBD. Sections from gallbladder and cystic duct and jejunum (one case), stomach (classical PD) were submitted.

* Corresponding author.

E-mail address: drakeshajmera@yahoo.in (R. K. Ajmera).

2.2. Lymph node submission

Peripancreatic lymph nodes included lymph nodes dissected from anterior and posterior pancreaticoduodenal group, Infra pyloric group, SMA lymph nodes, SMV lymph nodes, pericholedochal (uncinate), anterior, superior, inferior lymph nodes were dissected. At least 12 to 15 lymph nodes were examined. Dissection of peripancreatic lymph nodes was done after orientation of the specimen and before sectioning of the pancreatic head. Specimen of regional lymph nodes labeled speriportal group, hepatoportal group, hepatoduodenal and lymph nodes along hepatic artery were received separately. In cases of extended PD retro peritoneal lymph nodes and aortocaval lymph nodes were received separately.

3. Results

Of the total 31 specimens of Whipple resections we had received, 17(55%) specimens were of pylorus preserving pancreaticoduodenectomy, 13(42%) of extended Whipple's and 1(3%) was of classical Whipple's.

The specimen of classical pancreaticoduodenectomy (in which distal gastrectomy specimen was received as expected) revealed growth in head of pancreas and hemicolectomy specimen was also received along with it. Out of 13 cases of , 07 had periampullary carcinoma, 04 had CBD carcinoma and both the remaining cases had duodenal carcinoma. One (01) of the cases of extended pancreaticoduodenectomy having tumor of CBD had gross metastatic deposits in liver hence right hepatectomy was also done.

Of the 17 cases of PPPD, 09 had periampullary lesion, 05 had lesion in pancreas and 03 had neoplasm in CBD. As expected proximal 2- 3 cm of duodenum and distal stomach were not received in these specimens. In one(01) case of PPPD, part of jejunum was also received en bloc.

The patients had age ranging from 38 to 76 years. There were 20 (66%) male patients and 11(33%) female patients with M:F:: 2 : 1

Of the total 31 specimen of Whipple resections, 16(52%) had periampullary lesion, 07 had carcinoma of common bile duct, 06(19%) had lesion in head of pancreas and 02(7%) were having duodenal carcinoma

In the present study, peripancreatic lymph nodes were found to have metastasis in 05 out of total 29(17%) cases of malignant neoplasm. All the lymph nodes from samples of retro peritoneal group of lymph nodes received in all cases of Extended Whipple's were free of metastasis.[Table 1]

3.1. Periampullary lesions

In the present study there were 16(sixteen) cases of periampullary lesion, of which 09 had undergone pylorus preserving pancreaticoduodenectomy (PPPD) and 07 had extended Whipple resection. Age of patients were between

42 to 76 years with M:F::1.2 :1. Mean tumor size was 2.5 cm. Histopathology revealed 15 cases of malignant neoplasm (08 well differentiated adenocarcinoma, 05 moderately differentiated adenocarcinoma and 02 mucinous carcinoma) and 01 of Brunner's gland hyperplasia with adjacent pancreatitis.

Of the 15 cases of carcinoma, 06 had pathologic tumor stage of T1 followed by T3(05 cases) and T2 (04 cases)

In two (02) cases SMA surface and in one (01) case posterior surface had microscopic foci of tumor (R1). Perineural invasion was noted in 04 cases periampullary carcinoma and lymphovascular invasion was noted in 02 cases.

Of the total 15 malignant neoplasms of periampullary region, 02 cases had peripancreatic lymph node metastasis with extranodal extension. Both of these had PNI as well as LVI. One case with PNI as well as LVI and one case with only PNI did not have lymph node metastasis. None of the cases of neuroendocrine carcinoma had PNI, LVI or lymph node metastasis. None of the 07(seven) cases of periampullary carcinoma which underwent Extended Whipple's had retroperitoneal lymph node metastasis. Gallbladder and cystic duct were free in all the cases.

3.2. Lesions of Head of Pancreas

In the present study, 06 cases had lesion in head of pancreas. Ages of the patients were between 47 to 65 years. All the 06 cases were male patients. Amongst total 06 lesions of pancreatic head, 05 had pylorus preserving pancreaticoduodenectomy, one(01) was of classical Whipple (which included distal gastrectomy). In case of classical Whipple's resection, hemicolectomy was also performed. On gross and histopathology, hemicolectomy specimen including resected margins was free of tumor. Of the five cases which had undergone PPPD, four (04) had moderately differentiated carcinoma and one(01) had necrotizing pancreatitis (acute-on-chronic) with pseudocyst formation. Mean tumor size was 5.26cm. Tumor was solid in 4 out of 5 cases of malignant neoplasms and solid cystic in one(01) case. 03 cases had T3 tumor and 02 had T2 tumor. Amongst 05 cases of malignant neoplasm, 03 had moderately differentiated adenocarcinoma and 02 had mucinous carcinoma (one each of well and moderately differentiated). Perineural invasion was noted in 03 cases and LVI in one(01) case. Of the total 05 cases of pancreatic head carcinoma, 01 had peripancreatic lymph node metastasis. The case with lymph node metastasis had PNI as well as LVI. Remaining case with PNI did not have lymph node metastasis. Only one of the cases of pancreatic head carcinoma had microscopic involvement of SMA surface. Gallbladder and cystic duct were free of tumor in all cases.

Table 1: Detail Findings of Pancreaticoduodenectomy

	Periampullary n=16	Pancreatic Head n=6	CBD n=7	Duodenum n=2
Operation				
i- Classical Whipple (n=1)	0	1	0	0
ii- PPPD (n=17)	9	5	3	0
iii- Extended Whipple (n=13)	7	0	4	2
Histo type				
i -WD AdenoCa (n=8)	8	0	0	0
ii-MD AdenoCa (n=17)	5	3	7	2
iii-Mucinous Ca (n=2)	0	2	0	0
iv-Neuroendocrine Ca (n=2)	2	0	0	0
v-Brunner's Gland Hyperplasia with Pancreatitis (n=1)	1	0	0	0
vi-Pancreatitis (n=1)	0	1	0	0
Details of Malignant Neoplasm (n=29) *				
Age in yrs	42-76	47-65	38-70	47-56
Sex (M:F)	1.2:1	01:00	1.3:1	1.0:1.0
Mean Tumor Size in cm	2.5	5.26	2.5	5.5
Tumors Stage T1	6	0	1	0
Tumors Stage T2	4	2	0	0
Tumors Stage T3	5	3	6	2
PNI (n=12)	4	3	4	1
LVI (n=5)	2	1	2	0
Metastasis				
i-Peripancreatic LN (n=5)	2	1	2	0
ii-Regional LN (n=0)	0	0	0	0
iii-Retroperitoneal LN (n=0)	0	0	0	0
iv-Hepatic Mets (n=1)	0	0	1	0
CRM involved (n=5)	3(SMA 2, Post 1)	1(SMA)	1(Post)	0

* remaining 2 cases are having benign / inflammatory histopathology

3.3. Lesions involving common bile duct(CBD)

Total 07 cases had tumor arising from common bile duct. In one of these cases, tumor was extending into cystic duct. Age of patients was between 38 - 70 years. Male:female ratio was 1.33:1. Mean tumor size was 2.5 cm. Extended Whipple's resection was performed in 04 cases and 03 had undergone PPPD. All the cases of CBD lesion on histopathology had moderately differentiated adenocarcinoma. 05 cases had T3 tumor and one (01) each had T1 and T2 tumor. Perineural invasion was noted in 04 cases and lymphovascular invasion in 02 cases. Peripancreatic lymph node metastasis was noted in two cases. Of these two (02) cases with lymph node metastasis, one (01) had evidence of LVI, PNI and microscopic involvement of posterior surface. The remaining case had PNI only and margin /surfaces were free. One (01) case of adenocarcinoma of CBD which had only PNI and only tumor emboli did not have lymph node metastasis. In one case of PPPD, part of jejunum was resected which was free of tumor. In one of the cases which had undergone extended

Whipple's resection, right hepatectomy was performed. The hepatectomy specimen was of size 14 x 10 x 7 cm with growth of size 7 x 7 x 5 cm. Histology revealed metastatic deposits of adenocarcinoma.

3.4. Lesions involving duodenum

There were two(02) cases of duodenal adenocarcinoma. Both the patients were of 56 years of age and one was male and the other female. Both the cases of duodenal carcinoma had undergone extended Whipple's resection. Mean tumor size was 5.5cm. Both cases had T3 tumor. On gross, tumor was not involving ampullary region. One had circumferential ulceroproliferative growth. Both the cases had moderately differentiated adenocarcinoma. PNI was noted in one case and none had LVI. None of the cases had lymph node metastasis in peripancreatic, regional or retro peritoneal group of lymph nodes. Gallbladder, common bile duct, all margins and surfaces were free of tumor in both the cases.

3.5. Histopathology findings

Histopathology revealed 29 (94%) cases of malignant neoplasm and 02(6%)of benign lesions. Amongst 29 cases with malignant neoplasms, 17(58%) were of moderately differentiated adenocarcinoma followed by 08(28%) of well differentiated adenocarcinoma and 02(7%) each of mucinous carcinoma and neuroendocrine carcinoma. Of the two cases with benign /non-neoplastic lesions, there was one (01) case of mass like Brunner gland hyperplasia [Figure 1] involving ampullary region with necrotising pancreatitis in the adjacent pancreatic tissue. Pseudo cyst formation was seen. Adjacent duodenal wall revealed foci of Brunner's gland hyperplasia.

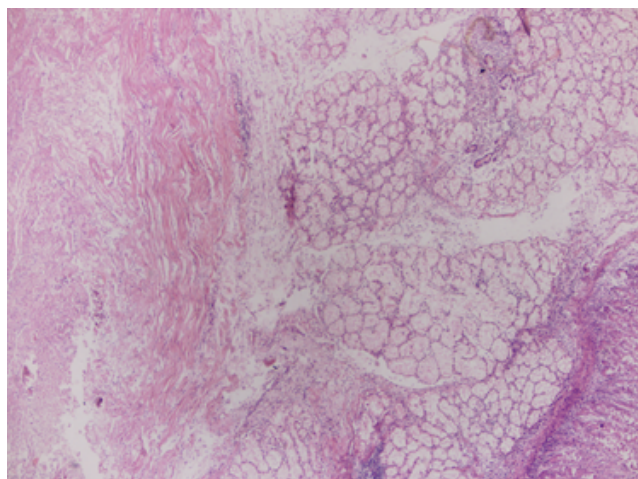


Fig. 1: Brunner's gland hyperplasia

One case of pancreatitis was involving head of pancreas with cystic change (pseudocyst formation). Large areas of necrosis and inflammatory cell infiltrates of lymphocytes, plasma cells, neutrophils and eosinophils indicating acute on chronic inflammation were seen. All the 28% cases of well differentiated adenocarcinoma were involving periampullary area. Amongst the cases of moderately differentiated adenocarcinoma, all the cases of carcinoma of CBD and duodenum as well as 05 out of 16 cases of periampullary carcinoma and 03 out of 06 cases of pancreatic head carcinoma had moderately differentiated adenocarcinoma. Both cases of neuroendocrine carcinoma were involving periampullary region and both the cases of mucinous carcinoma were arising from pancreatic head.

One case of well differentiated carcinoma had few small foci of squamous differentiation.[Figure 2] The foci of squamous differentiation were very small and not accounting to 30% of the tumor hence the tumor was reported as adenocarcinoma with squamous differentiation & not as adenosquamous carcinoma.

One case of moderately differentiated adenocarcinoma of common bile duct had focus of intraluminal papillary growth. [Figure 3]

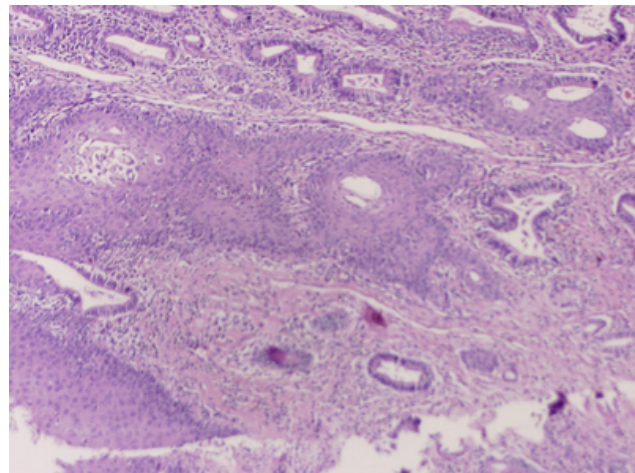


Fig. 2: Adenocarcinoma with squamous differentiation.

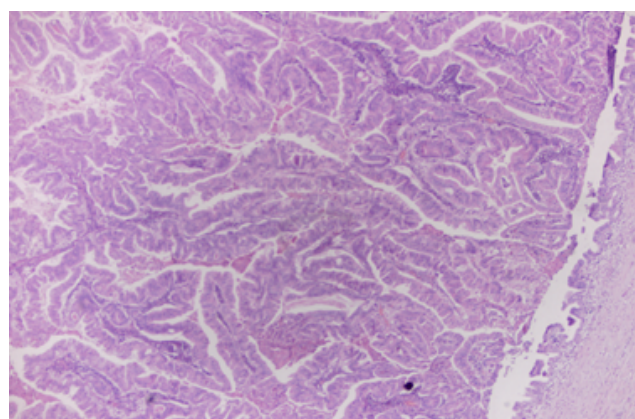


Fig. 3: A case of invasive adenocarcinoma with intraluminal papillary growth.

None of the cases of periampullary carcinoma had histological pattern of pancreatobiliary carcinoma

3.6. Histopathologic predictive and prognostic factors(PNI, LVI, lymph node metastasis, involvement of margins/surface, pathologic stage of tumor & histologic grade)

None of the cases who underwent extended Whipple's had metastasis in retroperitoneal oraortocaval lymph nodes.

Of the total 05 cases with peripancreatic lymph node metastasis, 04 were of moderately differentiated carcinoma and 01 was of well differentiated carcinoma. Primary site wise distribution was- periampullary carcinoma 02 cases, CBD carcinoma 02 cases and pancreatic head carcinoma 01 case. Both the cases of neuroendocrine carcinoma (both involving periampullary region) and both the cases of mucinous carcinoma (involving pancreatic head) did not have lymph node metastasis.

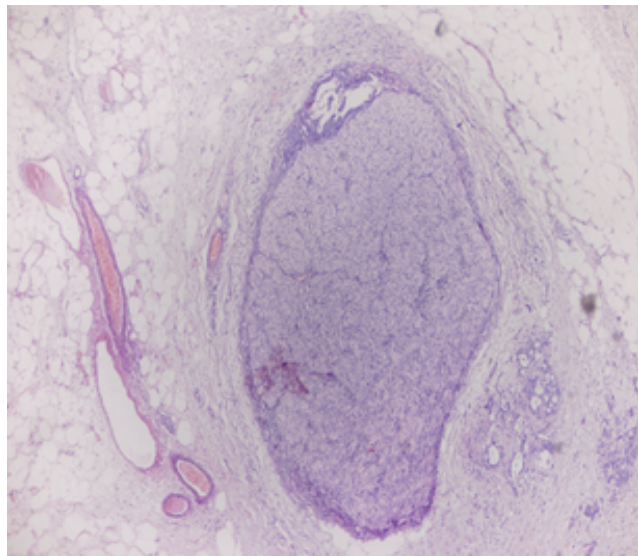


Fig. 4: Perineural invasion [PNI]

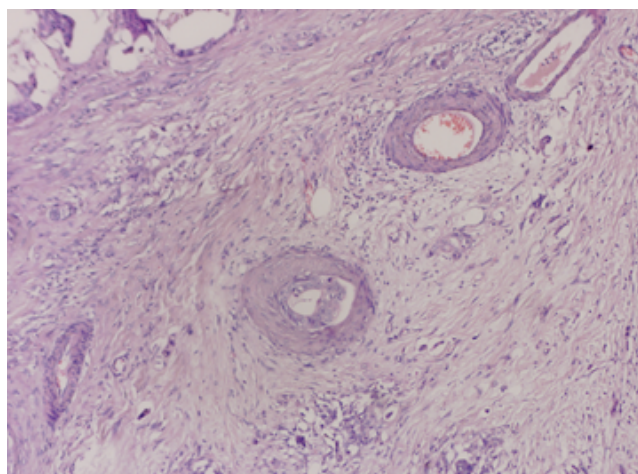


Fig. 5: Lymphovascular invasion [LVI]

Of the five (05) cases having lymph node metastasis, 03 cases had PNI as well as LVI, and 02 cases had PNI only.

CRM / surfaces in 05 cases were found to have microscopic foci. SMA surface was involved in 03 cases (02 having periampullary carcinoma and 01 with pancreatic head carcinoma.) Posterior margin was found to be involved microscopically in two cases (one each of periampullary carcinoma and carcinoma of CBD).

Of the 03 cases with SMA surface involvement, 02 were of periampullary & 01 was of pancreatic head carcinoma. Two of these had PNI. None of these three had lymph node metastases.

Of the 02 cases with involvement of Posterior pancreatic surface, both were of CBD carcinoma, both had PNI, one had LVI & both had Peripancreatic lymph node metastases.

One case each had only LVI and only SMA surface involvement.

Of the total 12 cases with PNI, 05 cases with LVI and 05 cases with lymph node metastasis, majority (13) had tumor with pathologic stage T3.

Of all the eight (08) cases of well differentiated adenocarcinoma only one (01) had PNI and lymph node metastases. Amongst seventeen (17) cases of moderately differentiated adenocarcinoma, 11 had PNI, 05 had LVI and 04 had lymph node metastases.

4. Discussion

In the present surgical pathology study of cases of Whipple's resection, overall M:F ratio was 2:1. Similar findings were noted by Yeo et al,⁶ Michelassi et al,⁷ Forough Foroughi et al.⁸ However Ibrahim Shifa and Meena Kumari⁹ quote equal sex incidence. In our study equal sex incidence was seen for cancers of periampullary region.

Periampullary region was the most common (52%) site involved in the present study. Similar finding was noted by many authors.⁶⁻⁹ Of the total 31 specimens, 29(94%) had malignant neoplasm and only 02(6%) had non-neoplastic/benign / inflammatory lesion as quoted by many authors⁶⁻⁹

4.1. Malignant neoplasms

Amongst 29 cases of malignant neoplasms, mean tumor size noted for ampullary carcinoma as well as for carcinoma of CBD was 2.5 cm. Mean tumor size noted for cancer of head of pancreas was 5.26 cm and that for duodenal carcinoma was 5.5 cm. The pathological stage of majority of the tumors (52%) was T3 followed by T1 (24%), T2 (21%) and T4 (3%). Foroughi F. et al⁸ also found 50% of their cases of carcinoma having T3 stage. This indicates late detection of the malignant lesion and therefore they recommended more precise evaluation of clinical signs and symptoms for early detection so as to increase the resectability of the tumor. Shrikhande et al¹ also emphasized that symptoms related to pancreatic cancer are nonspecific hence lead to late detection and poor prognosis. Our findings of ampullary carcinoma having almost equal number of cases of T1(06 cases) and T3 (05 cases) were found to be similar as that of Ibrahim Shifa and Meena Kumari⁹.

4.2. Predictive / Prognostic histopathologic factors

In the present study amongst the total 05 cases with lymph node metastases, all had PNI, 03 had LVI, 02 had involvement of posterior pancreatic surface & all had T3 pathologic stage of tumor. None of the cases with involvement of SMA surface had lymph node metastases. [Table 2]

Perineural invasion (PNI), lymphovascular invasion (LVI), loco regional lymph node metastasis, pathologic stage of tumor and microscopic assessment

Table 2: Predictive and prognostic histopathologic factors

Site	PNI(n=12)	LVI(n=05)	Margin/surface (n=05)	Lymph nodes(n=05)	T status
CBD	+	+	Posterior pancreatic surface +	N1	T3
Periampullary	+	+	-	N1	T3
Periampullary	+	+	-	-	T3
Head of pancreas	+	+	-	N1	T3
Head of pancreas	+	-	SMA surface +	-	T2
Head of pancreas	+	-	-	-	T3
Periampullary	+	-	-	-	T3
CBD	-	+	-	-	T3
CBD	+	-	Posterior pancreatic surface+	N1	T3
Duodenum	+	-	-	-	T3
CBD	+	-	-	-	T3
Periampullary	+	-	-	N1	T3
Periampullary	+	-	SMA surface +	-	T3
Periampullary	-	-	SMA surface +	-	T3

Perineural invasion (PNI), lympho vascular invasion (LVI), Common bile duct (CBD)

of margin / surface have been said to be the important predictive factors of risk of recurrence and important prognostic factors by many authors.^{2,10-12} Lymphovascular or perineural tumor spread indicates risk of regional tumor spread and involvement of loco regional lymph node metastasis. Microscopic involvement of resection margins has been said to be associated with poor prognosis. However there are debates and controversies regarding involvement of resected margin and their significance as far as the overall survival benefit is concerned in margin negative resection. Earlier definition of microscopic negative margins differed, according to American pathologists, meaning of negative margin was absence of tumor cells at inked margin and that for many European authors negative margin was absence of tumor cells within 1 mm of resection margin.^{2,10-12} However, the CAP guidelines,¹³ June 2017 mention that the presence of tumor at or within 1mm of resection margin constitutes a positive margin. Significant decreased survival has been reported in patients with SMA or SMV surface / margin involvement on microscopy as compared to margin negative resections and also that microscopic involvement of SMA margin has been said to have more impact on survival than that of microscopic involvement of SMV margin.¹¹ Shrikhande et al¹, in the “Indian Council of Medical Research Consensus Document for management of pancreatic cancer” emphasize the importance of complete resection with microscopically negative margins (Ro resection) for cure in patients with resectable pancreatic cancer.

Histopathologic grade has been shown to have prognostic significance. Cases with high grade carcinoma have been said to have relatively less favorable prognosis.¹³ Of all the eight (08) cases of well differentiated adenocarcinoma only one (01) had PNI and lymph node metastases. Amongst seventeen (17) cases of moderately differentiated

adenocarcinoma, 11 had PNI, 05 had LVI and 04 had lymph node metastases. This indicates that, the degree of differentiation/ grade of the tumor may influence the prognosis. One case of well differentiated carcinoma with few small foci of squamous differentiation did not have PNI, LVI or lymph node metastases. The case of moderately differentiated adenocarcinoma with element of intra luminal papillary growth had PNI but did not have LVI or lymph node metastases.

Ampullary / Periampullary carcinomas on histology are typed as intestinal or pancreatobiliary type by some authors.^{9,14} They conclude that pancreatobiliary type of histologic pattern is an independent poor prognostic factor. None of our cases had pancreatobiliary type of histological pattern.

4.3. Benign lesions

Of the total 31 specimen of Whipple’s resection only 02(6%) had non-neoplastic / benign / inflammatory lesion. Amongst these 02 cases, 01 was having Brunner’s gland hyperplasia involving ampullary-periampullary region with adjacent pancreatitis and the remaining 01 case had necrotising pancreatitis (acute on chronic inflammation) involving head of the pancreas. Kavanagh et al¹⁵ (2008) have found about 7% of benign lesions amongst the surgical specimens of Whipple’s resection and Adsay³ et al (2014) have quoted 5% cases of benign lesions. However this percentage is quoted higher by Foroughi et al⁸ (13.7%) and Shifa and Meena Kumari⁹ (20%). Yeo et al⁶ have reported 32% of benign lesions amongst analysis of 650 cases of Whipple’s resection. Adsay et al (2014)³ noted that many of the ‘pseudo tumors’ found in their study had paraduodenal (groove) pancreatitis. Sakorafas et al¹⁶ (2000) reviewed 484 consecutive cases of chronic pancreatitis treated surgically, of which 105 (22%) had undergone Whipple’s

resection. They conclude that Whipple's resection should be done when a malignant neoplasm must be excluded. Sakorafas et al¹⁶ (2000) further say that if malignant neoplasm is suspected and in spite of that if sub-total resection of pancreatic head is performed, and if it reveals malignant neoplasm it may indicate violation of oncological principles. Shyr et al¹⁷ (2003) reported two cases of Whipple surgery for suspected cancer which on histology revealed cholesterol polyp in CBD in one case and other had ampullary ectopic gland hyperplasia. In the present study one case had Brunner's gland hyperplasia involving periampullary region with adjacent pancreatitis. Brunner's gland hyperplasia at ampulla of Vater is rare. By the year 2006, two cases of ampullary Brunner's gland hyperplasia in Whipple's specimen were reported. (Mayoral et al 2000¹⁸, S E Janes et al 2006)¹⁹. S E Janes et al¹⁹ (2006) mention about the association of Brunner's gland hyperplasia with H. pylori infection, chronic pancreatitis and uremia. Yarandi S S et al²⁰ (2014) report an exhaustive 10 year study of 870 cases in which they had attempted to understand the effect of EUS (Endoscopic Ultra sonography)/FNA & ERCP on prevalence of benign lesion in patients that have undergone Whipple resection for suspicion of malignancy. They state that in spite of addition of ERCP, EUS/FNA to the existing presurgical selection criterion (like clinical score, CA 19-9 levels etc.) about 10% Whipple specimen reveal benign lesion.

4.4. Duodenal tumors

In the present study two cases had duodenal adenocarcinoma and both were arising from second part of duodenum. Both had moderately differentiated adenocarcinoma and tumor stage T3. One case had evidence of PNI but did not have LVI, lymph node metastasis or microscopic involvement of resected margins and/ or surfaces. The other case did not have evidence of any of these poor prognostic markers. Both the cases had undergone extended Whipple's resection and retroperitoneal lymph nodes were negative for metastasis in both the cases.

Duodenal adenocarcinoma is rare consisting only around 1% of all gastrointestinal tumors. The majority of duodenal adenocarcinomas arise in second part of duodenum and are very rare in the first part. Duodenal adenocarcinoma arising from the second part of duodenum may require pancreaticoduodenectomy. The prognostic factors include distant metastasis, lymph node metastasis, grade of tumor, tumor stage (T) margin status, presence of LVI and /or PNI and overall stage. (Goldner B and Stabile BE 2014,²¹ Jordan M Cloyd et al 2016²², Lopez- Domibguez Jetal, 2019²³).

Protocols of dissection and grossing

Proper grossing practices are essential for correct diagnosis as well as to assist staging, understand prognosis and plan for the management of the patient.

The protocol of grossing and dissection which we follow is based on the guidelines of Tata Memorial Hospital Mumbai⁴

Careful gross examination and meticulous sampling are essential to separate tumors as per their site of origin because cancers of ampulla, head of pancreas, CBD, and duodenum behave biologically different. However it may not be possible to identify origin of the lesion because of the complex anatomy of the region and involvement of more than one anatomic site by the tumor.⁴ Histopathologic diagnosis therefore is a process that includes steps like proper dissection, grossing protocols, tissue sampling, microscopic examination and standard reporting of findings.

As far as transection /resection margins are concerned there is consensus about the margins like pancreatic neck cut margin, CBD cut margin, stomach / duodenal cut margin, however differences remain about 'circumferential resected margin' (CRM) used by Verbeke and Menon² and the 'surfaces' or 'margin' used by Adsay et al.³

The term CRM used by Verbeke and Menon² includes anterior surface, posterior surface, SMV surface and SMA surface. Thus Verbeke² on one hand call it CRM that is a margin and include the areas with suffix of 'surface' creating confusion about use of the term 'margin' and 'surface'. The term 'CRM' Verbeke² further advocate serial axial sectioning (bread loaf like) of pancreatic head and do not advocate longitudinal opening of pancreatic duct/ bile duct of head along the probe so as to keep surface CRM intact. They think axial slicing is easy to perform, independent of location and nature of the lesion and easy to understand the relation of the lesion and adjacent anatomical structures. They quote high R1 rate of more than 75% with this method because each slice can provide CRM for examining almost all parts of CRM. Photo-documentation of slices is advocated by them.

Tissue sampling from anterior surface is recommended by them because presence of tumor cells at anterior surface increases the risk of recurrence. Chang et al¹⁰ (2009) consider anterior / serial margin as surface and not surgical resected margin. Adsay et al³ call it as anterior free margin.

Contrary to Verbeke & Menon², Adsay et al³ advocate probing of pancreatic duct and CBD and bisecting the pancreatic head for proper staging of ampullary carcinoma which they divide into four distinct categories – IAPN (Intra ampullary papillary neoplasm) associated carcinoma, ampullary ductal carcinoma, ampullary duodenal carcinoma and ampullary carcinoma not otherwise specified. (NOS). They state that bifurcating the pancreatic head gives better documentation of periampullary extension and gives better access to the ordinal / groove area as compared to serial axial slicing which fails to document spread to the group area. About the terms surface and margin their (Adsay et al³) approach is to call surgically- manually dissected compartments as "margins" and those that are covered with

serosa and come off easily as "free surfaces", for example they prefer term 'margin' for posterior inferior aspect of uncinate process i.e. uncinate margin and call posterior right aspect of pancreatic head as posterior 'free surface'.

Therefore it is felt that there is need of standardization of protocols of grossing of pancreaticoduodenal specimen as well as uniformity in using the terms 'margin' and 'surface' so as to avoid the confusion created by plethora of terms.

Adsay et al³ have advocated shaving off all the free surfaces of pancreatic head which is likely to have lymph nodes (orange peeling approach). Even if some of the sections submitted do not yield lymph nodes, they serve as peripancreatic soft tissue samples for search of microscopic foci of carcinoma.(T3)

5. Conclusion

Whipple's pancreaticoduodenectomy (PD) is a radical surgery performed for resectable tumors arising from head of pancreas and the structures related to it, with the goal to achieve microscopically negative surgical margins (R0 resection). Therefore pathologic assessment of surgical specimen of PD needs special attention to carefully evaluate resected margins, CRM as well as assess some important pathological predictive /prognostic factors. From this study we conclude that important prognostic factors were location, extension, pathologic stage, histologic grade, status of margins / surfaces, LVI, PNI, and lymph node status. Therefore pathologic assessment of surgical specimen of pancreaticoduodenectomy (Whipple resection) needs special attention to evaluate these factors. To fulfill this purpose there is need of evolving standardized grossing protocols as well as uniform terminology related to terms 'margin' & 'surface' for proper tissue sampling .

6. Source of funding

None.

7. Conflict of interest

None.

References

- Shrikhande S, Barreto S, Sirohi B, Bal M, Shrimali R, et al. Indian council of medical research consensus document for the management of pancreatic cancer. *Indian J Med Paediat Oncol.* 2019;40(1). doi:10.4103/ijmpo.ijmpo_29_19.
- Verbeke CS, Menon KV. Redefining resection margin status in pancreatic cancer. *HPB.* 2009;11:282–289. doi:10.1111/j.1477-2574.2009.00055.x.
- Adsay NV, Basturk O, Saka B, Bagci P, Ozdemir D, et al. Made Simple For Surgical Pathologists: Orientation, Dissection, and Sampling of Pancreaticoduodenectomy Specimens For a More Practical and Accurate Evaluation of Pancreatic, Distal Common Bile Duct, and Ampullary Tumors. *Am J Surg Pathol.* 2014;38(4):478–493.
- Desai SS, Bal M, Rekhi B, Jambhekar NA. Grossing of Surgical Oncology Specimens A practical guide towards complete pathology reporting. Mumbai,India: Department of Pathology. Tata Memorial Centre, Mumbai ; 2011,...
- Nakao A, Takeda S, Sakai M, Kaneko T, Inoue S, et al. Extended Radical Resection Versus Standard Resection for Pancreatic Cancer. *Pancreas.* 2004;28(3):289–292. Available from: <https://dx.doi.org/10.1097/00006676-200404000-00014>. doi:10.1097/00006676-200404000-00014.
- Yeo CJ, Sohn TA, Cameron JL, Hruban RH, Lillmoen KD, et al. Periapillary Adenocarcinoma: Analysis of 5-Year Survivors. *Ann Surg.* 1998;227(6):821–831.
- Michelassi F, Erroi F, Dawson PJ, Pietrabissa A, Noda S, et al. Experience with 647 Consecutive Tumors of the Duodenum, Ampulla, Head of the Pancreas, and Distal Common Bile Duct. *Ann Surg.* 1989;210:544–556. Available from: <https://dx.doi.org/10.1097/0000658-198910000-00015>. doi:10.1097/0000658-198910000-00015.
- Foroughi F, Mohsenifar Z, Ahmadvand A, Zare K. Pathologic findings of Whipple pancreaticoduodenectomy: a 5-year review on 51 cases at Taleghani general hospital ;.
- Ibrahim SS. Analysis of Whipple's Resection Specimens: A Histopathological Perspective. *Ann Pathol Lab Med.* 2016;03(02).
- Chang DK, Johns AL, Merrett ND, Gill AJ, Colvin EK, et al. Margin Clearance and Outcome in Resected Pancreatic Cancer. *J Clin Oncol.* 2009;27(17):2855–2862.
- van Roessel S, Kasumova GG, Tabatabaie O, Ng SC, van Rijssen LB, Verheij J. Pathological Margin Clearance and Survival After Pancreaticoduodenectomy in a US and European Pancreatic Center. *Ann Surg Oncol.* 2018;25(6):1760–1767. Available from: <https://dx.doi.org/10.1245/s10434-018-6467-9>. doi:10.1245/s10434-018-6467-9.
- Tummers WS, Groen JV, Mulder BGS, Farina-Sarasqueta A, Morreau J, et al. Impact of resection margin status on recurrence and survival in pancreatic cancer surgery. Wiley ; 2019,. Available from: <https://dx.doi.org/10.1002/bjs.11115>. doi:10.1002/bjs.11115.
- Sanjay K, Chanjuan S, Adsay NV, Pa F. Protocol for the Examination of Specimens From Patients With Carcinoma of the Pancreas ; 2017,. Available from: <https://documents.cap.org/protocols/cp-gihepatobiliary-pancreas-exocrine-17protocol-4001.pdf>.
- Westgaard A, Tafford S, Farstad IN, Cvancarova M, Eide TJ. Pancreatobiliary versus intestinal histologic type of differentiation is an independent prognostic factor in resected periampullary adenocarcinoma. *BMC Cancer.* 2008;8. doi:10.1186/1471-2407-8-170.
- Kavanagh DO, O'Riain C, Ridgway PF, Neary P, Crotty TC, et al. Radical Pancreaticoduodenectomy for Benign Disease. *Scientific World J.* 2008;8:1156–1167. doi:10.1100/tsw.2008.147.
- Sakorafas GH, Farnell MB, Nagorney DM, Sarr MG. Pancreaticoduodenectomy for Chronic Pancreatitis: Long-term Results in 105 Patients. *Arch Surg.* 2000;135.
- Shyr YM, Su CH, Wu CW, Lui WY. Is pancreaticoduodenectomy justified for chronic pancreatitis masquerading as periampullary tumor? . *Hepatogastroenterol.* 2003;50:1163–1166.
- Mayoral W, Salcedo JA, Montgomery E. Biliary Obstruction and Pancreatitis Caused by Brunner's Gland Hyperplasia of the Ampulla of Vater: A Case Report and Review of the Literature. *Endoscopy.* 2000;32(12):998–1001. Available from: <https://dx.doi.org/10.1055/s-2000-9623>. doi:10.1055/s-2000-9623.
- Janes SJ, Zaitoun AM, Catton JA, Aithal GP, Beckingham JJ. Brunner's gland hyperplasia at the ampulla of Vater. *J Postgrad Med.* 2006;52(1).
- Yarandi SS, Runge T, Wang L, Liu Z, Jiang Y. Increased incidence of benign pancreatic pathology following pancreaticoduodenectomy for presumed malignancy over 10 years despite increased use of endoscopic ultrasound. *Diagn Therapeutic Endosc.* 2014; Available from: <http://dx.doi.org/10.1155/2014/701535>.
- Goldner B, Stabile BE. Duodenal adenocarcinoma: why the extreme rarity of duodenal bulb primary tumors? *Am Surg.* 2014;80(10):956–959.
- Cloyd JM, George E, Visser BC. Duodenal adenocarcinoma: Advances in diagnosis and surgical management. *World J Gastrointest*

Surg. 2016;8(3):212–212. Available from: <https://dx.doi.org/10.4240/wjgs.v8.i3.212>. doi:10.4240/wjgs.v8.i3.212.

23. López-Domínguez J, Busquets J, Secanella L, Peláez N, Serrano T, et al. Duodenal Adenocarcinoma: Surgical Results of 27 Patients Treated at a Single Center. *Cirugía Española (English Edition)*. 2019;97(9):523–530. Available from: <https://dx.doi.org/10.1016/j.cireng.2019.10.013>. doi:10.1016/j.cireng.2019.10.013.

Author biography

Hemant R Kokandakar Professor

Rakesh Kumar Ajmera Assistant Professor

Syeda Muneza Junior Resident

Somesh Nilkanth Assistant Professor

Ajay Boralkar Associate Professor

Anagha Varudkar Professor

Cite this article: Kokandakar HR, Ajmera RK, Muneza S, Nilkanth S, Boralkar A, Varudkar A. Surgical pathology of whipple pancreaticoduodenectomy: A 3-year experience at a tertiary cancer care center of marathwada region of India. *IP J Diagn Pathol Oncol* 2020;5(1):69-78.