



Case Report

Multiple primary tumour of parotid gland and duodenum in an elderly male: An unusual rare case report

E S Keerthika Sri¹, S Sowmya^{1,*}, K Shanmugasamy¹, K Anandrajvaithy¹¹Dept. of Pathology, Mahatma Gandhi Medical College and Research Institute, SBV (Deemed to be University), Pondicherry, India

ARTICLE INFO

Article history:

Received 15-09-2019

Accepted 18-09-2019

Available online 20-09-2019

Keywords:

Duodenal carcinoma

Mucoepidermoid carcinoma

Synchronous tumour.

ABSTRACT

Introduction: Patients with multiple primary malignancies (MPMs) are progressively increasing and MPM includes metachronous and synchronous tumours. Synchronous tumour is defined as two or more neoplasms identified simultaneously in the same patient or a second tumour identified up to six months after the initial diagnosis. In India, the incidence of synchronous colorectal adenocarcinoma varies and according to the literature, ranges from 2 to 5%.

Case presentation: In the present case scenario a 68 year old male presented with left pre auricular swelling for 2 months duration along with right axillary swelling for the past one month with history of loss of appetite and significant weight loss. Cytology of parotid swelling showed features of mucoepidermoid carcinoma (MEC) of salivary gland and right axillary swelling revealed metastatic deposits from adenocarcinoma. In addition, the axillary lymph node excision biopsy revealed metastatic deposits from mucoepidermoid carcinoma. Pan endoscopy guided biopsy showed features of adenocarcinoma of duodenum.

Conclusion: Strong clinical acumen and suspicion are required to identify cases of MPM and to differentiate them from metastatic disease. While synchronous tumour is known to occur among colorectal region and below diaphragm, MPM involving head and neck region (parotid) and sub diaphragmatic region (duodenum) makes this case report unique.

© 2019 Published by Innovative Publication.

1. Introduction

Billroth was the first to describe “Multiple Primary Malignancy (MPM)” more than a century back.¹ Later Warren and Gates coined the term MPM and categorised into 2 types: synchronous and metachronous. Being a rare entity, the incidence of multiple cancers had progressively increased over time in the recent past.²

While the term metachronous is applied when tumours follow one another after a period of six months, synchronous is defined as tumours arising simultaneously or within 6 months from the primary malignant tumour.² The former has higher incidence than the later in terms of frequency with an average incidence of 2:1.³

Currently, there is no accepted consensus on the criteria to define synchronous tumour.⁴ Few researchers suggested

proposals which include,

1. Two or more histologically different malignancies and detected simultaneously
2. Two or more histologically distinct malignancies diagnosed during the same time admitted in the hospital
3. Two or more histologically distinct malignancies arising from the same system of origin with a sequence gap of minimum 2 months duration
4. Metastatic lesions among these tumours must be excluded

Several theories had been proposed on the factors that influence the occurrence of MPM like elderly age, male gender, family history, genetic predisposition and precursor lesions. MPM is predominantly observed among the gastrointestinal system especially in colorectal and always has a tendency to occur below diaphragmatic sites.⁵ Apart from GIT, MPM is known to involve breast, renal system

* Corresponding author.

E-mail address: pathology@mgmcri.ac.in (S. Sowmya).

and lung. MPM involving the parotid gland as one component in adjunction with GIT malignancy (especially duodenal carcinoma) as another component is an extremely rare phenomenon.⁶

In the present case scenario, we had an elderly male with synchronous tumor as a rare and unique presentation.

1.1. Case presentation

A 68 years old male patient presented with painless swelling in the left cheek of 2 months duration with gradual increase in size. He also gave history of left axillary swelling of one and a half months duration. He had loss of appetite and significant weight loss in the past 2 months. He was a known hypertensive.

On examination, there was a left preauricular swelling of 6x4 cm size (Figure 1). The swelling was nodular, firm, with neither warmth nor tenderness. Skin over the swelling was normal. Horizontal mobility was more than vertical mobility. Right axilla showed a solitary firm swelling measuring 3x3 in diameter.

As a screening procedure for any superficial swelling, the patient was subjected to Fine Needle Aspiration Cytology procedure (FNAC) for the parotid and axillary swelling. Cytological picture of the parotid swelling revealed features of mucoepidermoid carcinoma (MEC) of salivary gland (Figure 2) and cytology of axillary swelling showed features of metastatic adenocarcinomatous deposits (Figure 3). Subsequent excision biopsy of axillary swelling showed classical metastatic deposits from MEC (Figure 4). Since the patient gave history of loss of appetite, vomiting, abdominal pain and significant weight loss, pan endoscopy procedure was performed which revealed an ulcerative growth in duodenum and its histopathological picture proved to be adenocarcinoma of duodenum (Figure 5). Thus the patient proved to be a case of MPM with synchronous nature presenting with less than six months duration.

2. Discussion

The term MPM earlier entitled as ‘Second primary malignancy or dual malignancy’ was known even ten decades back.⁶ Literature search states that colorectal cancers will be definite component along with genital or urinary cancers often having precursor lesions especially Hereditary Non Polyposis Colorectal Cancers (HNPCC).⁷ Studies had observed the incidence of MPM as 7-9% worldwide and 6-9% among all cancers in Tropical countries like India with annual increase in incidence^{7,8}

The tendency of some patients to develop MPM (synchronous or metachronous) may be explained by the action of carcinogenic factors acting on different organs at different times.⁸ This could be the explanation regarding the association between slow growing and aggressive tumours, as reported in our case.

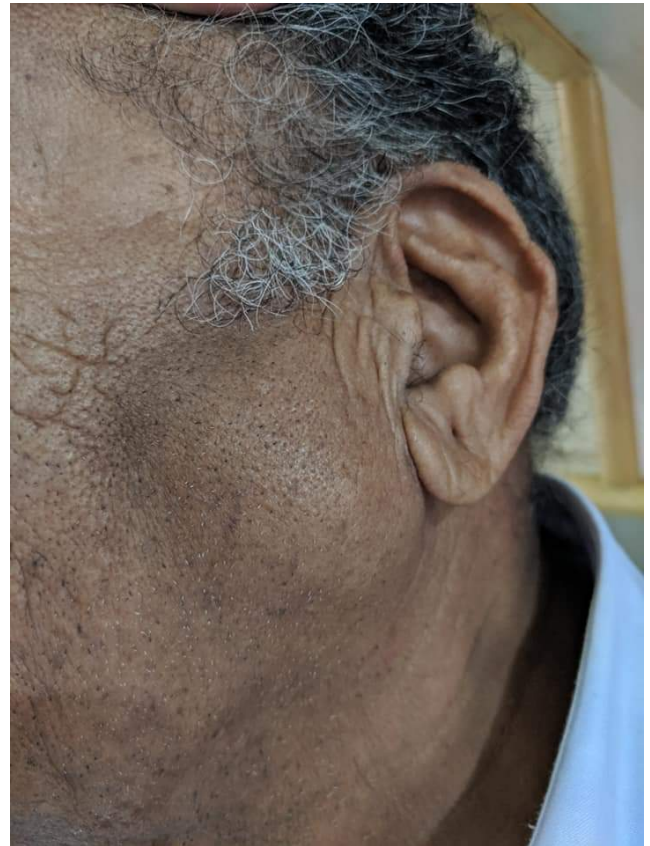


Fig. 1: Left Preauricular cheek swelling measuring 6 x 4 cm

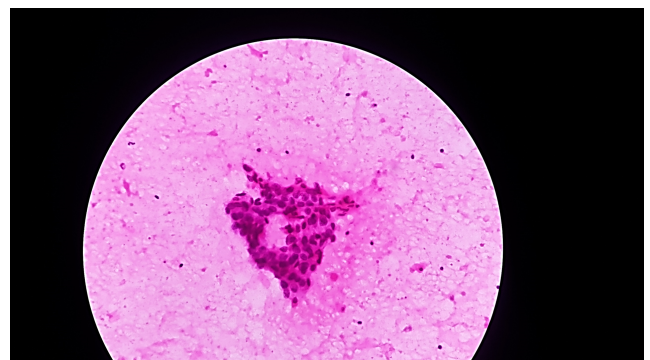


Fig. 2: Smears from aspirate of preauricular swelling showing small clusters of intermediate cells in a background of blood mixed mucin. Pap, 40X

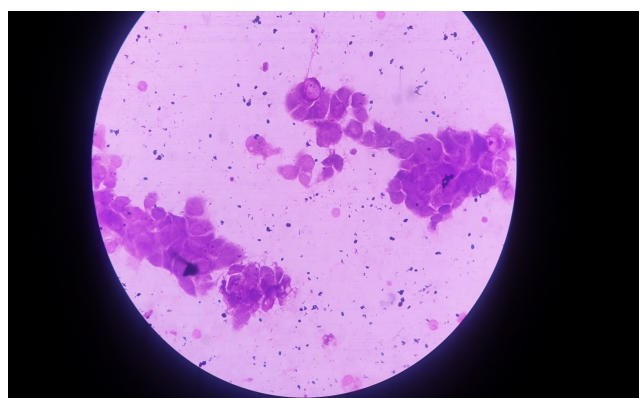


Fig. 3: Fine needle aspiration smears from axillary lymph node showing deposits of Mucoepidermoid carcinoma. MGG, 40X

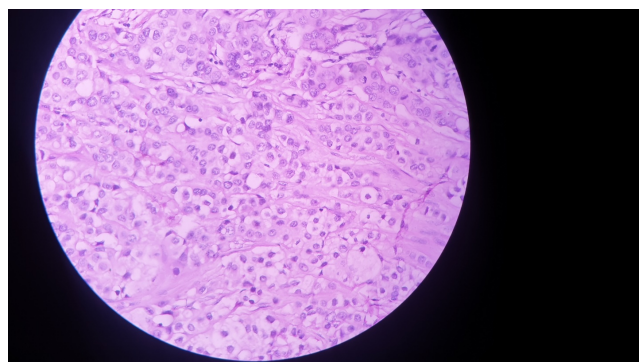


Fig. 4: Excision biopsy of axillary swelling showing mucoepidermoid carcinoma with tumor cells of mucin secreting type, H&E, 40X

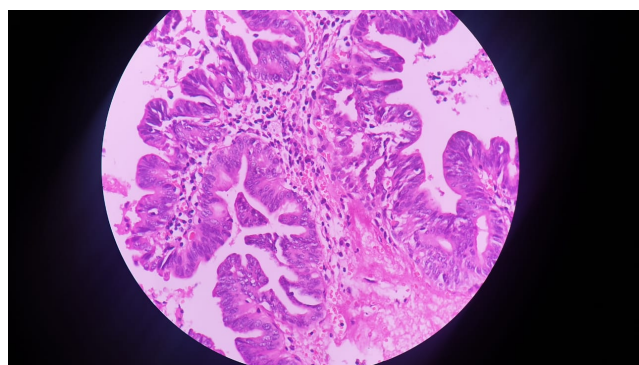


Fig. 5: Endoscopic biopsy from duodenum showing adenocarcinoma with tumor cells arranged in glandular pattern with nuclear pleomorphism. H&E, 40X

With regard to MPM, age factor is an uncertain parameter, as several studies have indicated that synchronous tumours occur in older patients,⁹ while few studies observed among younger patients. However the usual age incidence ranges between 45–75 years of age with median age of 55 years.

Majority of the cases diagnosed synchronously were incidental during staging work up of the primary tumour. Very few patients will have complaints attributable to the second primary tumour. Most common challenge encountered by practitioners is to label such tumour to be metastatic in nature, often obviating the rare possibility of a second primary tumour. Multiple tumours that have been microscopically confirmed at the time of presentation should be evaluated and staged as independent tumours.^{9,10}

Salivary gland tumours commonly known to occur in parotid region and are usually benign than malignant. While Mucoepidermoid carcinoma of salivary gland is a relatively rare condition it is well known to have metastatic spread to cervical lymph node. Surprisingly in the present case, the patient had metastatic deposits to axillary node which was confirmed histopathologically.¹¹

While colorectal carcinoma is a well-known MPM component, the incidence of duodenal carcinoma as MPM component is rarely reported in literatures. While GIT cancers spread to supraclavicular node above the diaphragm, metastasis to axillary region is still an unique presentation.^{11,12}

Luciani et al. stated that salivary gland as a component is extremely rare, even if involved acinic cell carcinoma and Warthins tumour are only reported in the literatures.¹² MEC in adjunction with duodenal adenocarcinoma as synchronous tumour is a rare combination ever reported in the literatures. It is evident from the present case that synchronous tumour can also involve salivary gland with MEC as a component thereby warranting further exploration of MPM especially in supradiaphragmatic lesions.^{10,12}

The treatment plan should be decided after staging of both the primary and secondary tumour in view to attain maximum clinical response. Proper counselling and patient's understanding of the magnitude of the disease is paramount. Single stage surgery can be offered to treat both the tumour if indicated in majority of cases with low morbidity and mortality.

2.1. Critical appraisal and uniqueness of the case

Synchronous tumour involving salivary gland with GIT is extremely rare. Mucoepidermoid carcinoma in conjunction with duodenal adenocarcinoma is a unique presentation. To our knowledge on synchronous tumour, no case in literature has so far mentioned the occurrence of MEC of salivary gland tumour in adjunction with duodenal adenocarcinoma and salivary gland tumour metastasizing to axillary node is also a rare phenomenon.

3. Conclusion

MPM can present in elderly males with supradiaphragmatic component as well. Strong clinical acumen and suspicion are required to identify cases of MPM and to differentiate them from metastatic disease. Synchronous tumour is known to occur among colorectal region as the most common presentation. Mucoepidermoid carcinoma of salivary gland with duodenal adenocarcinoma makes this case report unique. The preoperative detection of synchronous tumours not only allows establishing the appropriate surgical strategy, but also facilitates the follow-up plan after surgery.

4. Acknowledgments

Dr.K.V.Rajan, Professor of General Surgery, MGMCRI, SBV University (Deemed to be), Puducherry, India

5. Source of Funding

None.

6. Conflicts of interest

None.

References

- Warren S, Gates O. Multiple primary malignant tumours: a survey of the literature and statistical study. *Am J Cancer*. 1999;16:1358–1414.
- Sakelaris M, Peroukides S, Iconomou G, Boumpouheropoulos S, Kalofonos H. Multiple primary malignancies: report of two cases. *Chin J Cancer Res*. 2014;26:215–8.
- Xu LL, Gu KS. Clinical retrospective analysis of cases with multiple primary malignant neoplasms. *J Gen Mol Res*. 2014;22:30–5.
- Yancik R, Ries LA. Aging and cancer in America. Demographic and epidemiologic perspectives. *J Hematol Oncol Clin North Am*. 2000;14:17–23.
- Shin DW, Baik YJ, Kim YW, Oh JH, Chung KW, et al. Knowledge, attitudes, and practice on second primary cancer screening among cancer survivors: A qualitative study. *J Patient Educ Couns*. 2011;85:74–8.
- Shin DW, Kim YW, Oh JH, Kim SW, Chung KW, et al. Knowledge, attitudes, risk perception, and cancer screening behaviours among cancer survivors. *J Cancer Biology*. 2011;117:3850–9.
- Braakhuis BJ, Tabor MP, Leemans CR, Waal IVD, Snow GB, et al. Second primary tumours and field cancerization in oral and oropharyngeal cancer: Molecular techniques provide new insights and definitions. *J Head Neck cancer*. 2002;24:198–206.
- Morris LG, Sikora AG, Patel SG, Hayes RB, Ganly I. Second primary cancers after an index head and neck cancer: Subsite-specific trends in the era of human papillomavirus-associated oropharyngeal cancer. *J Clin Oncol*. 2011;29:739–46.
- Hulikal N, Ray S, Thomas J, Fernandez DJ. Second primary malignant neoplasms: A clinic pathological analysis from a cancer centre in India. *Asian Pac J Cancer Prev*. 2012;13:6087–91.
- Oijen MG, Slootweg PJ. Oral field cancerization: Carcinogen induced independent events or micro metastatic deposits? *J Cancer Epidemiol Biomarkers Prev*. 2000;9:249–56.
- Morris LG, Sikora AG, Hayes RB, Patel SG, Ganly I. Anatomic sites at elevated risk of second primary cancer after an index head and neck cancer. *J Cancer Causes Control*. 2011;22:671–9.
- Luciani A, Balducci L. Multiple primary malignancies: A review. *J Semin Oncol*. 2004;31:264–73.

Author biography

E S Keerthika Sri Tutor

S Sowmya Professor and HOD

K Shanmugasamy Professor

K Anandrajvaithy Associate Professor

Cite this article: Keerthika Sri ES, Sowmya S, Shanmugasamy K, Anandrajvaithy K. Multiple primary tumour of parotid gland and duodenum in an elderly male: An unusual rare case report. *J Diagn Pathol Oncol* 2019;4(3):241-244.